

An Atlas of Surgical Anatomy

A detailed pencil drawing of a surgical procedure. A hand is shown holding a surgical instrument, possibly a scalpel or forceps, over a dissected anatomical structure. The drawing is rendered in a classic, detailed style, showing the texture of the skin, the structure of the muscles, and the intricate network of nerves and blood vessels. The background is a light, neutral color, making the drawing stand out.

*Surgical Commentary
by Alain C Masquelet*

Illustrations by Léon Dorn

 Taylor & Francis
Taylor & Francis Group

with
CD-ROM

An Atlas of Surgical Anatomy

An Atlas of
Surgical Anatomy

Surgical commentary by

Alain C Masquelet, MD

Illustrations by Léon Dorn

© 2005 Taylor & Francis, an imprint of the Taylor & Francis Group

First published in the United Kingdom in 2005
by Taylor & Francis, an imprint of the Taylor & Francis Group,
2 Park Square, Milton Park, Abingdon, Oxon OX14 4RN

Tel.: +44 (0) 1235 828600
Fax.: +44 (0) 1235 829000
E-mail: info@dunitz.co.uk
Website: <http://www.dunitz.co.uk>

All rights reserved. No part of this publication may be reproduced, stored in a retrieval system, or transmitted, in any form or by any means, electronic, mechanical, photocopying, recording, or otherwise, without the prior permission of the publisher or in accordance with the provisions of the Copyright, Designs and Patents Act 1988 or under the terms of any licence permitting limited copying issued by the Copyright Licensing Agency, 90 Tottenham Court Road, London W1P 0LP.

Although every effort has been made to ensure that all owners of copyright material have been acknowledged in this publication, we would be glad to acknowledge in subsequent reprints or editions any omissions brought to our attention.

Although every effort has been made to ensure that drug doses and other information are presented accurately in this publication, the ultimate responsibility rests with the prescribing physician. Neither the publishers nor the authors can be held responsible for errors or for any consequences arising from the use of information contained herein. For detailed prescribing information or instructions on the use of any product or procedure discussed herein, please consult the prescribing information or instructional material issued by the manufacturer.

A CIP record for this book is available from the British Library.

Library of Congress Cataloging-in-Publication Data
Data available on application

ISBN 1 84184 000 0

Distributed in North and South America by
Taylor & Francis
2000 NW Corporate Blvd
Boca Raton, FL 33431, USA

Within Continental USA
Tel.: 800 272 7737; Fax.: 800 374 3401
Outside Continental USA
Tel.: 561 994 0555; Fax.: 561 361 6018
E-mail: orders@crcpress.com

Distributed in the rest of the world by
Thomson Publishing Services
Cheriton House
North Way
Andover, Hampshire SP10 5BE, UK
Tel.: +44 (0)1264 332424
E-mail: salesorder.tandf@thomsonpublishingservices.co.uk

Typeset by Scribe Design, Ashford, Kent
Printed and bound by

Contents

Preface vii

Léon Dorn: A biographical note viii

Léon Dorn: Notes on method ix

1 Reconstructive surgery

The tree of flaps for the upper limb 2

Flap from the lateral head of
gastrocnemius 3

Soleus muscle flaps 5

Sural skin flap 8

Vascularised osteoperiosteal flap from the
femur 10

Vascularised fibula transfer 11

Lateral brachial flap 14

Forearm radial flap 16

Posterior interosseous flap 18

Pronator quadratus muscle flap 20

2 Hand and peripheral nerve surgery

Anatomy of the hand 24

The trapezium: volar approach 27

The 'boutonnière' deformity 31

Arthrolysis of the PIP joint 34

Protective flaps for the median nerve at the
wrist 36

Flexor digitorum superficialis transfer to the
thumb 38

Vascularised bone transfer from the metaphysis
of the second metacarpal 39

Dupuytren's disease 40

Surgery of the wrist 44

Pollicisation of the index finger 45

Brachial plexus 49

Exposure of the interosseous nerve 54

Exposure of the radial nerve at the
elbow 57

3 Gynaecological surgery

The lower approach of the prolapse and
the separation of the vagina and the
bladder 60

Treatment of genital prolapse after
hysterectomy 65

Surgical treatment of clytrocele 70

4 Urological surgery

Allotransplantation of the kidney 74

Surgery of renal lithiasis 79

Extrophy of the bladder in a young boy 81

Hypospadias surgery 86

Prosthesis for erectile function of penis 90

Amputation of the penis for sexual ambiguity:
feminisation 97

5 Abdominal surgery

Reconstruction of a urinary bladder 106

Gastrectomy 110

The liver 115

6 Surgery of the vertebral column

Transpleural approach to the dorsal rachis by
thoracotomy 120

Treatment of lumbar spondylolisthesis 122

Surgical treatment of scoliosis 126

Treatment of lumbar disc hernia: anterior
approach 129

7 Upper limb surgery

Sternoclavicular dislocation 134

Stabilisation of a shoulder prosthetic
implant 136

Cleidectomy 137

Osteosynthesis of a fracture of the
forearm 139

Anterior approach to the subacromial
space 141

Contents

- Anterior approach to the glenohumeral joint 143
- Axillary approach to the glenohumeral joint 147
- Subdeltoid approach to the proximal metaphysis of the humerus 150
- Anterior approach to the proximal third of the radius 151

8 Lower limb surgery

- Anatomy of the posterior approach to the femoral shaft 154
- Extended medial approach to the popliteal vessels 157
- Anatomy of the knee 160
- Anatomy of the lumbosacral plexus 162
- Prosthesis of the patella 163
- Repair of a rupture of the anterior cruciate ligament 167
- Posterior approach to the posterior cruciate ligament 171

- Allograft of patella and patellar ligament 173
- Cross-section through the hip joint 176
- Posterior approach to the acetabulum 177
- Inguinal approach to the acetabulum 181
- Extended iliofemoral approach to the acetabulum 186
- Posteromedial approach to the ankle 190
- Lateral approach to the subtalar and midtarsal joint 193

9 Miscellaneous

- Muscular studies 195
- Surgery of the ear: neurosurgery 199
- Surgery of the middle ear 202
- Tympanic graft 204
- Paediatrics: Pavlick's harness 207
- Congenital malformations 208
- Detection of fetal anomalies 216
- Dissection of the left heart 217
- Dissection of the right heart 221

Index 225

Preface

Léon Dorn is one of the most famous medical illustrators in the world. Even today, at 80 years of age, he continues to pursue his work with the same enthusiasm. His work coincides with his great passion: the representation of the human body. Anatomy holds no secrets for him. He has spent countless hours in operating theatres, dissecting rooms and with himself; when Léon Dorn is drawing hands, he is drawing his own hands ...

Until recently, medical illustration was an undervalued job. The illustrators were basically artists, attracted to the human body. Many of them were self-trained people. Most of the time they were not well considered and some publishers even refused to mention their names in books.

Today, medical illustration has gained its 'letters patent of nobility'. Léon Dorn has witnessed the emergence, the development and the now well recognised state of the medical illustration.

Dorn is specially involved in the illustration of surgical techniques, which is probably the most difficult part of the art of medical illustration since the illustrator must attend surgical operations to understand what exactly is being done and then distil a long procedure into a few drawings. Usually, no more than five to seven drawings are needed to illustrate a surgical technique. The skill and possibly the genius of the artist lies in their ability to condense multiple operating stages into a limited number of drawings.

From a didactic point of view, it reveals the superiority of drawings over film. A film (movie or video sequence) delivers a linear succession of snap shots whereas a single drawing illustrates an entire sequence of a technical procedure.

For learning a technique, human understanding proceeds more by intuitive discerning of whole stages rather than separate elementary actions. This is the reason why the medical illustration based on drawings is superior to one based on videos. In spite of the recent advances in techniques of communi-

cation, the illustrated book will always be valid for the learning process.

I would like just to comment upon Léon Dorn's manner of working. Some illustrators work at home, trying to restore a surgical technique from a draft prepared by the surgeon. Dorn's method is quite different. For him, the illustrator is like a reporter, an eye witness and a field worker; he has to perceive the intensity of an acute stage to express it through the drawing. This book is an attempt to communicate this particular state of mind. With Léon Dorn we have selected over 300 drawings from among a collection of several thousands.

These selected drawings do not constitute a treatise of surgical techniques. Their function is to highlight one of the main stages of the illustrator's work, which is the 'almost finished rough sketch'. For that reason the drawings are still outlines in lead pencil, in black and white. We have included a few definitive drawings in colour to show the contrast between what is actually published and what is the most important stage of the artist's work. Thus we present isolated drawings or several associated drawings, taken from different surgical fields, which do not constitute the complete description of a surgical technique.

The drawings are succinctly explained, just for understanding what they show. Where they are present, we have kept the legends written by the artist as an aid for the definitive drawing. On the other hand, we have not added new legends that could impede the serene contemplation of the drawings. What is important for the readers is to open their eyes for pleasure; the secret is not in the text but in the illustrations. Léon Dorn has rejuvenated the tradition of the medical illustrators who were initially artists admiring the human body, such as Calcar, the pupil of Le Titian, who immortalised the dissections of Vesalius, or Jacob, the pupil of David, who drew the anatomical preparations of Bourguery.

AC Masquelet

Léon Dorn

A biographical note

Léon Dorn was born in Paris in 1920. He lived in Israel from 1932 to 1965, where he worked in a kibbutz. This long stay in Israel was interrupted for two years (1953–1954) during which he studied at the Academy of Arts in Florence (Italy). In 1961, he was named general secretary of the Organisation of Painters and Sculptors of Kibboutzim.

He began to work as a medical illustrator when he came back to France in 1965. He was mostly commissioned by Masson Publishers and, in 1989, was invited by Professor Tubiana to illustrate surgi-

cal books for Martin Dunitz. His illustrations for *An Atlas of Flaps in Limb Reconstruction* (published by Martin Dunitz) won the Royal Society of Medicine Atlas award in 1995.

Léon Dorn is a pioneer of modern medical illustration in France. He actively participated in the efforts of the European Association of Medical and Scientific Illustrators to promote special schools devoted to medical illustration. A department was opened at the Ecole Estienne of Paris in 1992.

Léon Dorn

Notes on method

What is the method of Léon Dorn? Another form of this fascinating question could be: How is the genesis of a definitive drawing?

The secret of Léon Dorn is based on two principles:

1. An excellent knowledge of anatomy. As Léon Dorn has worked with many surgeons from different specialties, he has indepth knowledge of the anatomy of the human body. Moreover, he has contributed to several books on anatomy. It can be said that during his entire professional life Dorn has continued to compare anatomy as described and taught in books with real-life anatomy as encountered in operating rooms and theatres.
2. The second principle issues from the first. Léon Dorn draws 'live'. In his professional life he is permanently on the move to attend surgical operations and dissections. The vast majority of his illustrations have not been drawn from photographs or rough sketches made by surgeons but from what he has seen and observed.

The realisation of a definitive drawing as it will be published in a book has three important stages. It has been difficult to retrieve all the stages for one drawing from Dorn's archives. He has lost many drawings, and the first stage of a drawing is generally destroyed.

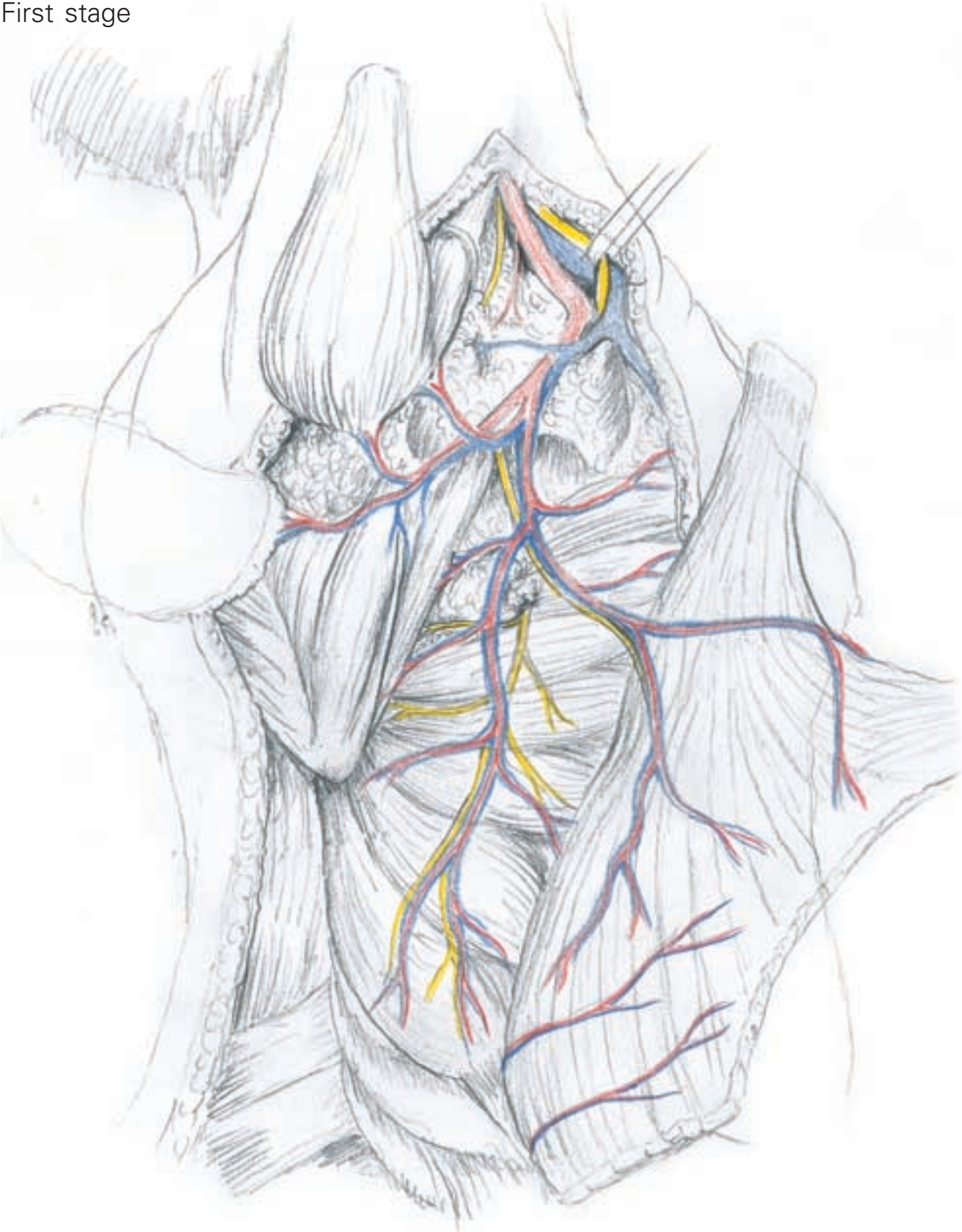We have only one example of a complete series.

- a) The first drawing is done in the operating room or in a theatre of anatomy. It can be called a sketch, but it is a very precise sketch. All the proportions are good, and all the structures are set in place: the nerves are coloured yellow, veins blue and arteries red. Some legends are added to remember exactly what has been drawn.
- b) The second stage is drawn 'at home'. It is the intermediate stage between the sketch and the definitive drawing. It can be called the 'rough drawing'. Details are precisely drawn, for example the representation of the arteries and the thickness of the subcutaneous tissue. In this stage, primarily the shadows are applied to increase the impression of volume for the muscles and the perspective for the deep structures. The rough drawing is given to the surgeon who can then modify any detail on a tracing paper firmly attached to the drawing.
- c) The definitive drawing is made once the rough drawing has been corrected. The structures are coloured or underlined in black ink and with paint.

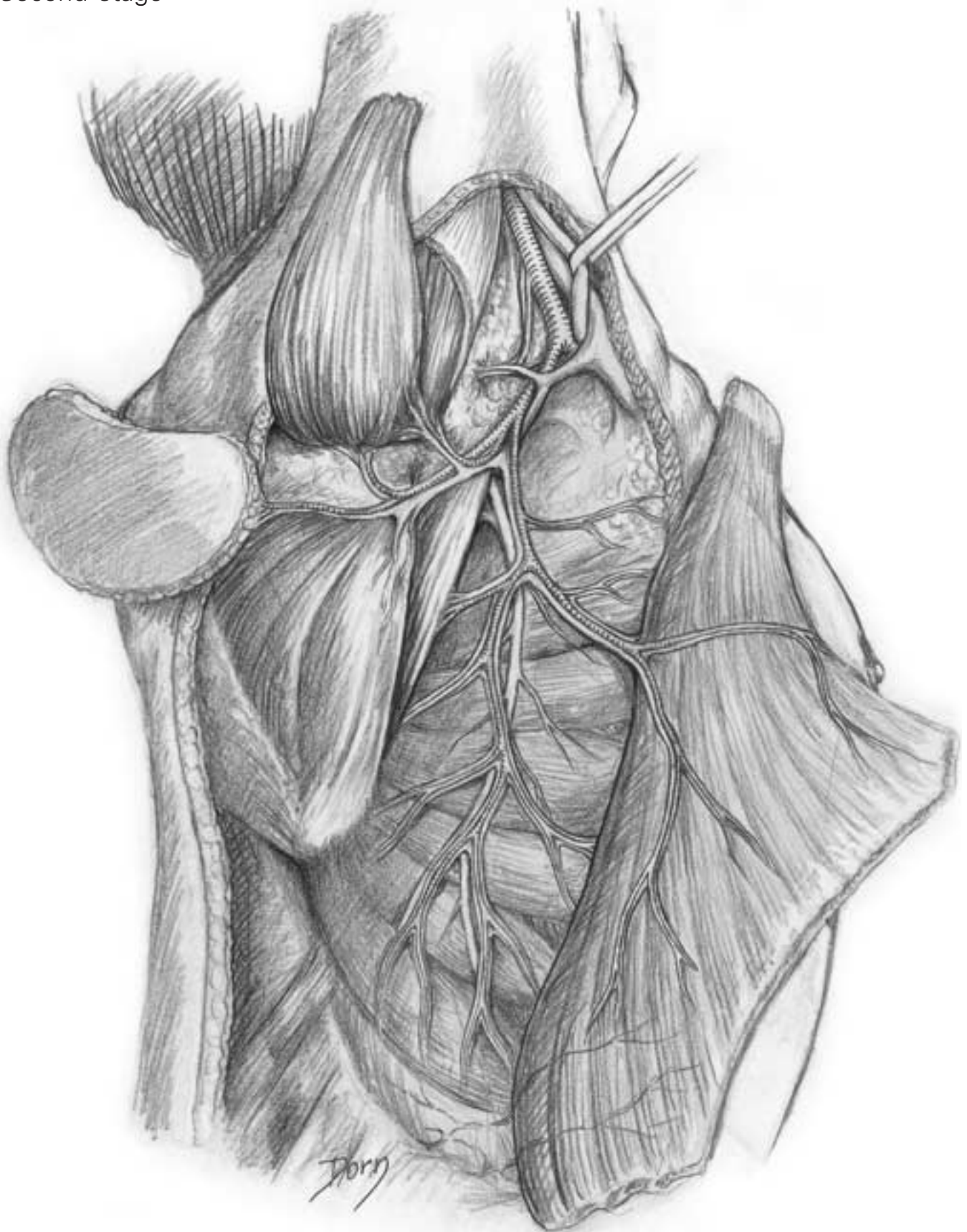
The destiny of each stage is quite different:

- The sketches are generally destroyed or lost.
- The definitive drawing is given to the publisher and becomes their property.
- The intermediate stage - the rough drawing - which is, in fact, the most beautiful stage because it is the most realistic, remains the property of Léon Dorn.

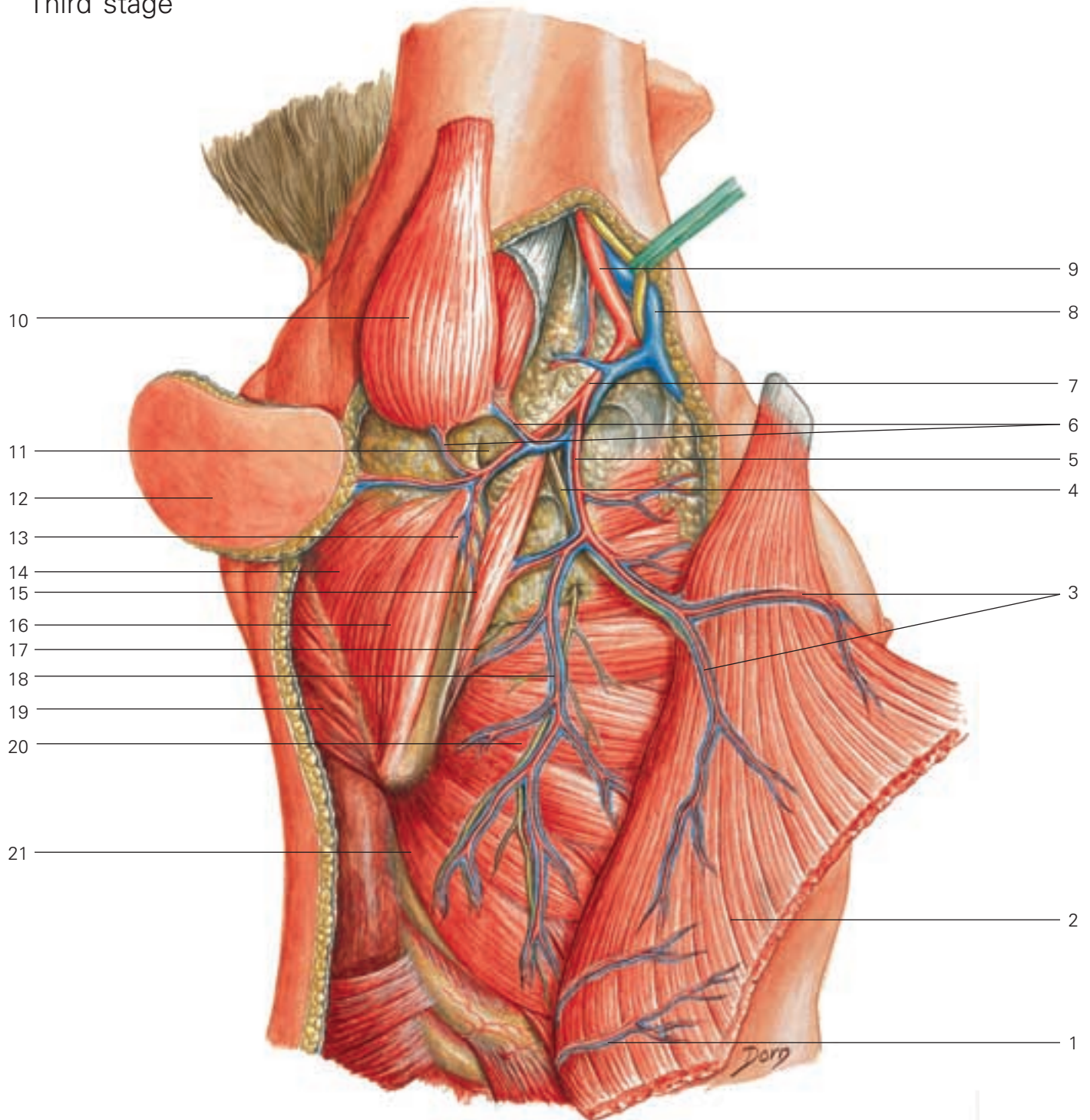
First stage



Second stage



Third stage



D

- | | | |
|--|--|--|
| 1 intramuscular pedicle issuing from intercostal arteries | 7 subscapular artery | 15 subscapular muscle |
| 2 latissimus dorsi muscle | 8 axillary vein | 16 teres minor muscle |
| 3 intramuscular divisions of vascular pedicle supplying latissimus dorsi | 9 axillary artery | 17 bony angular branch to scapula (anastomoses with vascular pedicle supplying rim of scapula) |
| 4 nerve to latissimus dorsi | 10 teres major muscle | 18 thoracic vessels |
| 5 thoracodorsal pedicle | 11 circumflex scapular artery and vein | 19 trapezius and rhomboid muscles |
| 6 pedicles to teres major muscle | 12 scapular flap | 20 long thoracic nerve |
| | 13 vascular pedicle supplying rim of the scapula | 21 serratus anterior muscle |
| | 14 infraspinatus muscle | |

Reconstructive surgery

During the past 30 years, reconstructive surgery has undergone incredible development. One of the main factors is microsurgical techniques which have permitted transfer of all kinds of tissue. There has been a renewed interest in anatomy, especially for the description of nutritive sources and vascular pedicles.

Recent advances in immunosuppressive treatment have allowed allotransplantation of functional organs, such as the hand.

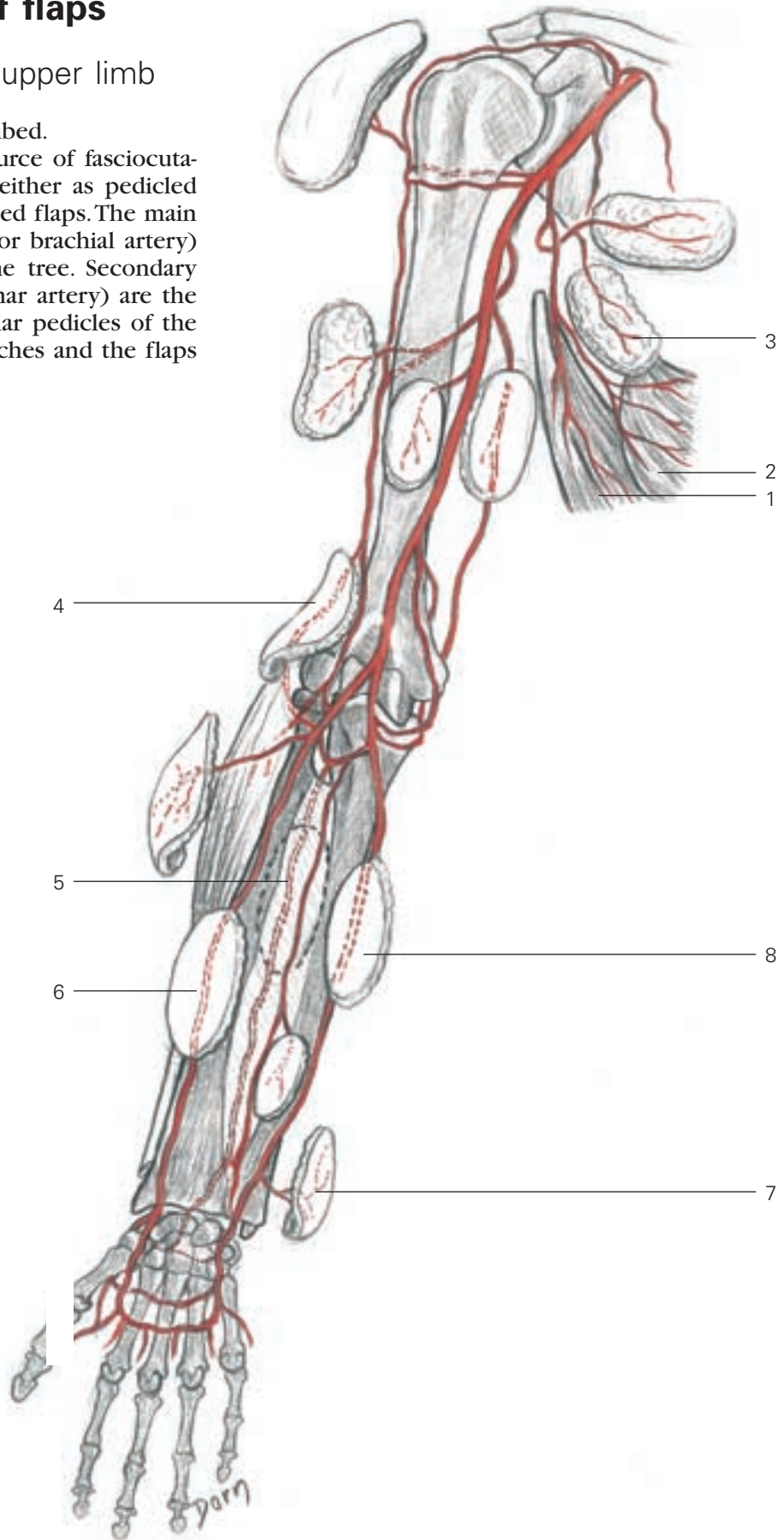
An Atlas of Flaps of the Musculoskeletal System is the latest book illustrated by Léon Dorn. All the drawings are based on anatomical dissections and every detail is authentic.

Anatomy: the tree of flaps

The tree of flaps for the upper limb

Numerous flaps have been described.

The upper extremity is the source of fasciocutaneous flaps which can be used either as pedicled island flaps or as free revascularised flaps. The main vascular axis (the axillary artery or brachial artery) is considered as the trunk of the tree. Secondary arteries (such as the radial or ulnar artery) are the divisions of the trunk. The vascular pedicles of the flaps are formed from small branches and the flaps are the leaves.

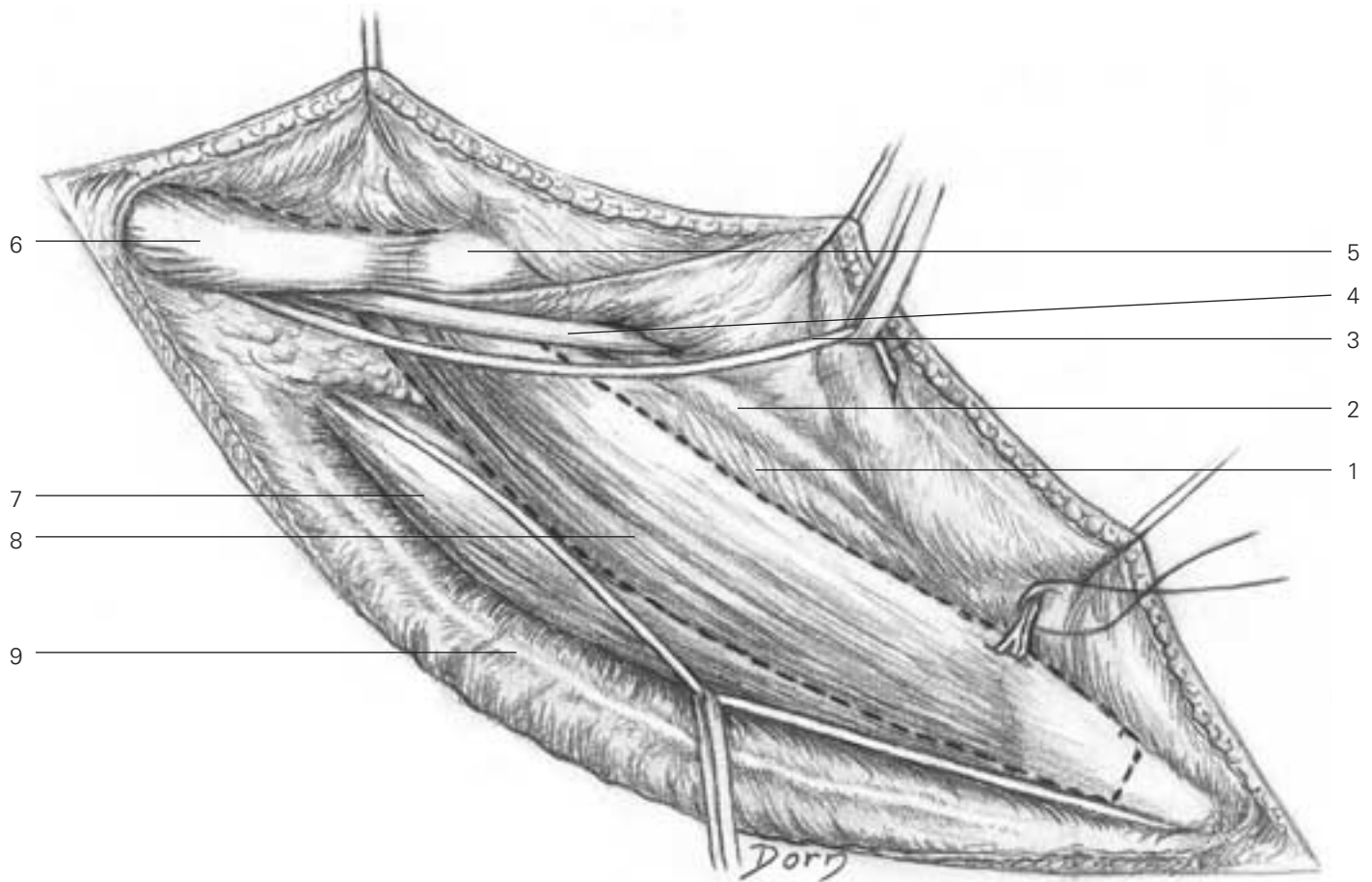


- 1 latissimus dorsi flap
- 2 serratus anterior flap
- 3 scapular flaps
- 4 lateral arm flap
- 5 posterior intraosseous flap
- 6 radial forearm flap
- 7 distal ulnar flap
- 8 ulnar forearm flap

Flaps from the lower limb

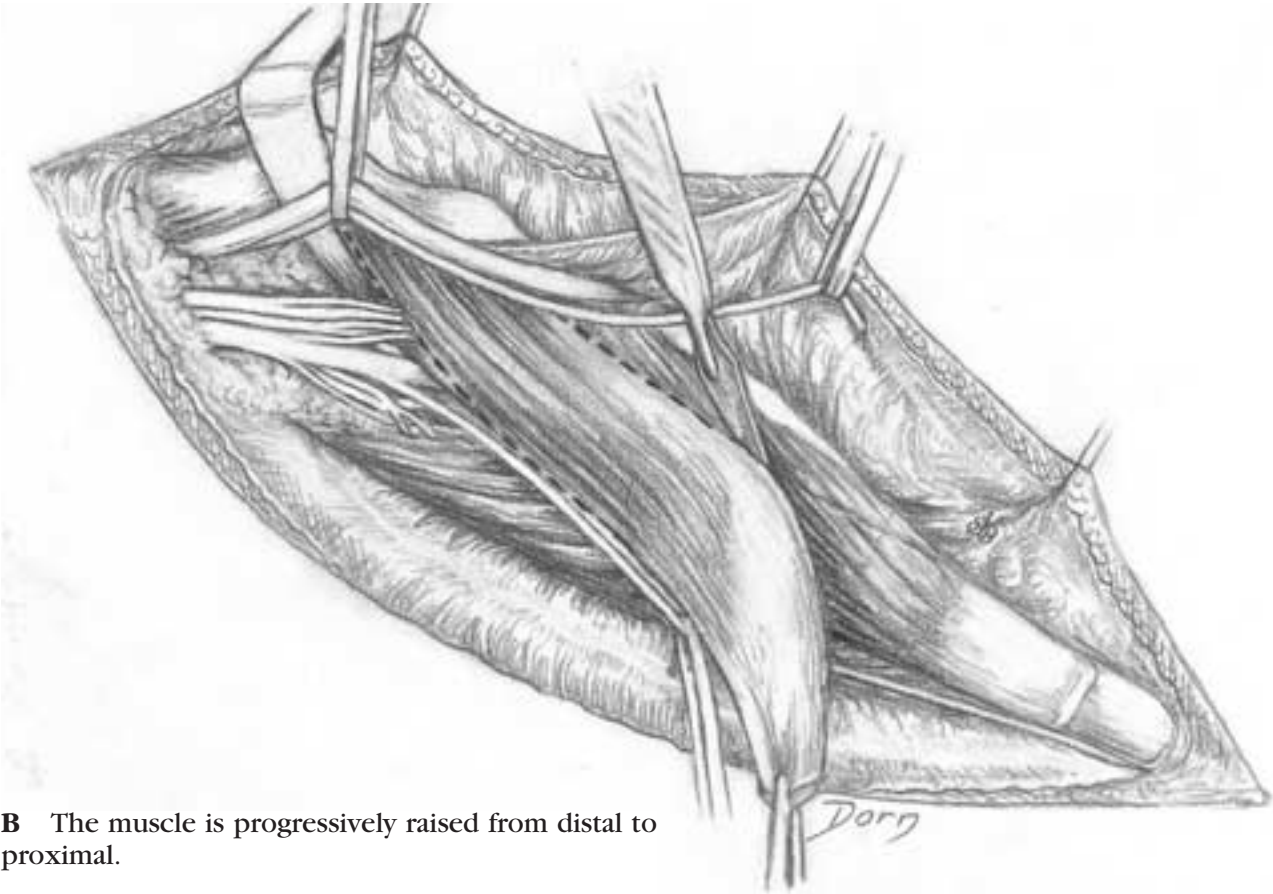
Flap from the lateral head of the gastrocnemius

A The muscle is exposed with all the surrounding structures.

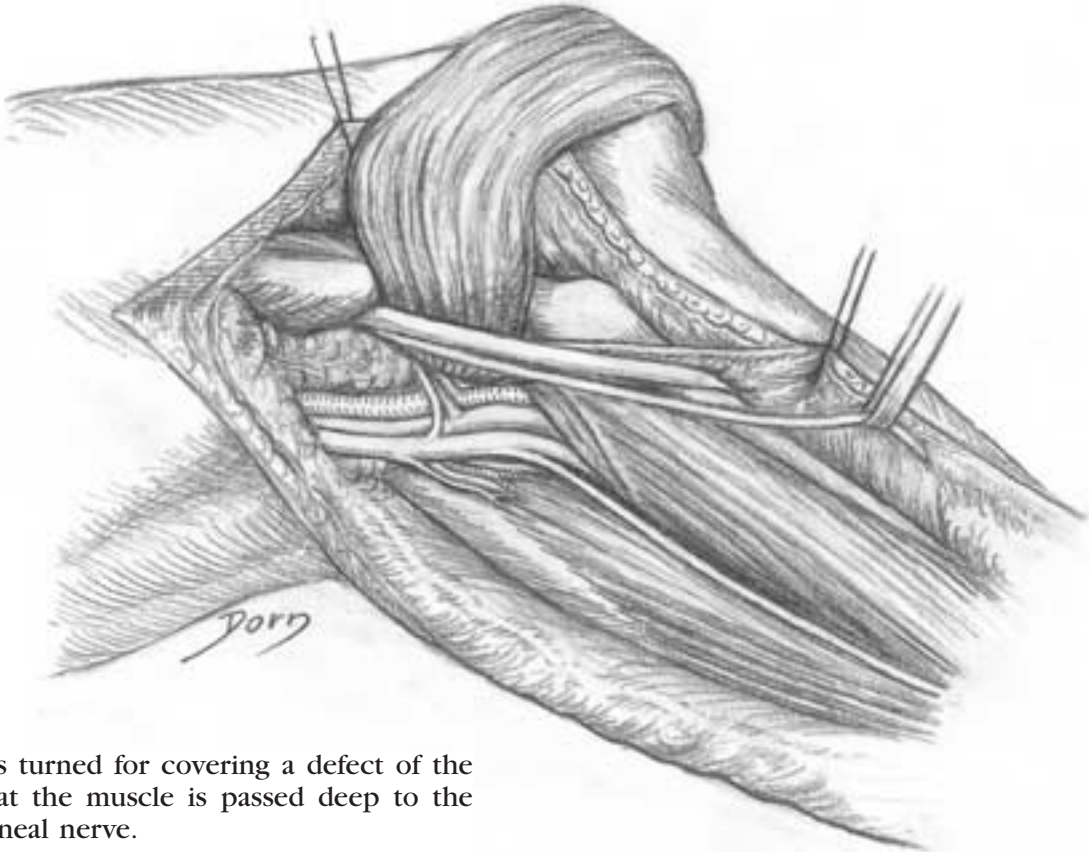


A

- 1 soleus
- 2 fibula
- 3 lateral sural cutaneous nerve
- 4 common peroneal nerve
- 5 head of fibula
- 6 biceps femoris
- 7 gastrocnemius (medial head)
- 8 gastrocnemius (lateral head)
- 9 lesser saphenous vein



B The muscle is progressively raised from distal to proximal.

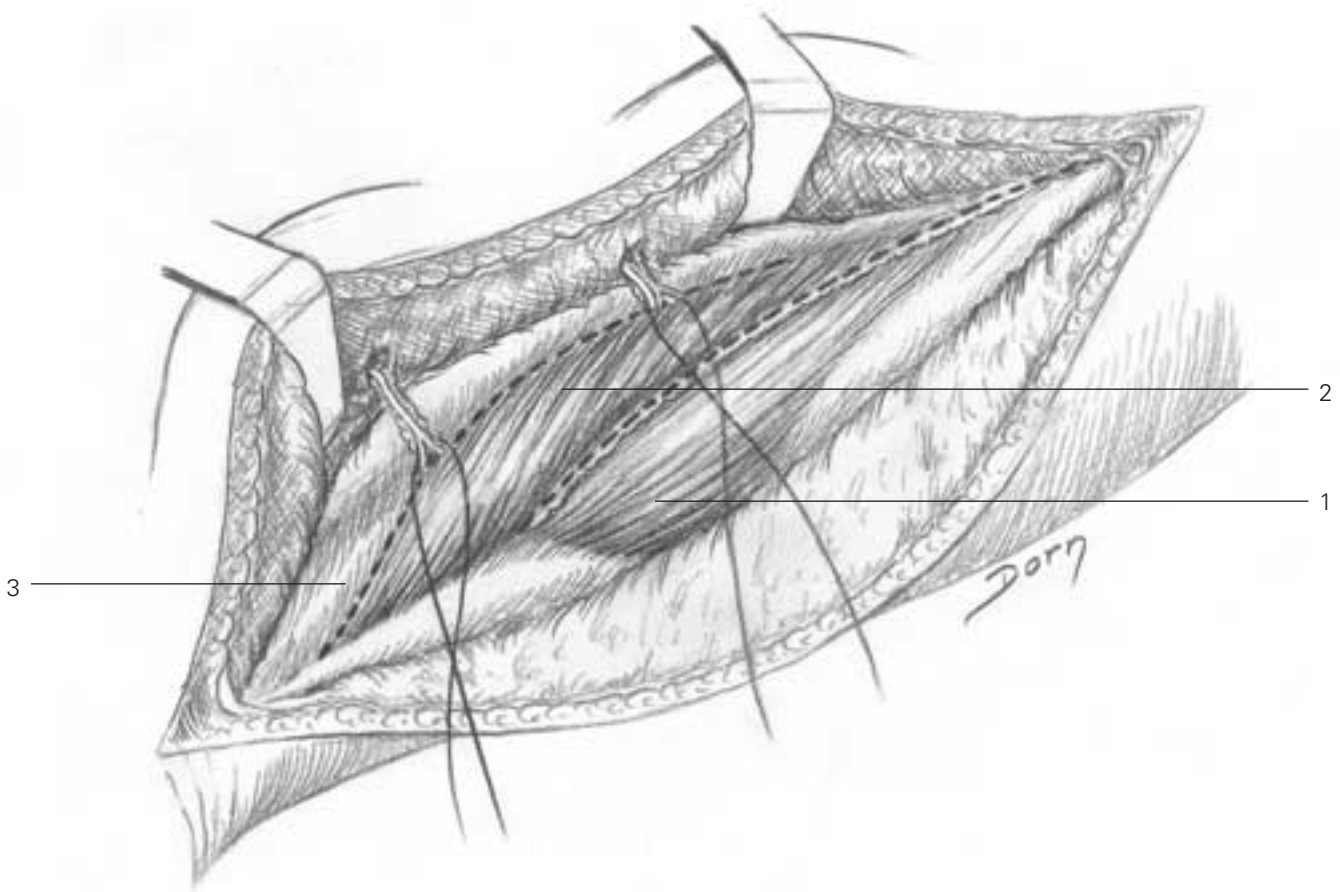


C The flap is turned for covering a defect of the knee. Note that the muscle is passed deep to the common peroneal nerve.

Soleus muscle flaps

This flap is suitable for covering a defect of the middle third of the leg.

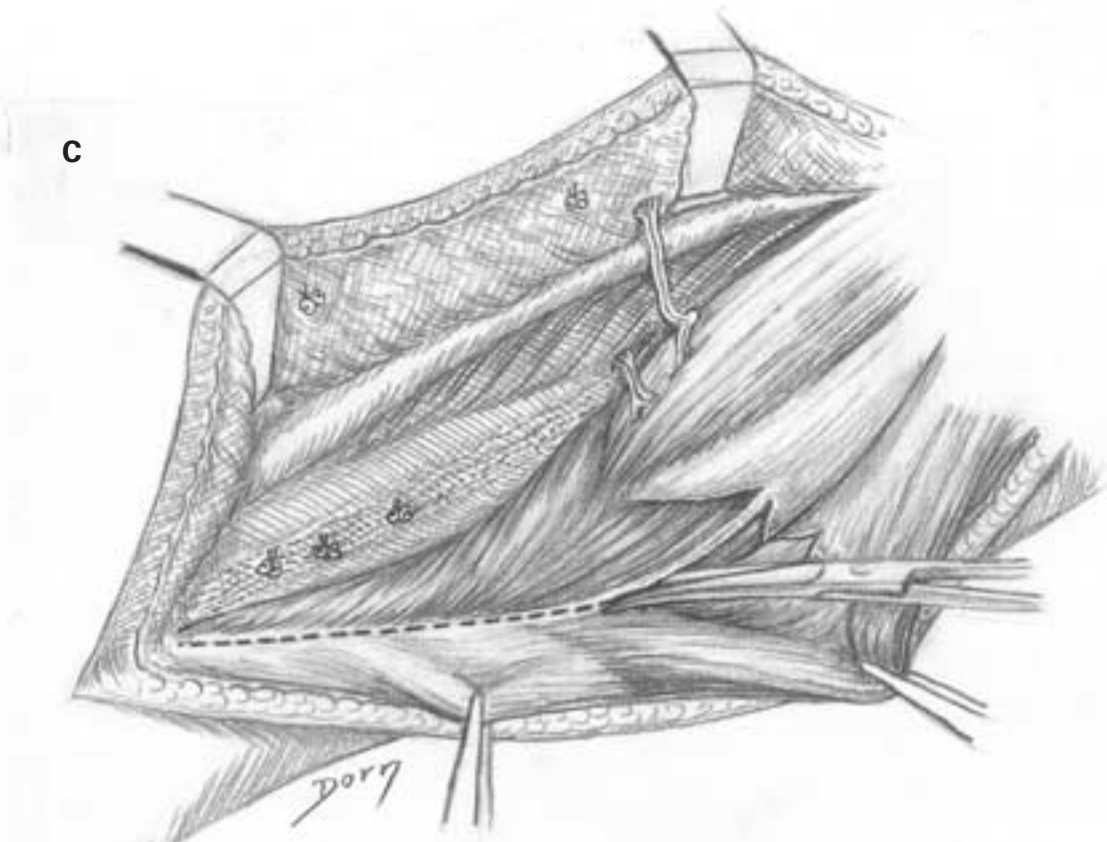
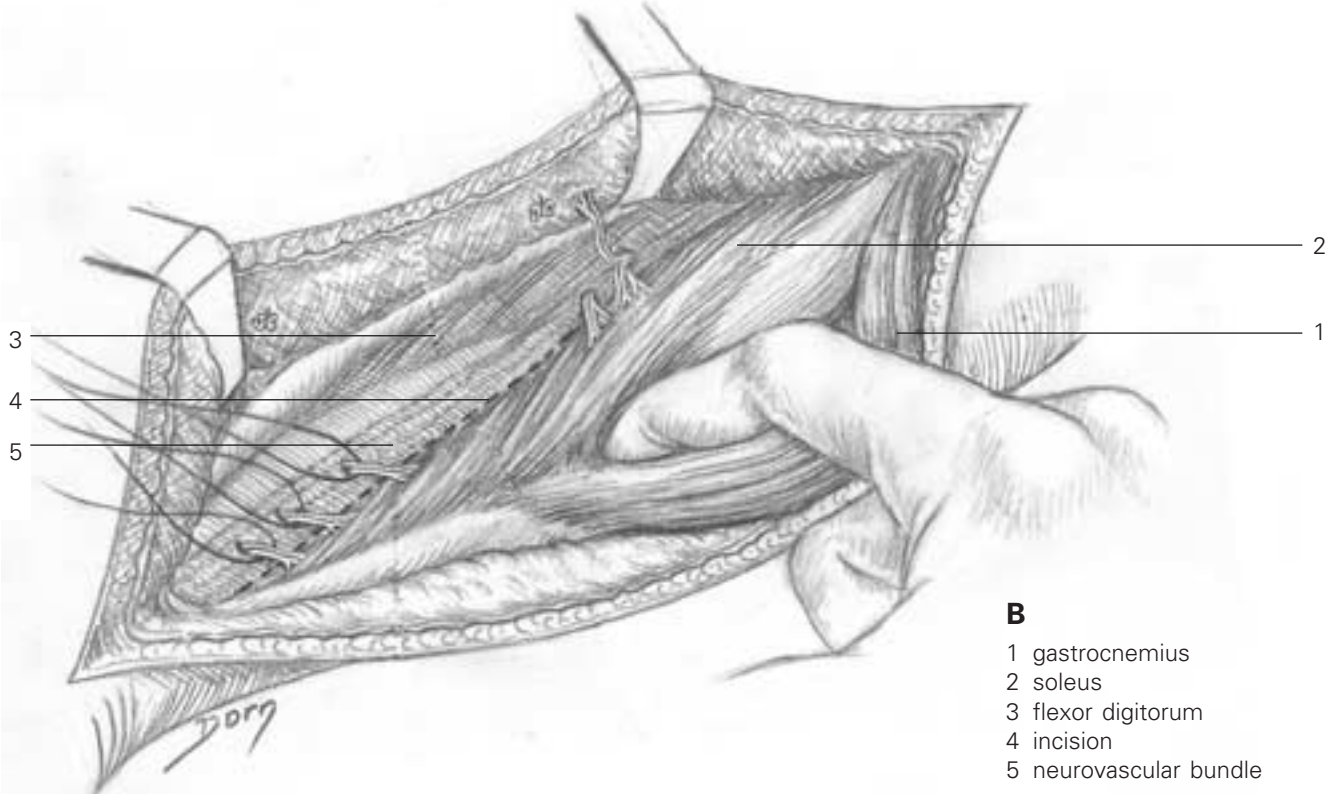
A The muscle is exposed on the medial aspect of the leg. Two planes of dissection are developed: (i) between the soleus and the medial head of the gastrocnemius and (ii) between the soleus and the deep posterior compartment of the leg.



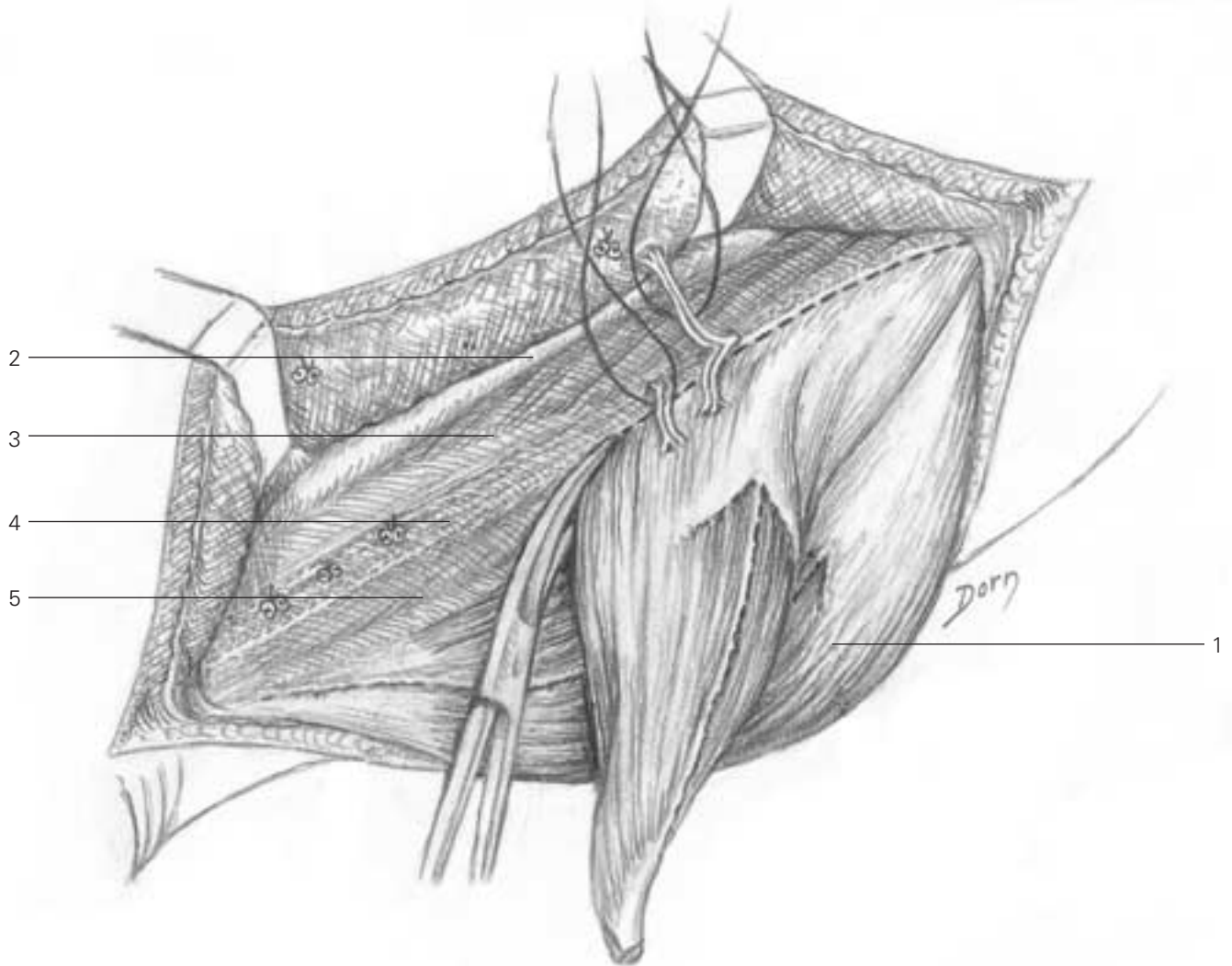
- 1 gastrocnemius (medial head)
- 2 soleus
- 3 deep posterior compartment

Reconstructive surgery

B, C The distal portion of the soleus is isolated and separated from Achilles' tendon.



D The distal extremity of the muscle has been freed and the flap is raised from distal to proximal.



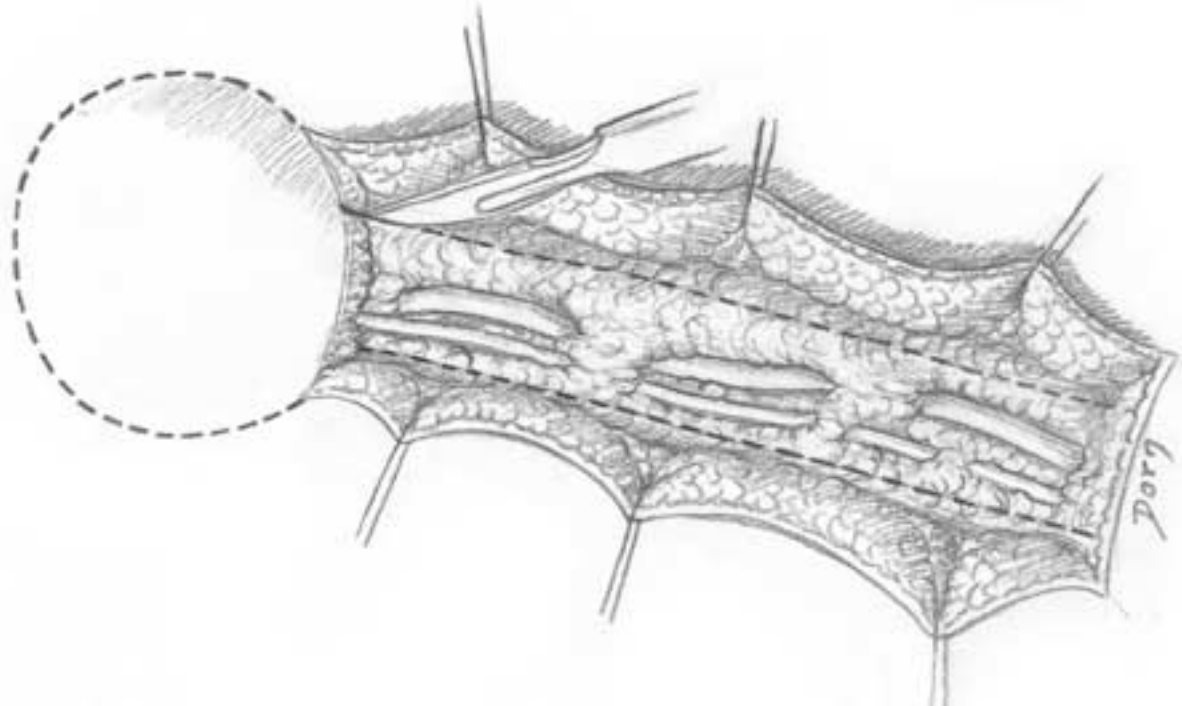
- D**
- 1 gastrocnemius
 - 2 tibia
 - 3 flexor digitorum longus
 - 4 nerve and vessels
 - 5 flexor hallucis longus

Reconstructive surgery

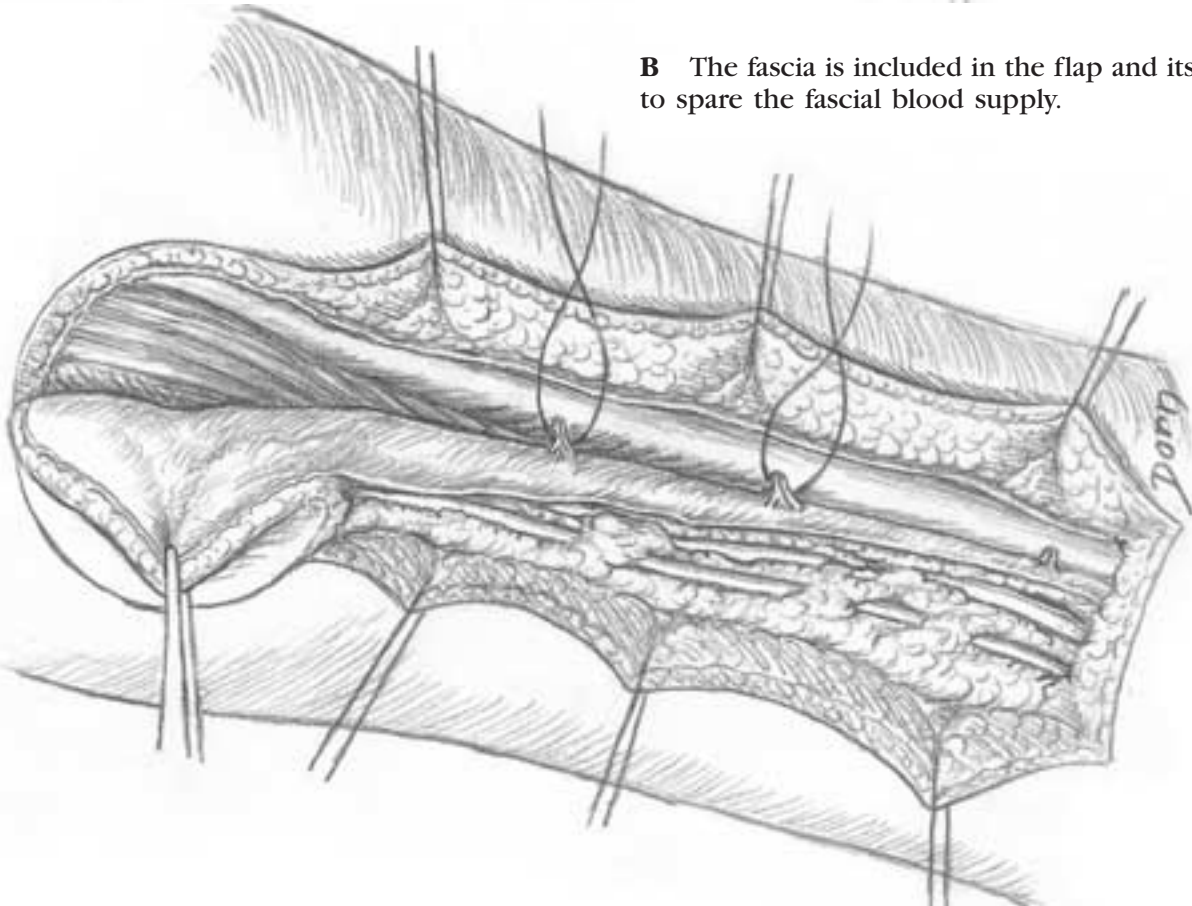
Sural skin flap

The sural skin flap is a neurocutaneous flap which is raised on the posterior aspect of the calf.

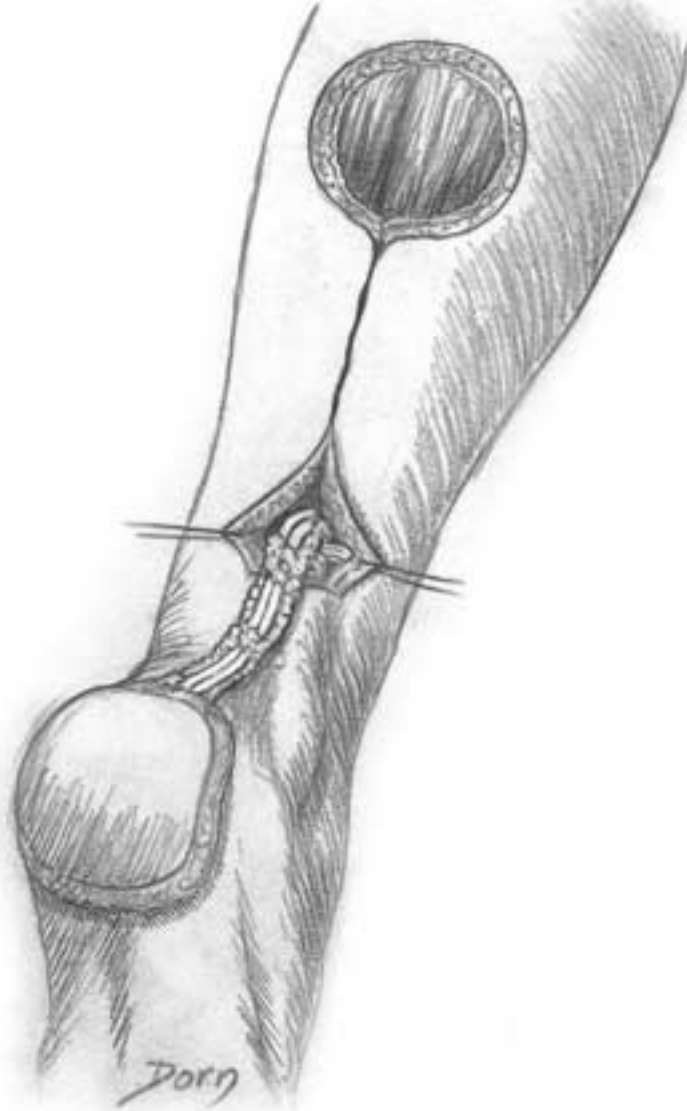
A The skin paddle is isolated on an adipofascial pedicle which contains a vein, superficial nerve and arterial network.



B The fascia is included in the flap and its pedicle to spare the fascial blood supply.



C This flap is indicated for covering a defect over the posterior heel. It is supplied by a perforating vessel issued from the peroneal artery.



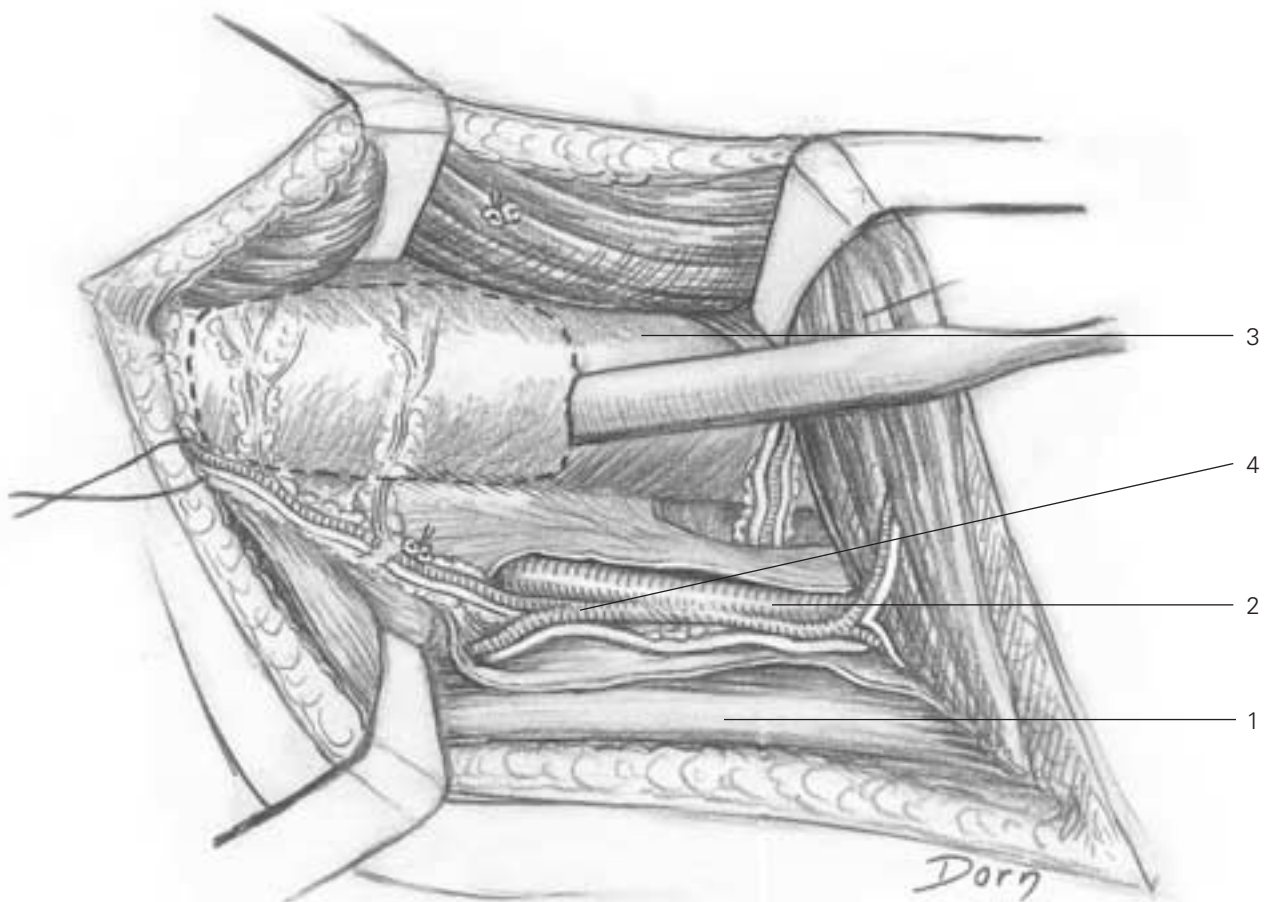
Vascularised bone transfers

Vascularised bone transfers have dramatically improved the treatment of bone defects. Healing occurs quickly avoiding the state of 'creeping substitution' specific to the revascularisation of conventional bone grafts.

Vascularised osteoperiosteal flap from the femur

This transfer is chiefly indicated in craniofacial surgery. It can also be used as a pedicled island flap to promote bone healing in a recalcitrant non-union of the femur.

The flap is detached from the medial aspect of the distal metaphysis of the femur. It is supplied by the descending genicular artery that issues from the lower femoral artery.

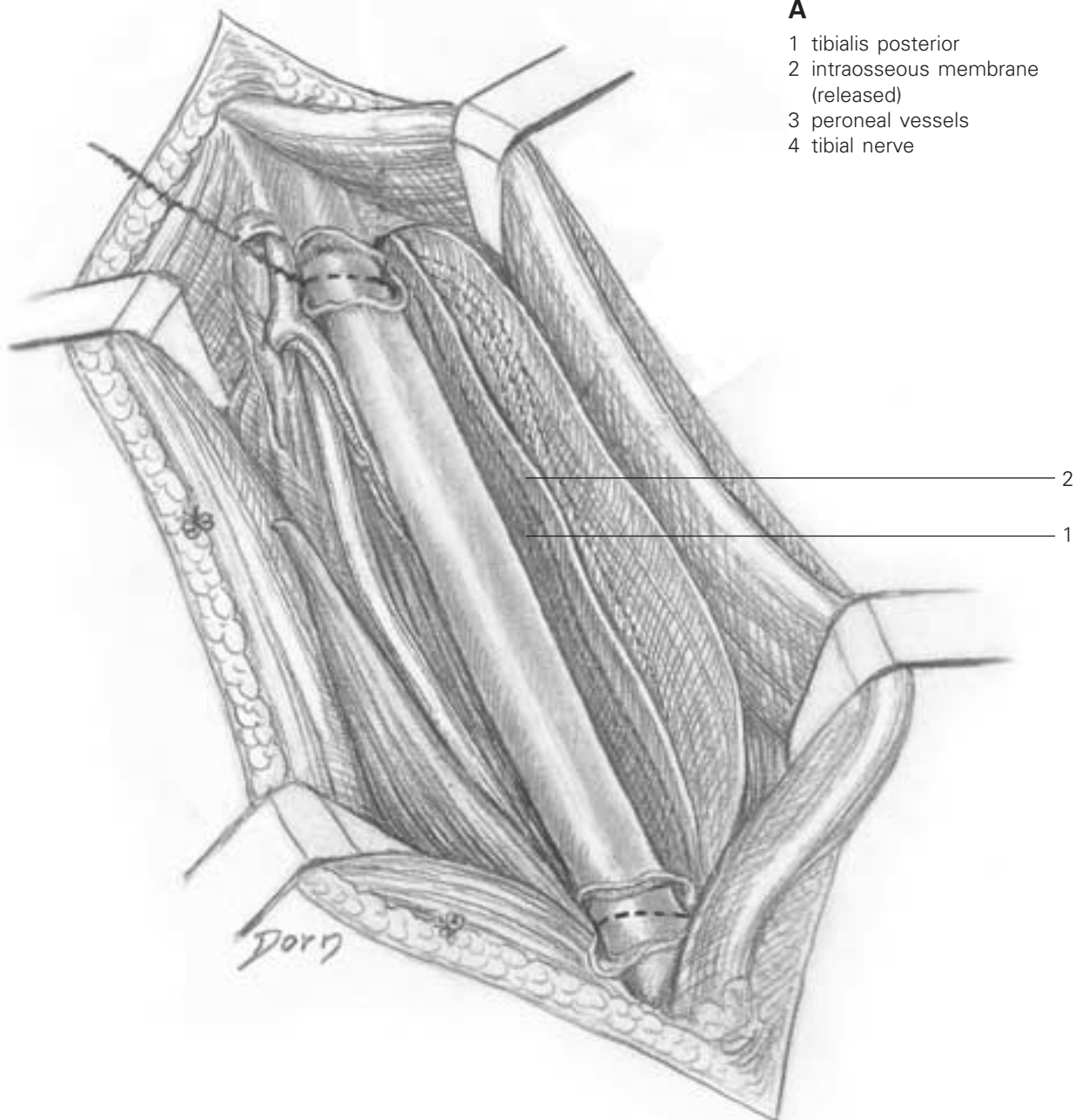


- 1 adductor magnus tendon
- 2 lower femoral artery
- 3 femur
- 4 descending genicular artery

Vascularised fibula transfer

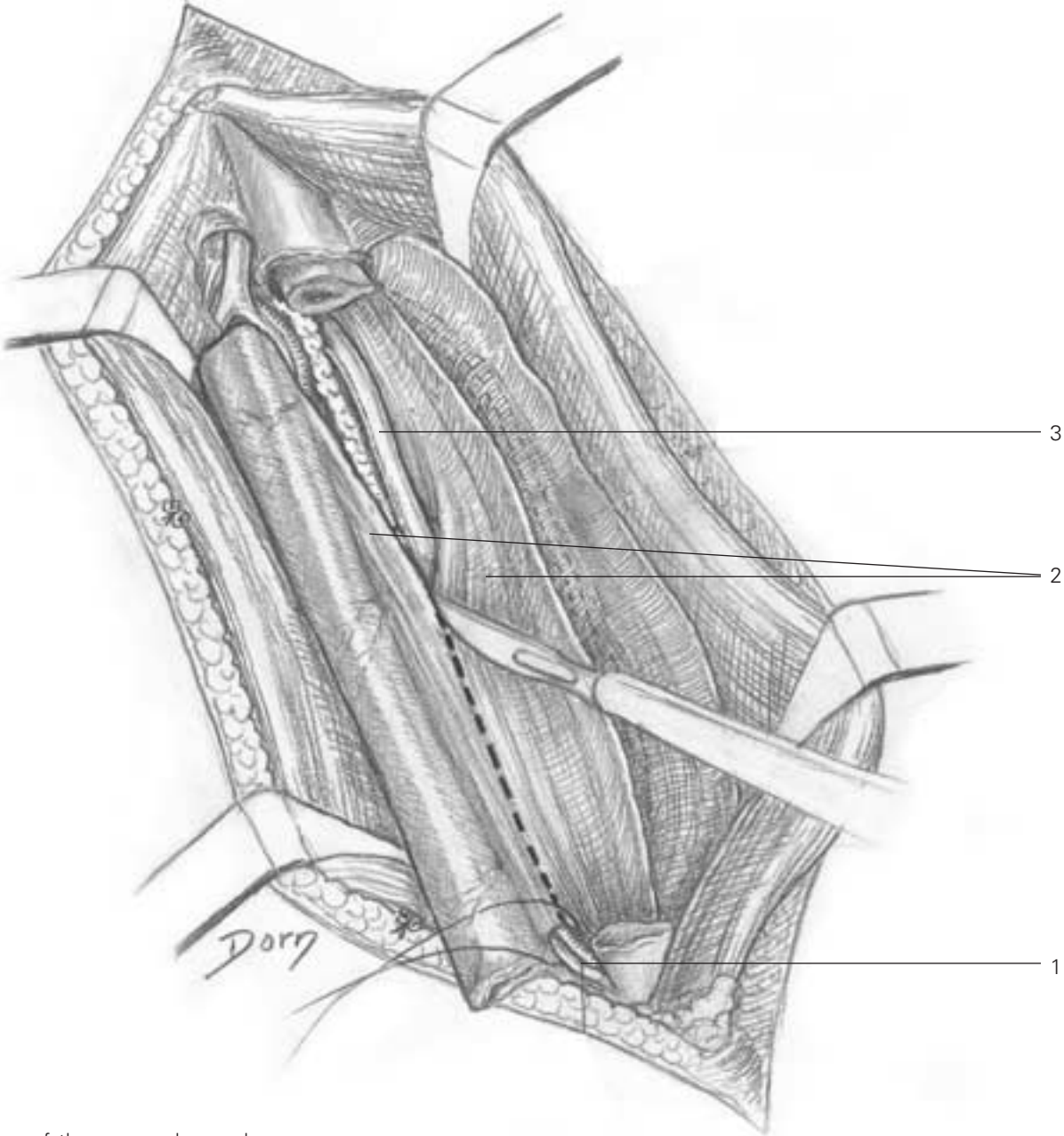
The vascularised fibula is now of much interest in reconstructive surgery of long bone defects.

A The fibula has been isolated with the peroneal vessels remaining protected by a portion of the tibialis posterior or the flexor hallucis longus muscles. The transfer is severed at both extremities, sparing a cuff of periosteum.



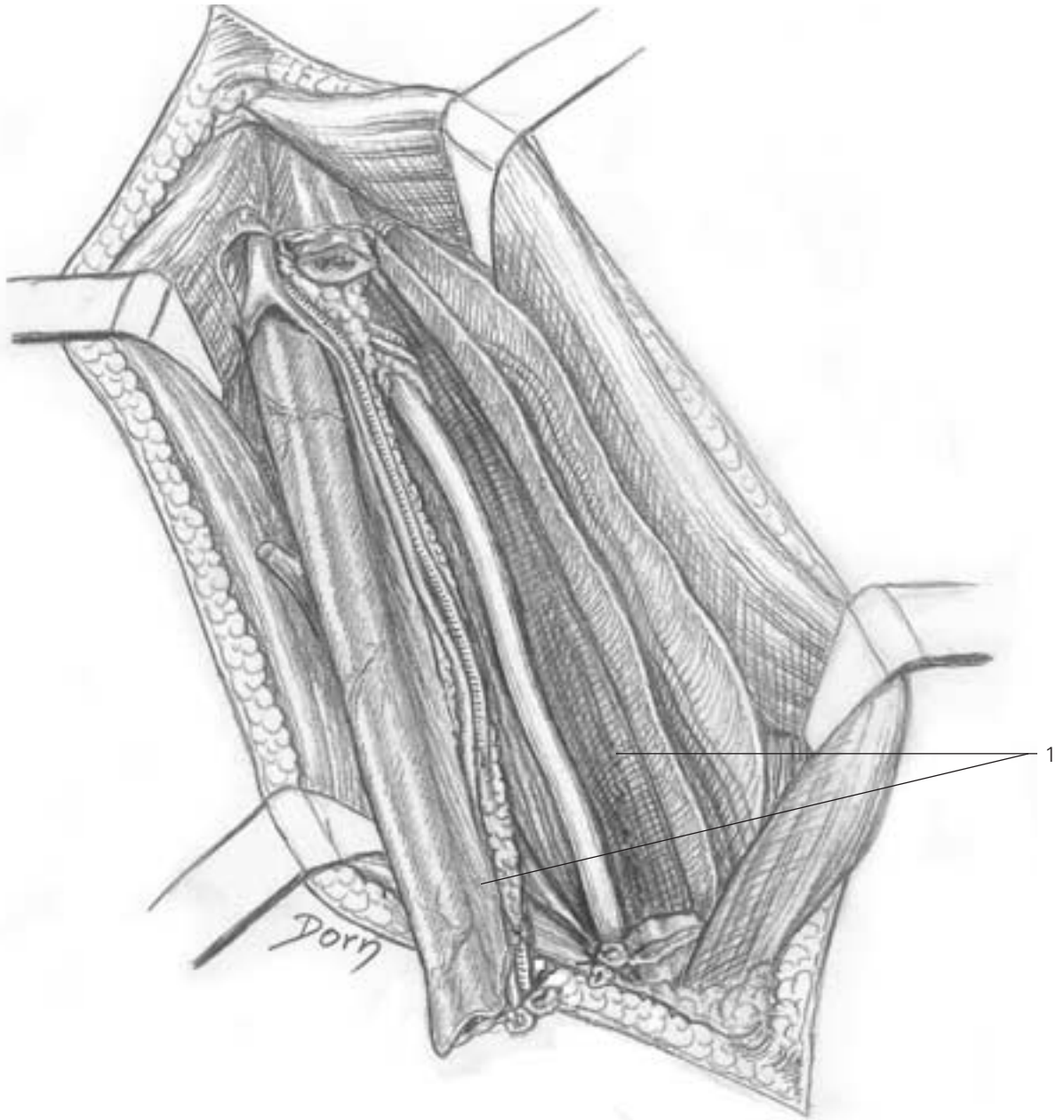
Reconstructive surgery

B A portion of tibialis posterior muscle remains attached to the fibula to protect the peroneal vessels which supply the bone.



- B**
- 1 distal ligation of the peroneal vessels
- 2 tibialis posterior (split)
- 3 tibial nerve

C The transfer is completely isolated on its pedicle.



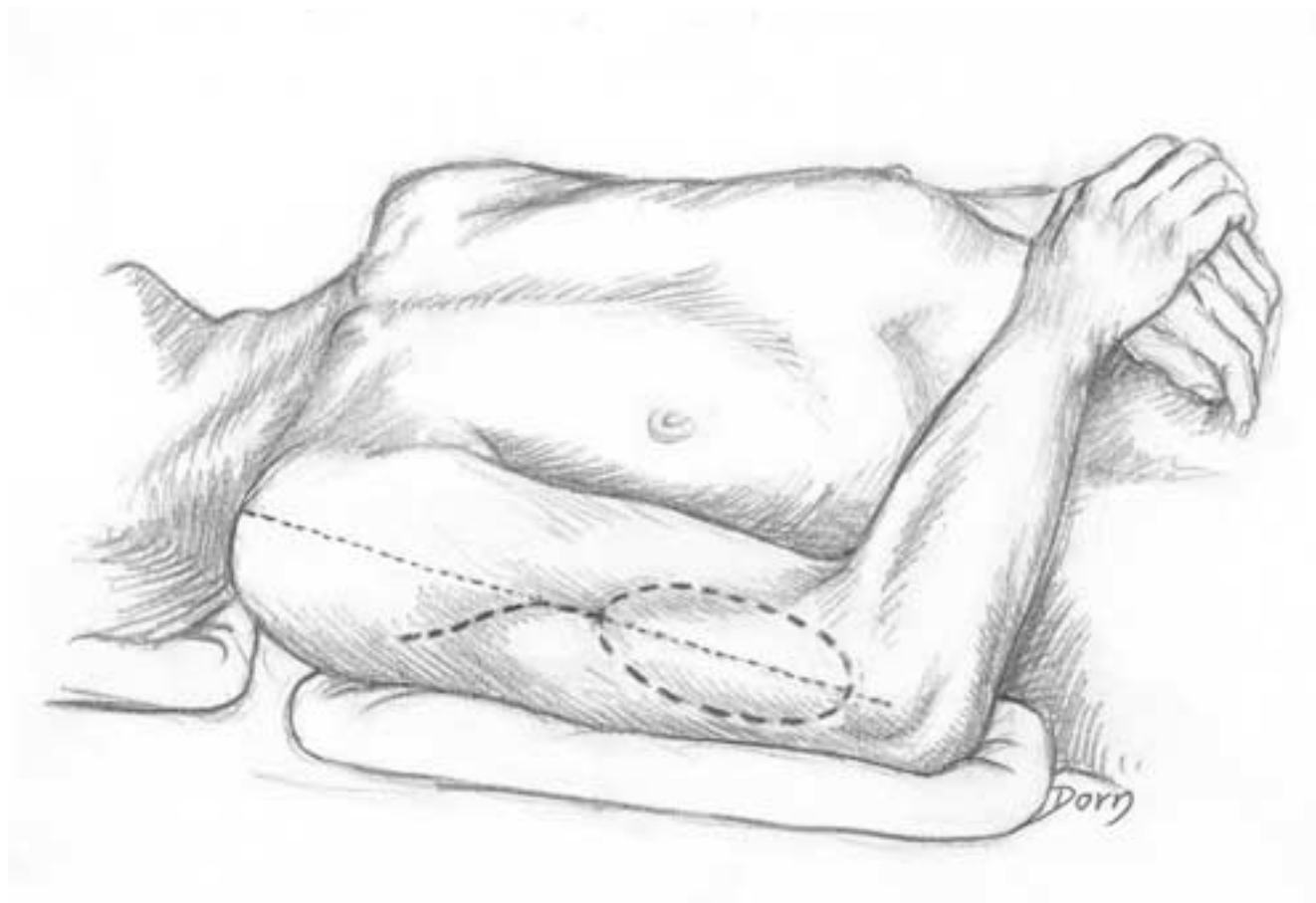
C
1 tibialis posterior (split)

Flaps from the upper limb

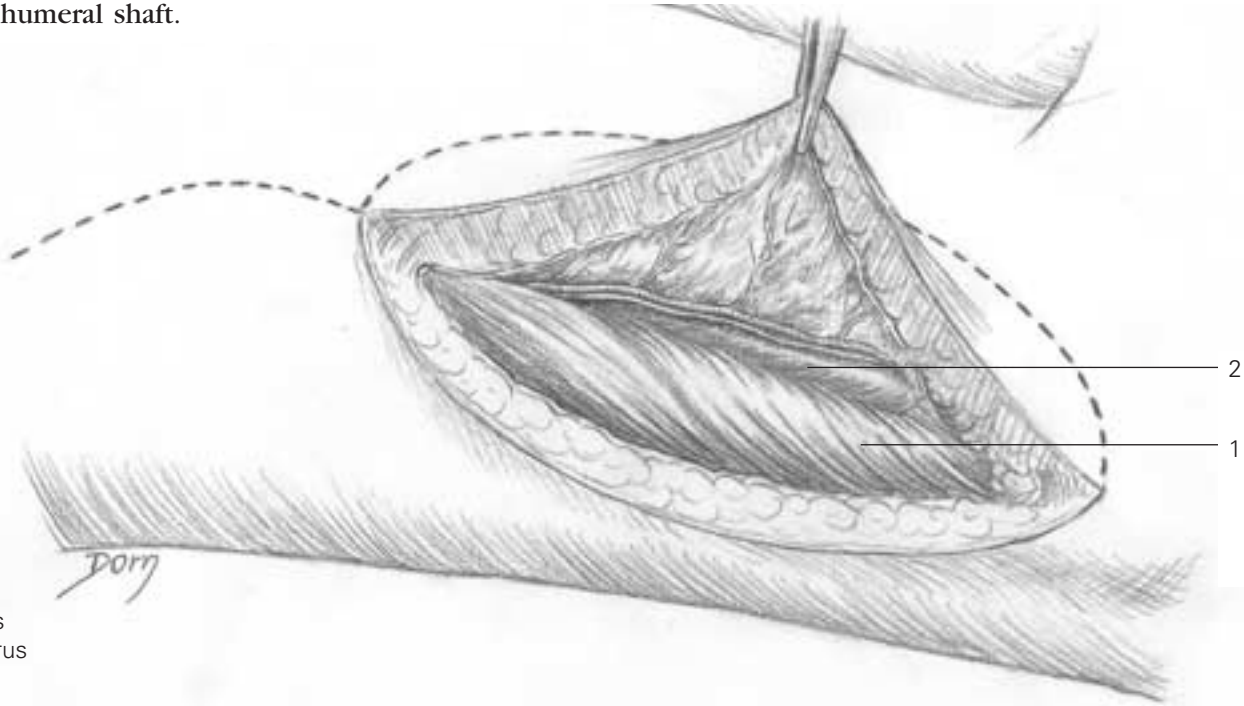
Lateral brachial flap

The lateral brachial flap is raised on the lateral aspect of the arm and is available as a pedicled flap or a free flap. It can be combined with a piece of bone from the humerus.

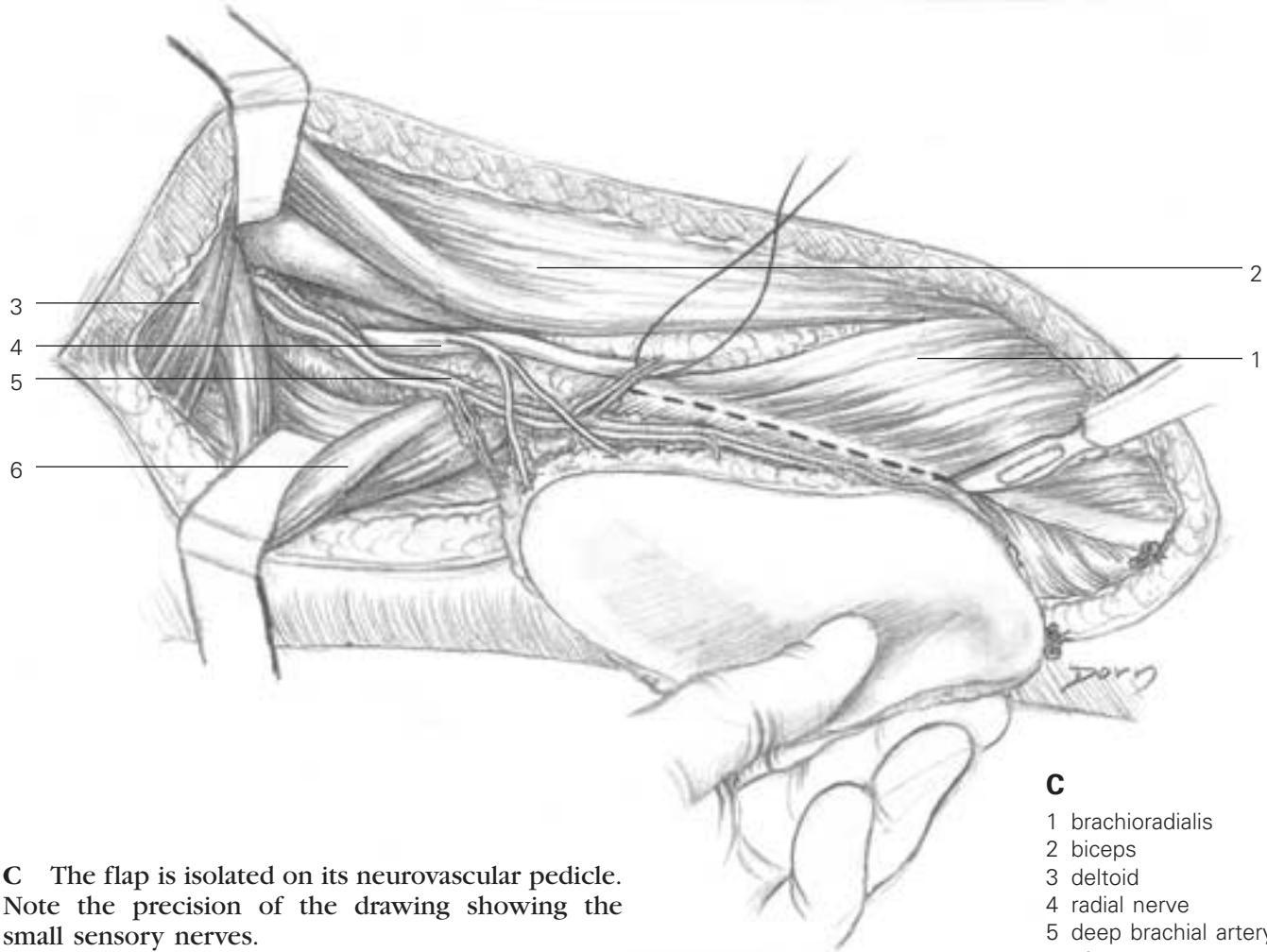
A Incision - the blood supply comes from the posterior branch of the brachial artery.



B The vessels are seen within the septum inserted on the humeral shaft.



B
1 triceps
2 humerus



C The flap is isolated on its neurovascular pedicle. Note the precision of the drawing showing the small sensory nerves.

C
1 brachioradialis
2 biceps
3 deltoid
4 radial nerve
5 deep brachial artery
6 triceps

Reconstructive surgery

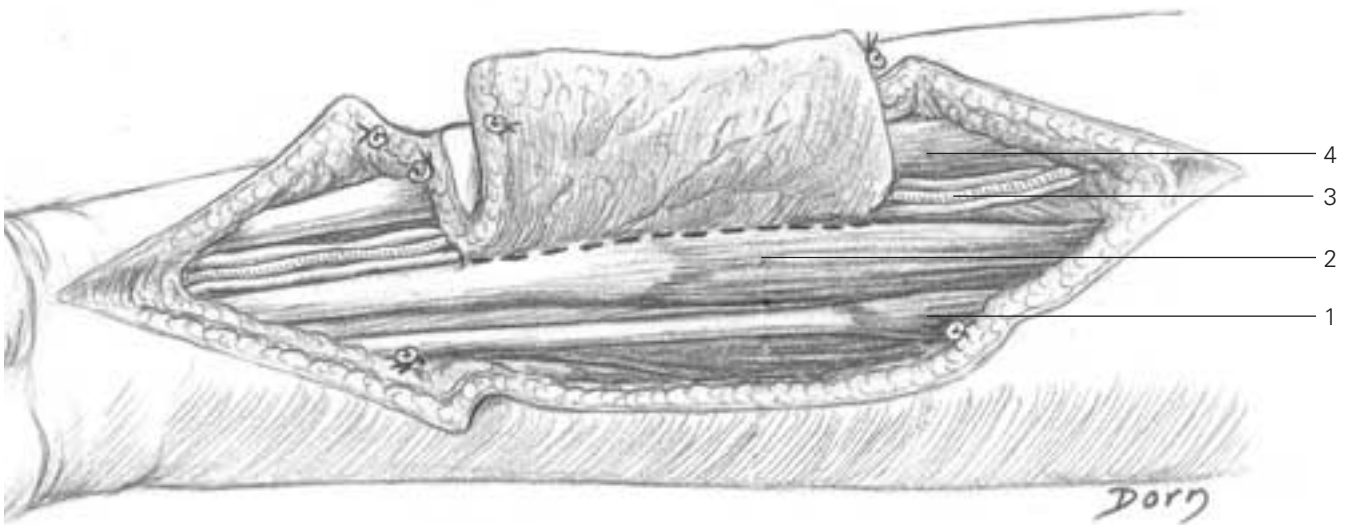
Forearm radial flap

This flap was the origin of a true revolution in 1980. Described by Chinese authors it is supplied by the radial artery and started the era of distally based pedicled island flaps, with retrograde blood flow, which were initially considered difficult to achieve.

A, B The flap is raised progressively on its vascular axis which is maintained in continuity during the first step of the dissection.

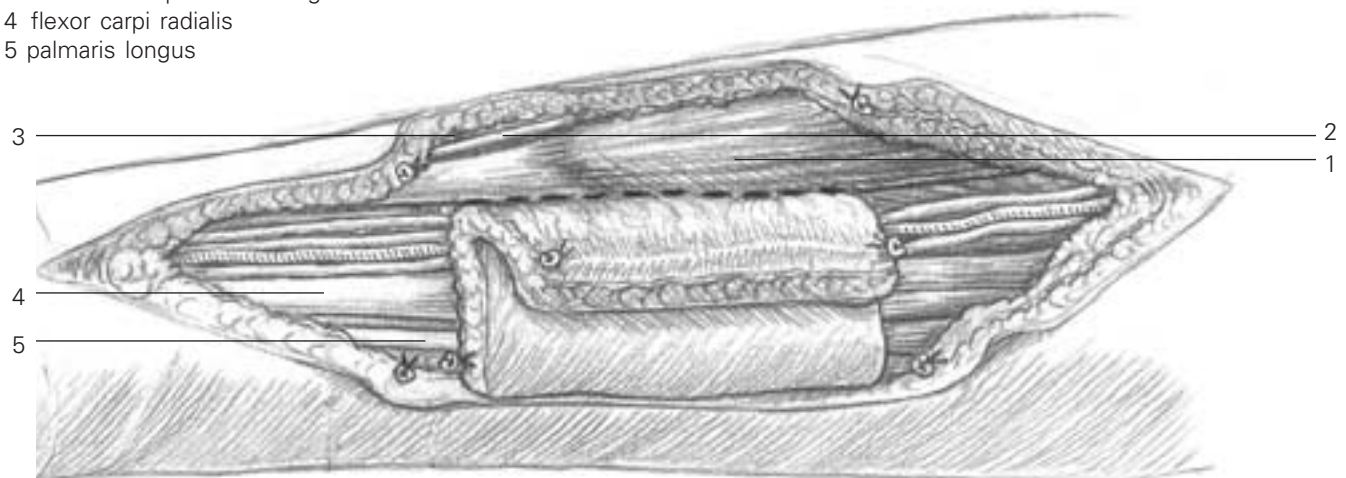
A

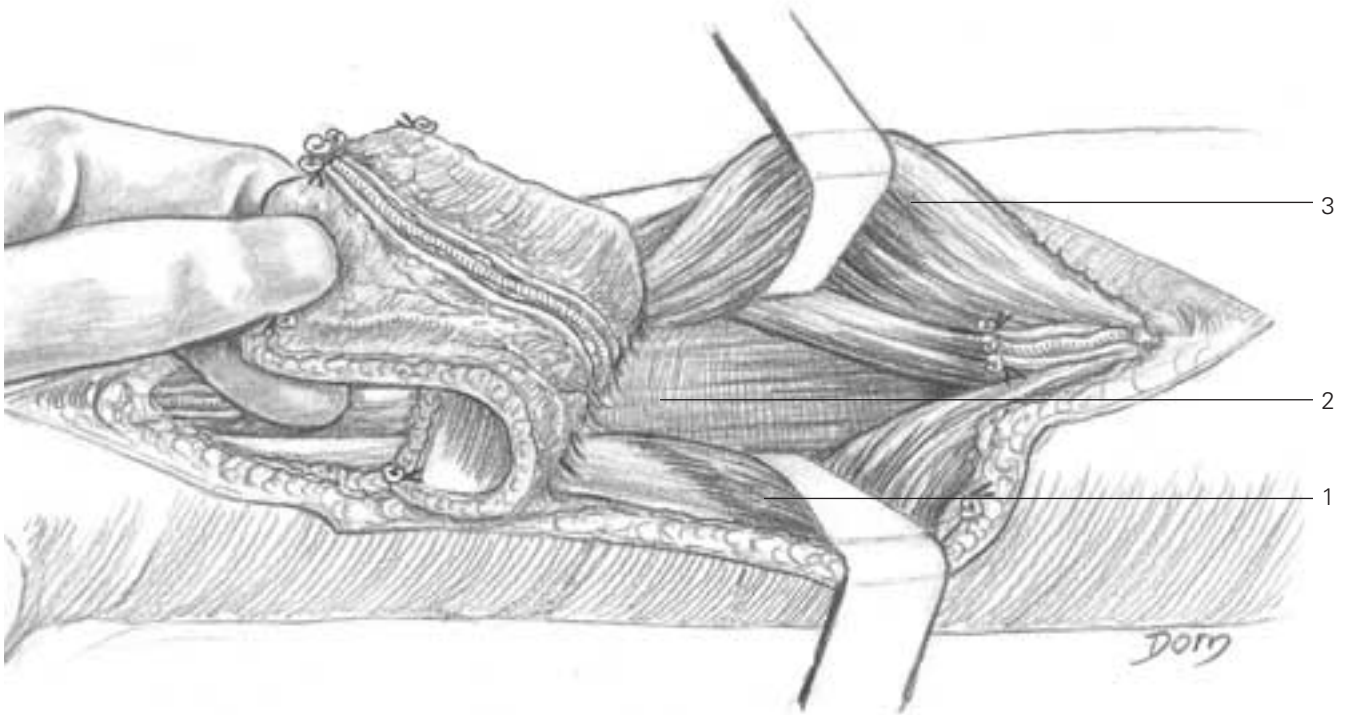
- 1 palmaris longus
- 2 flexor carpi radialis
- 3 radial artery
- 4 brachioradialis



B

- 1 brachioradialis
- 2 radial nerve (sensitive branch)
- 3 extensor carpi radialis longus
- 4 flexor carpi radialis
- 5 palmaris longus





C The radial artery has been severed proximal to the flap. The pivot point of the pedicle is at the level of the wrist. The flap is convenient for covering any defect of the hand.

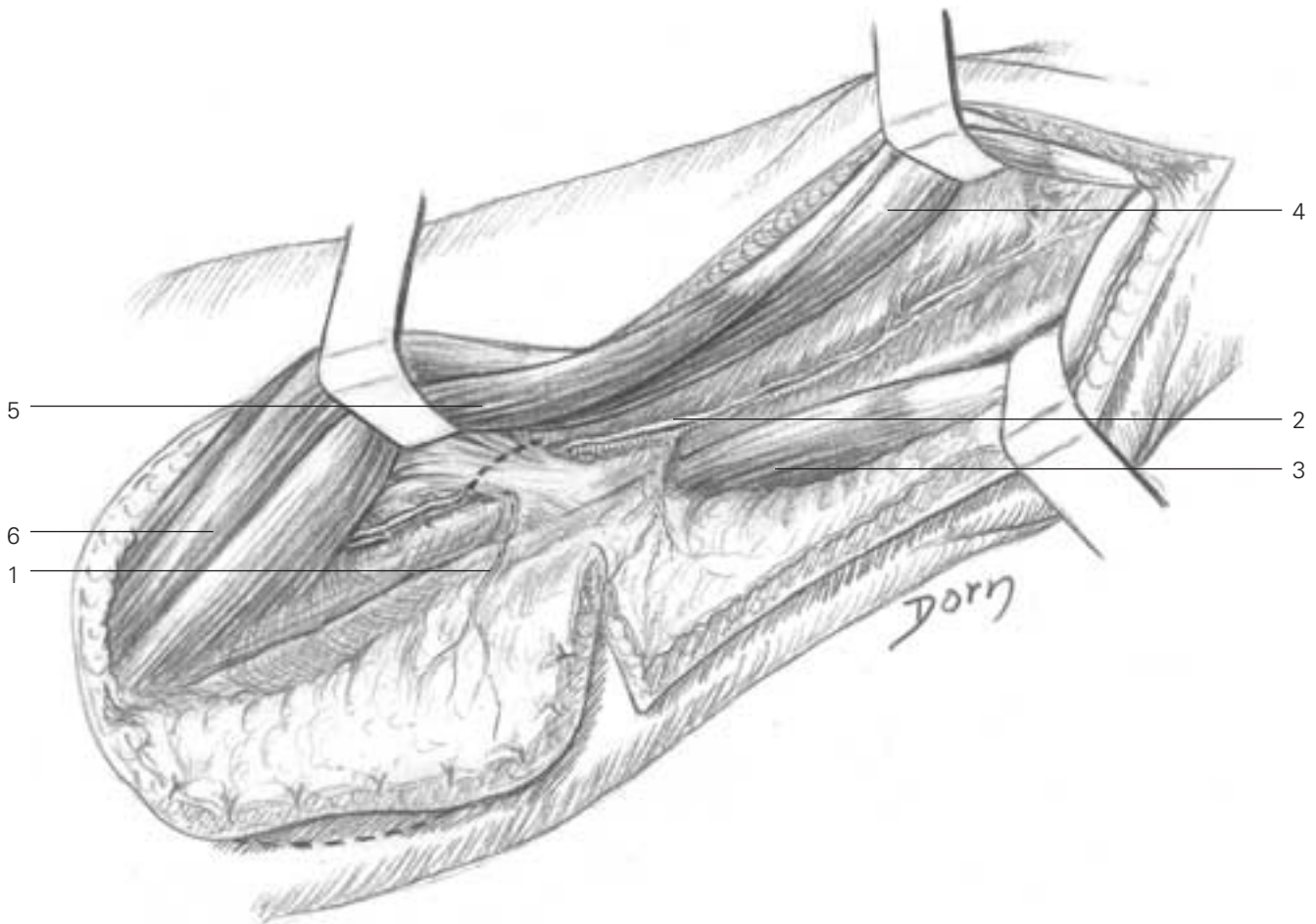
- C**
- 1 flexor carpi radialis
 - 2 flexor digitorum superficialis
 - 3 brachioradialis

Reconstructive surgery

Posterior interosseous flap

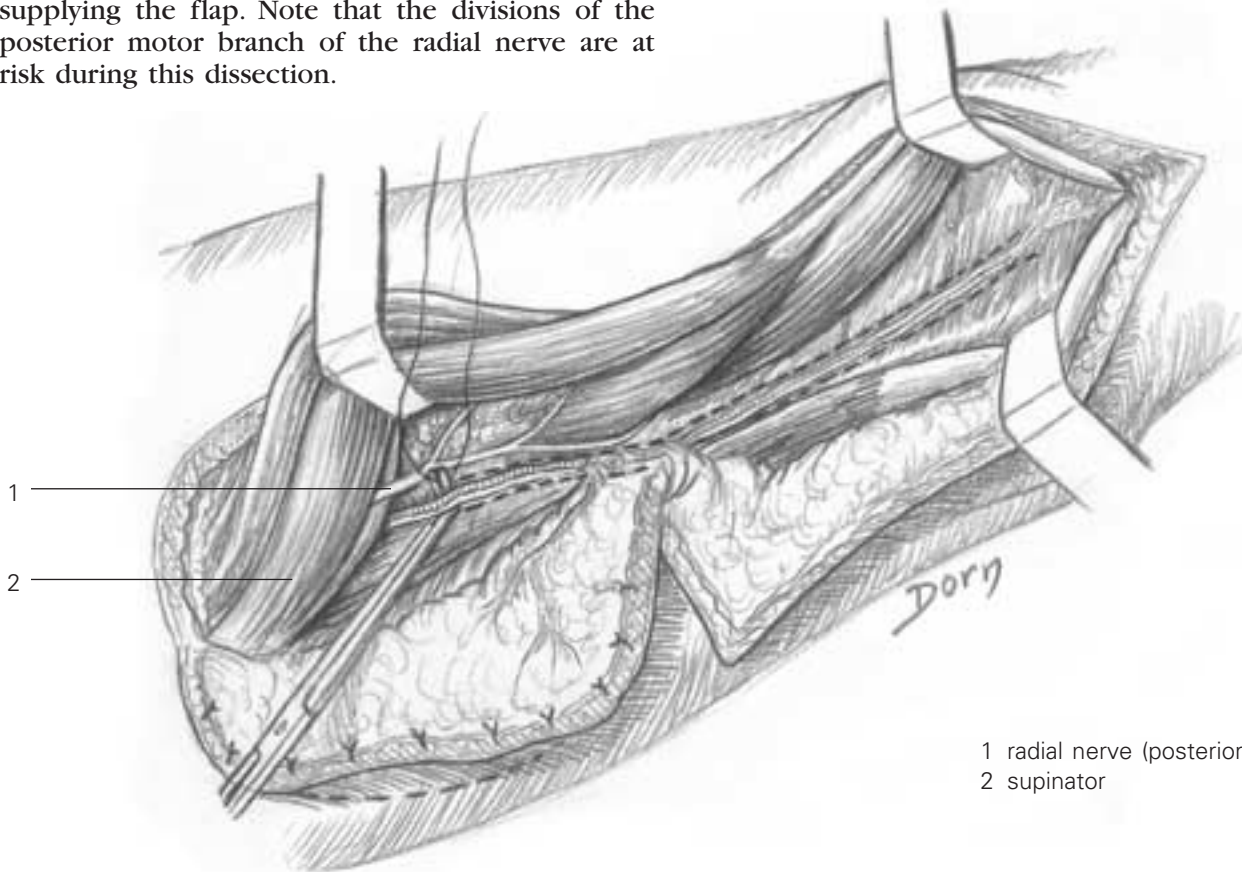
The flap is raised on the posterior aspect of the forearm. The advantage of this flap is the absence of sacrifice of a main vascular axis, since it is supplied by a small artery called the posterior interosseous artery. The technique is not easy and it is difficult to represent by drawings because of the different planes of perspective in depth.

A The flap is partially raised; a posterior hinge is maintained while exploring the vessels.



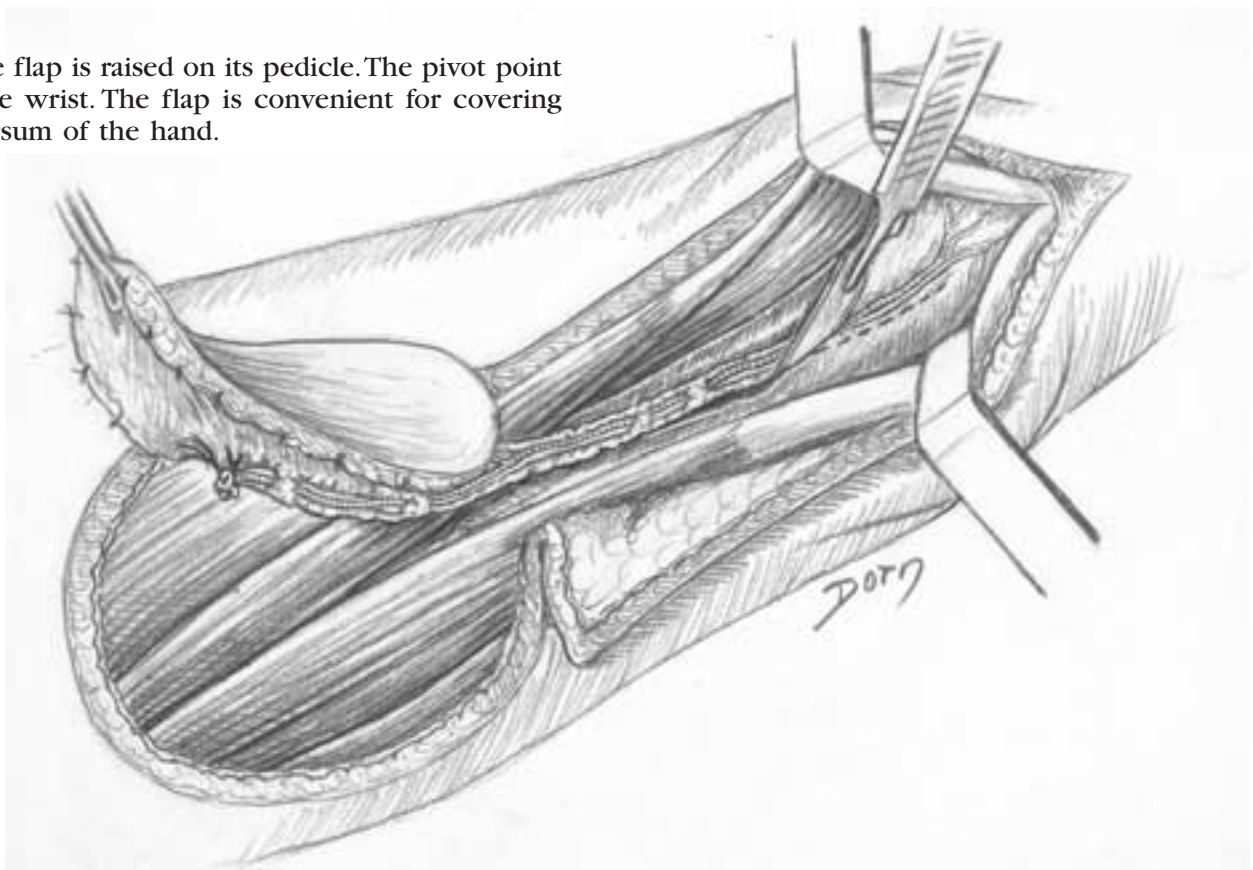
- 1 arterial branch to the flap
- 2 posterior interosseous artery
- 3 extensor carpi ulnaris
- 4 extensor indicis proprius
- 5 extensor digiti quinti
- 6 extensor digitorum

B The artery is severed proximal to the branch supplying the flap. Note that the divisions of the posterior motor branch of the radial nerve are at risk during this dissection.



- 1 radial nerve (posterior branch)
- 2 supinator

C The flap is raised on its pedicle. The pivot point is at the wrist. The flap is convenient for covering the dorsum of the hand.

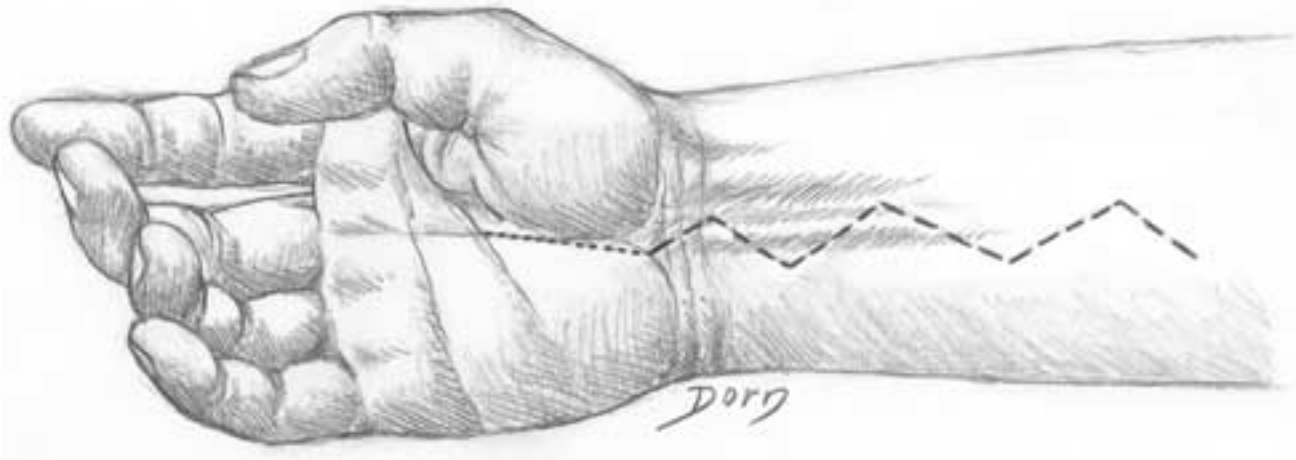


Reconstructive surgery

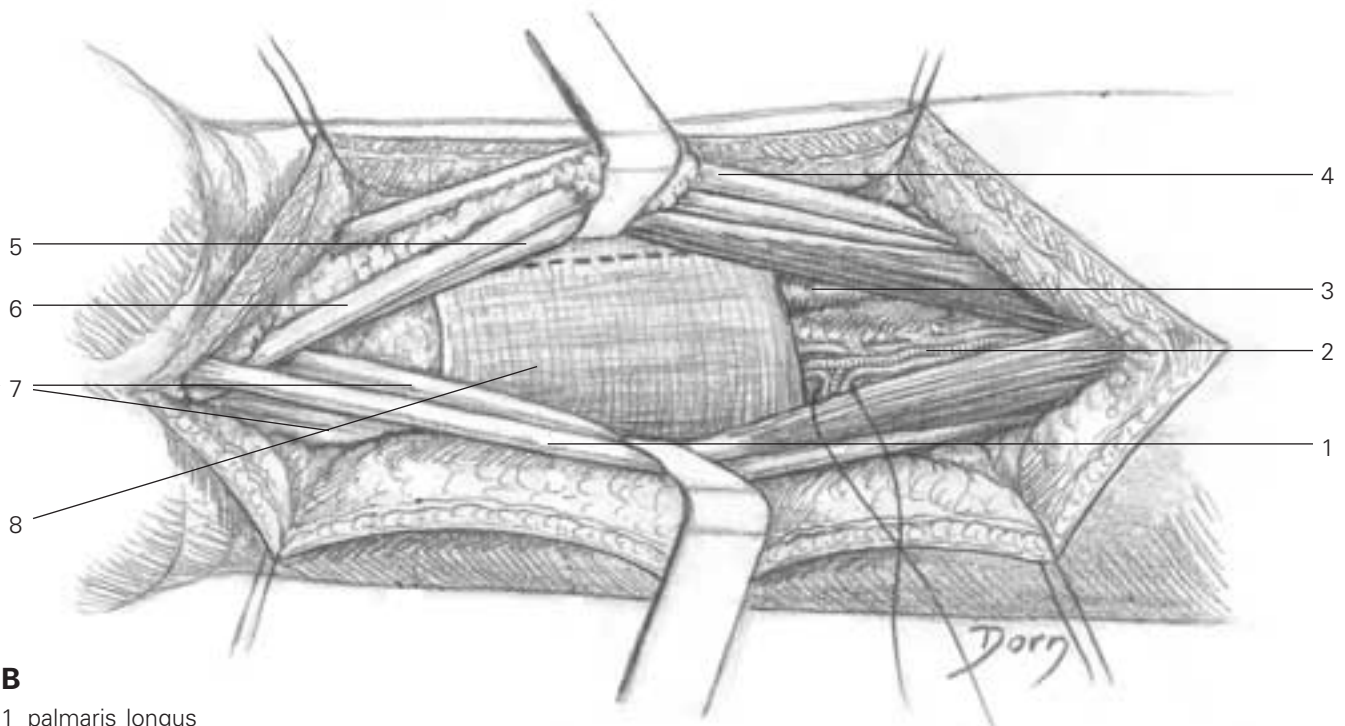
Pronator quadratus muscle flap

This flap is rarely used. However, the dissection is very fine and so are the drawings.

A Skin incision.

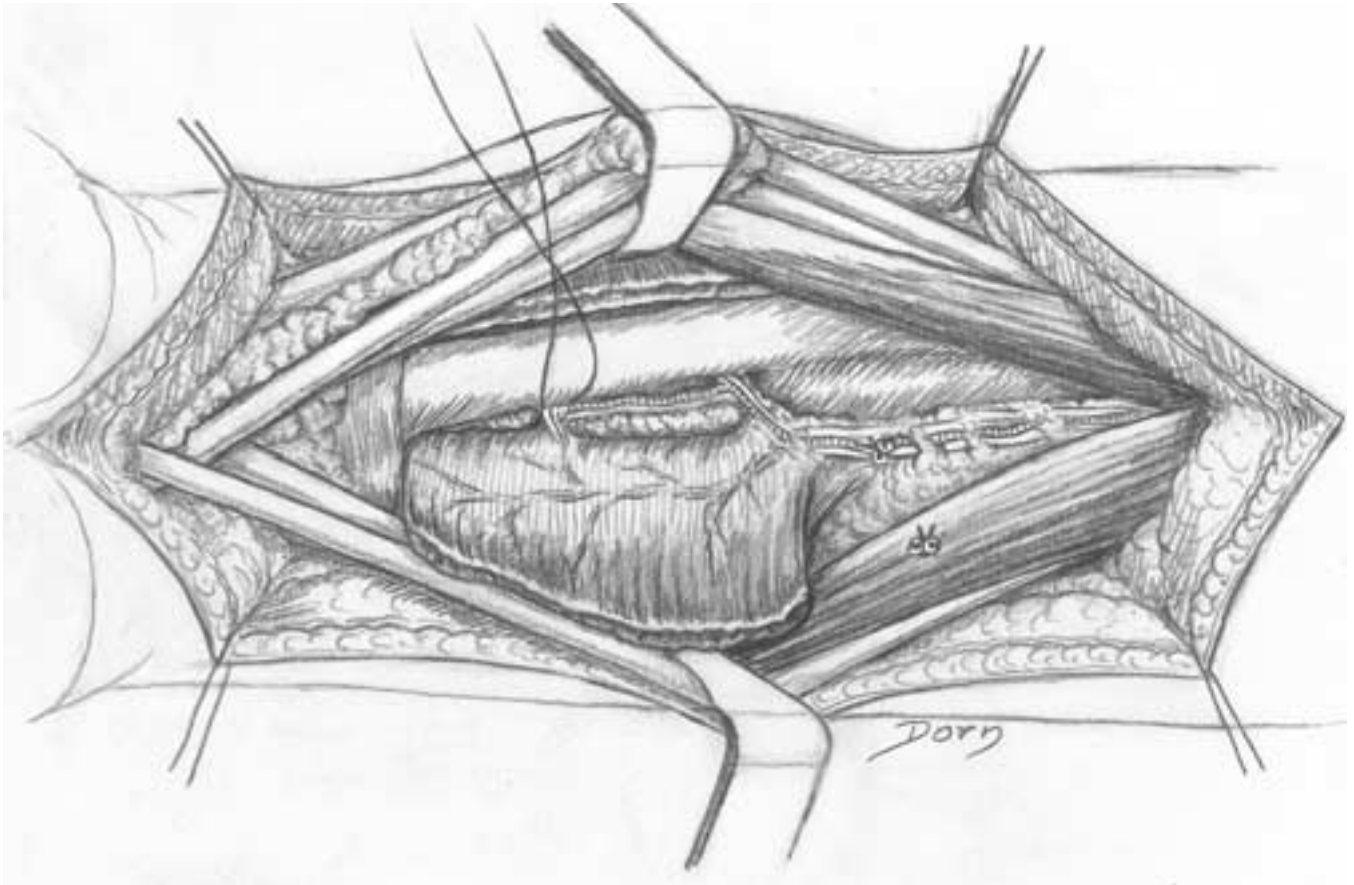


B Exposure of the pronator quadratus muscle.



- B**
- 1 palmaris longus
 - 2 anterior interosseous vessels
 - 3 radius
 - 4 flexor carpi radialis
 - 5 flexor hallucis longus
 - 6 median nerve
 - 7 flexor digitorum superficialis
 - 8 pronator quadratus

C The flap is raised on the anterior interosseous artery.



Hand and peripheral nerve surgery

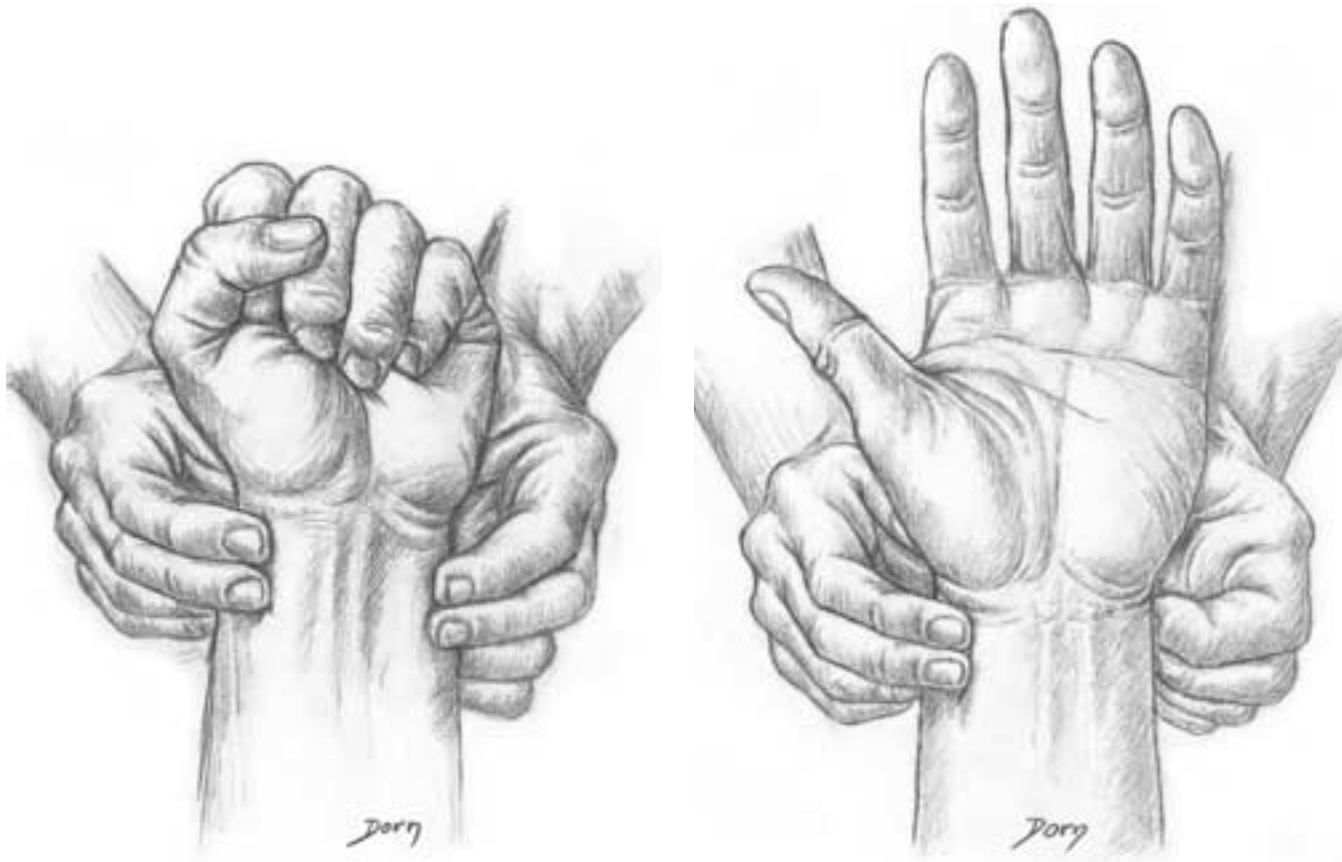
The hand is probably a field of predilection for Léon Dorn. He has worked very hard as the hand is not easy to depict. Dorn was the renowned collaborator of Raoul Tubiana for the monumental book *Chirurgie de la Main*.

Among Dorn's vast production of illustrations of the hand can be seen some which truly demonstrate the true skill of the artist.

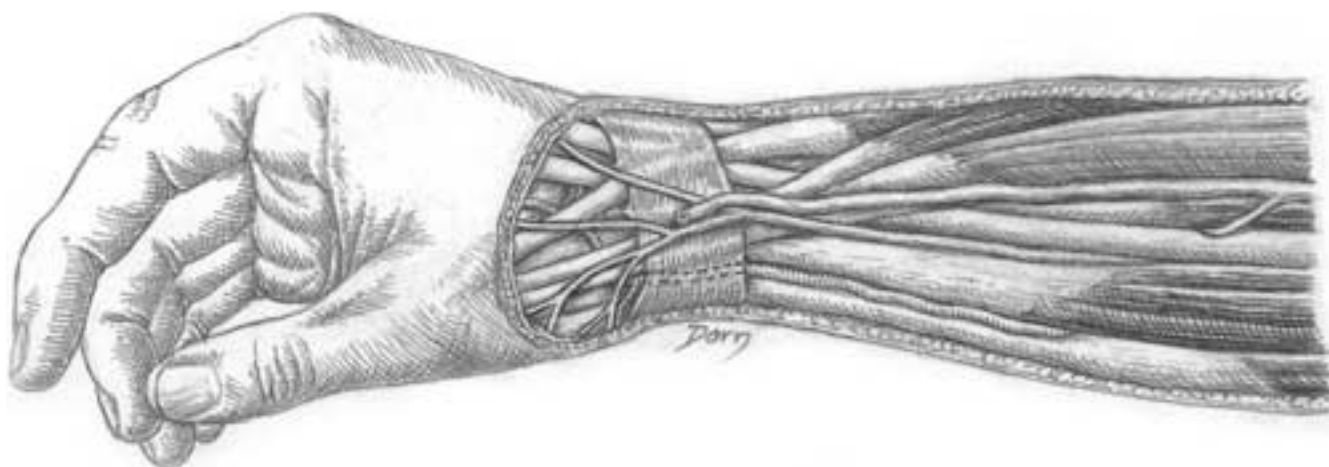
Hand and peripheral nerve surgery

Anatomy of the hand

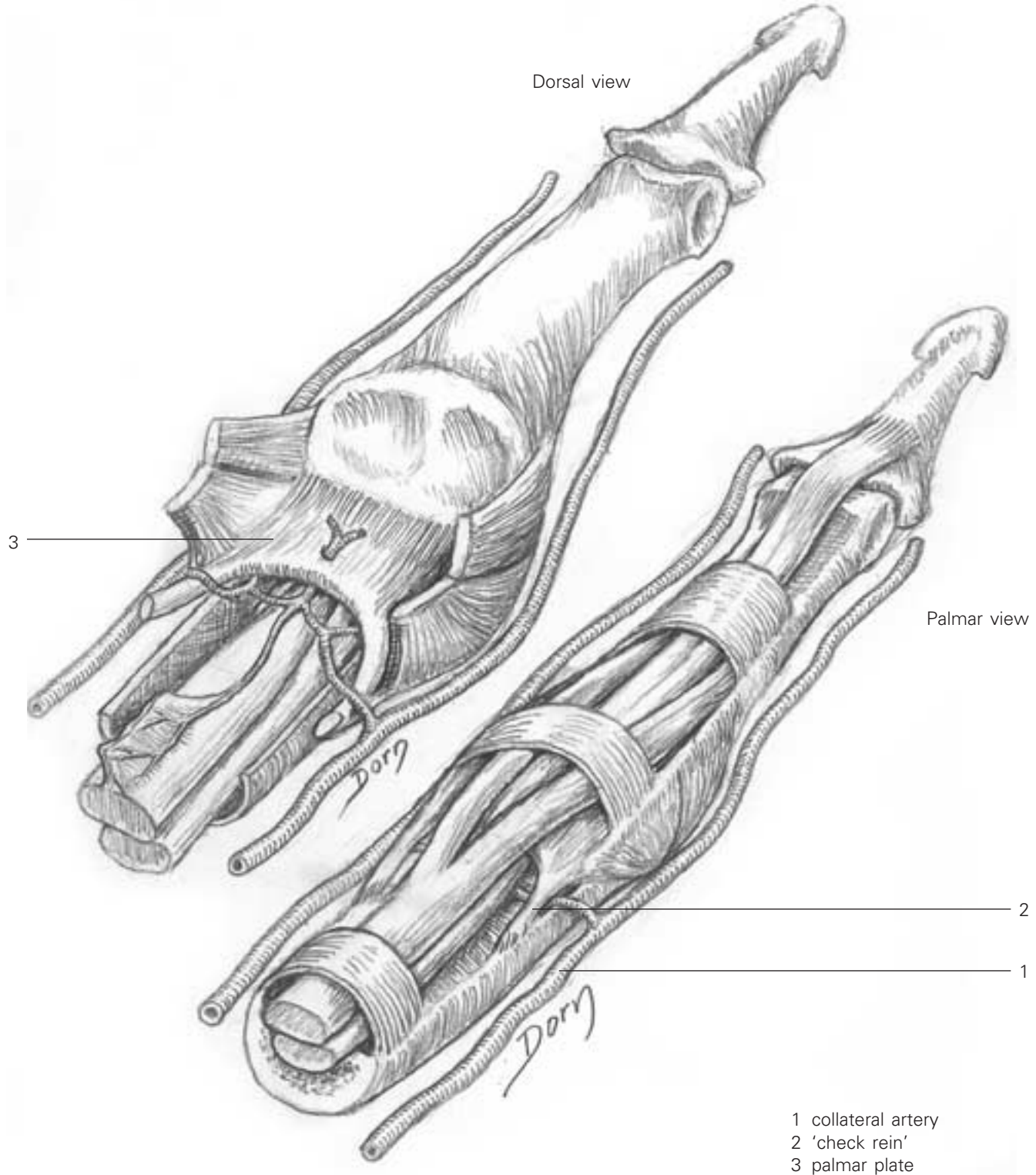
A Allen's test - the principle is to assess the permeability (patency test) of each artery of the hand.



B The radial aspect of the wrist and forearm. Note the divisions of the sensory branch of the radial nerve.

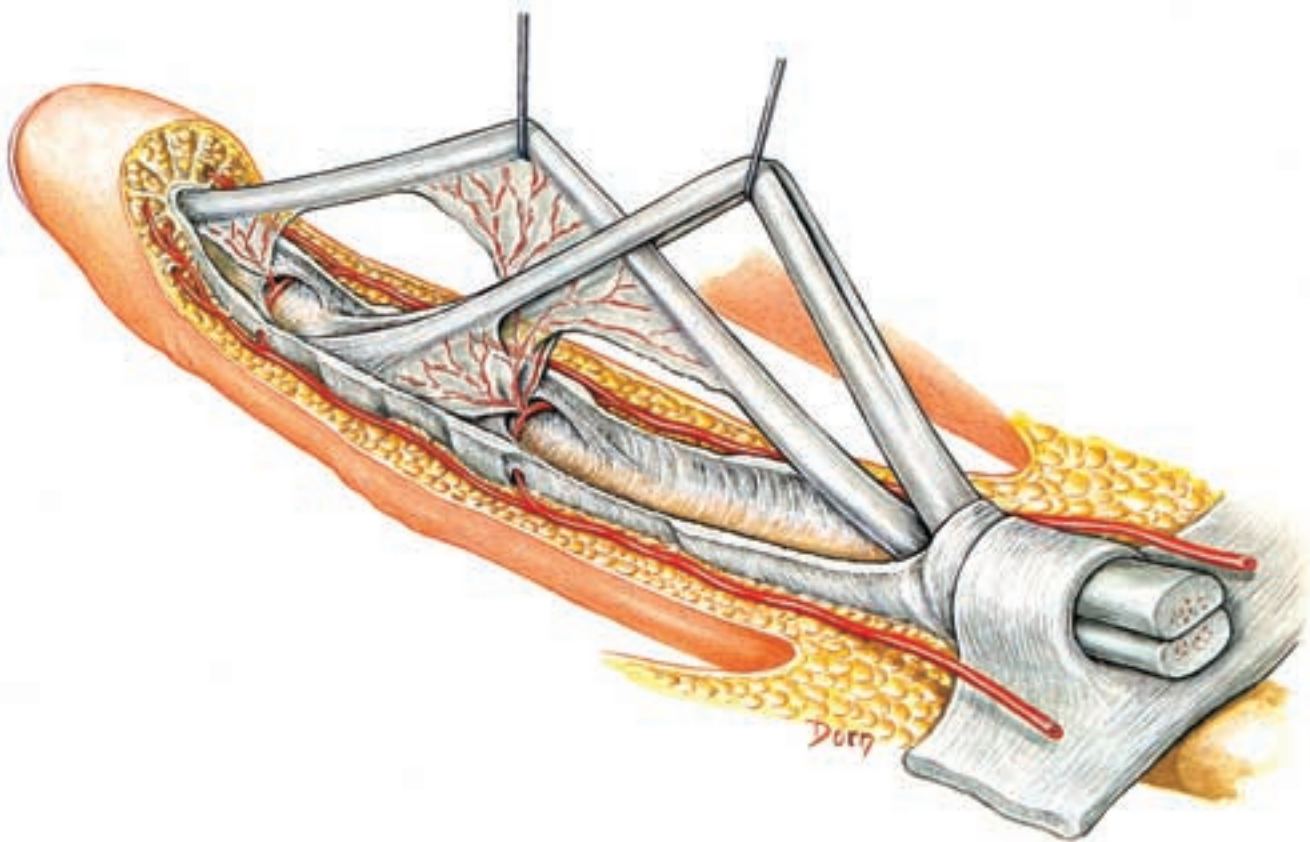


C Blood supply to the flexor tendons of the fingers. Note the small pedicles issuing from the collateral artery. They pass beneath the 'check reins' of the capsule of the PIP joint and divide into several branches. One branch is devoted to the vinculum.



Hand and peripheral nerve surgery

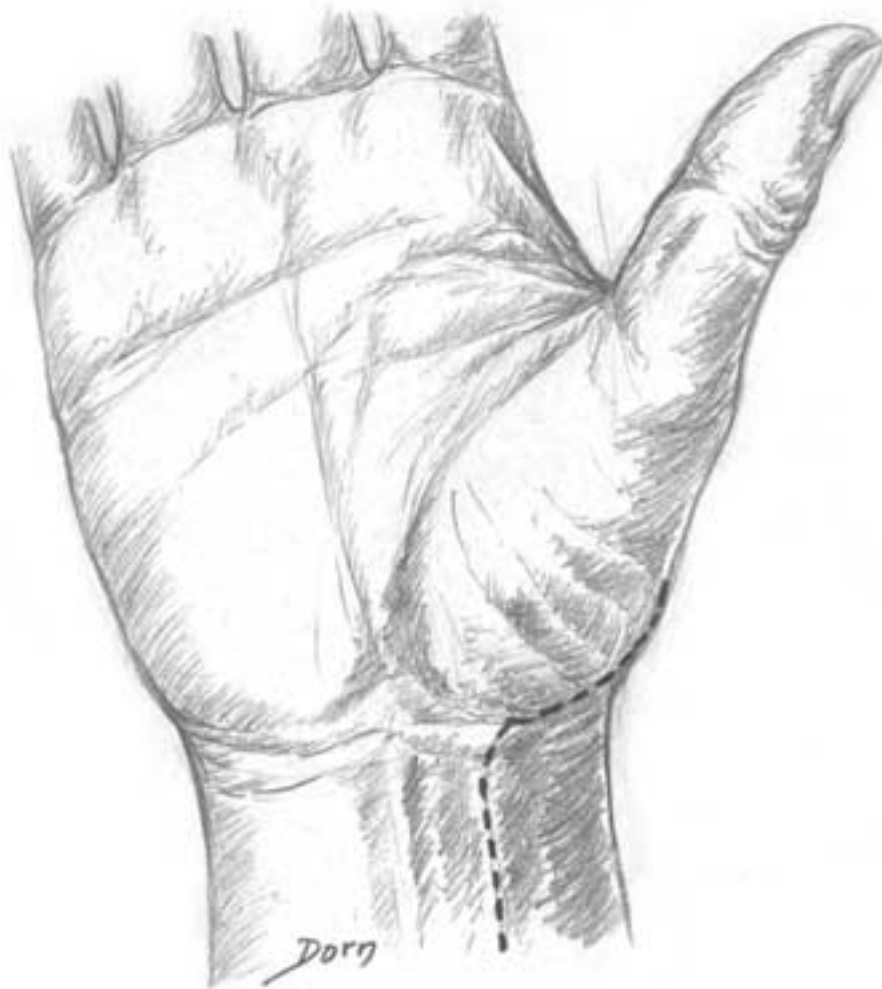D The blood supply to the profundus tendon comes from the vinculum of the superficialis tendon. Hence the superficialis tendon should not be excised when both tendons are divided; rather both tendons should be repaired.



The trapezium: volar approach

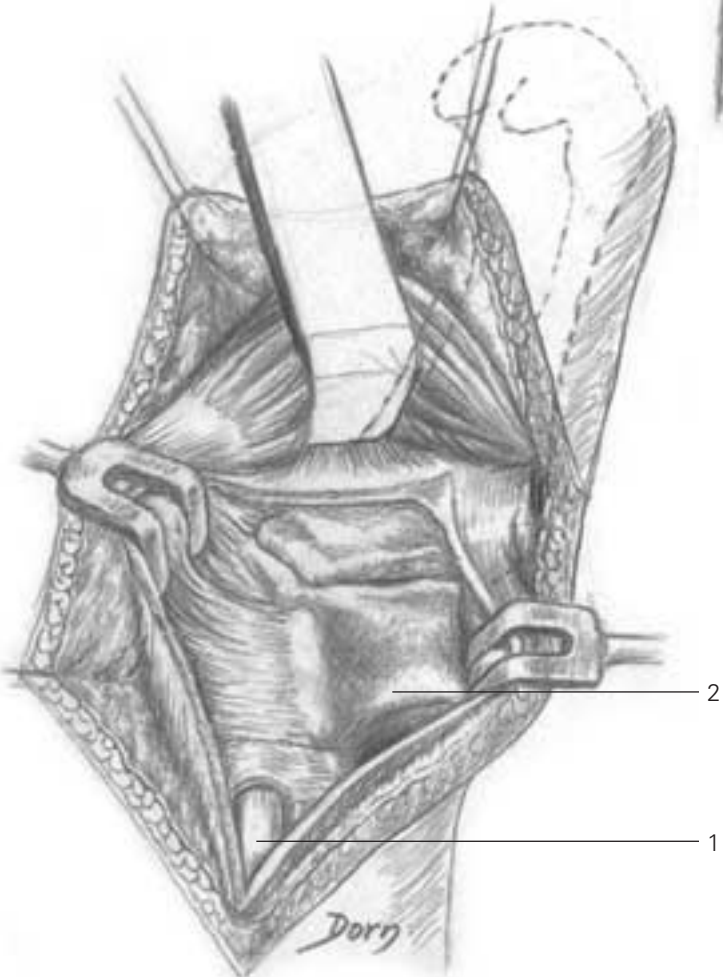
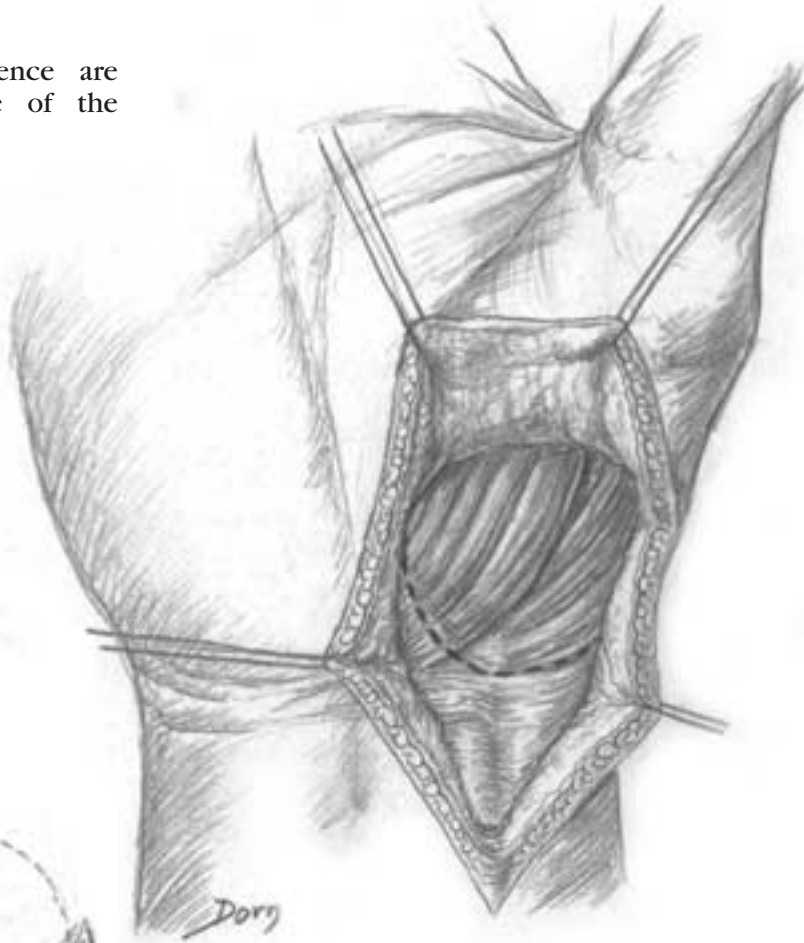
The indications of this procedure are trapeziectomy (for osteoarthritis) and internal fixation of intra-articular fractures.

A Skin incision.



Hand and peripheral nerve surgery

B The muscles of the thenar eminence are reflected from the underlying capsule of the trapeziometacarpal joint.

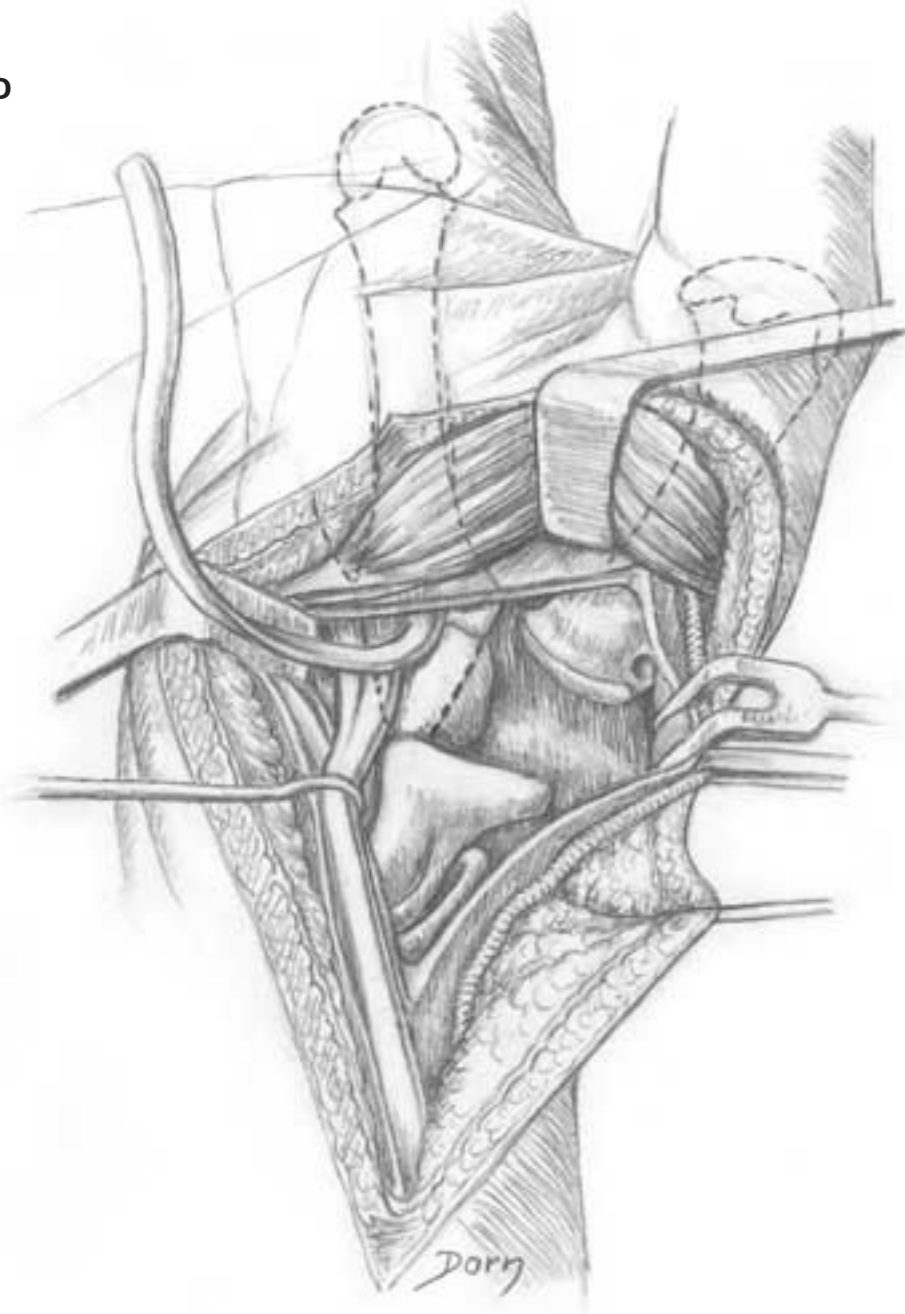


C The capsule is incised, giving access to the trapezium and the base of the first metacarpal.

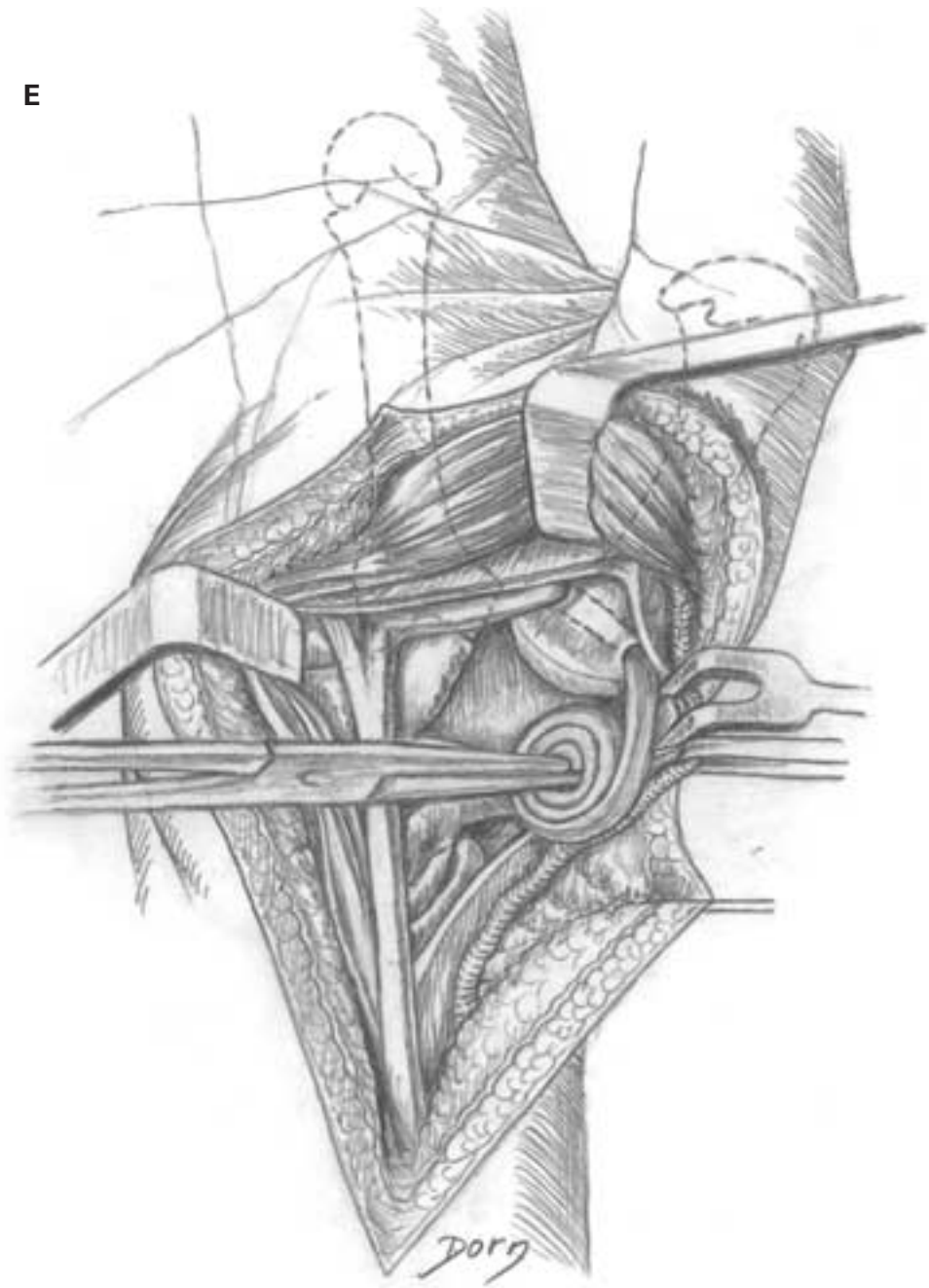
- 1 flexor carpi radialis
- 2 trapezium

D, E The trapezium has been removed. A band of tendon from the flexor carpi radialis is prepared to stabilise the first metacarpal bone and to fill the cavity.

D



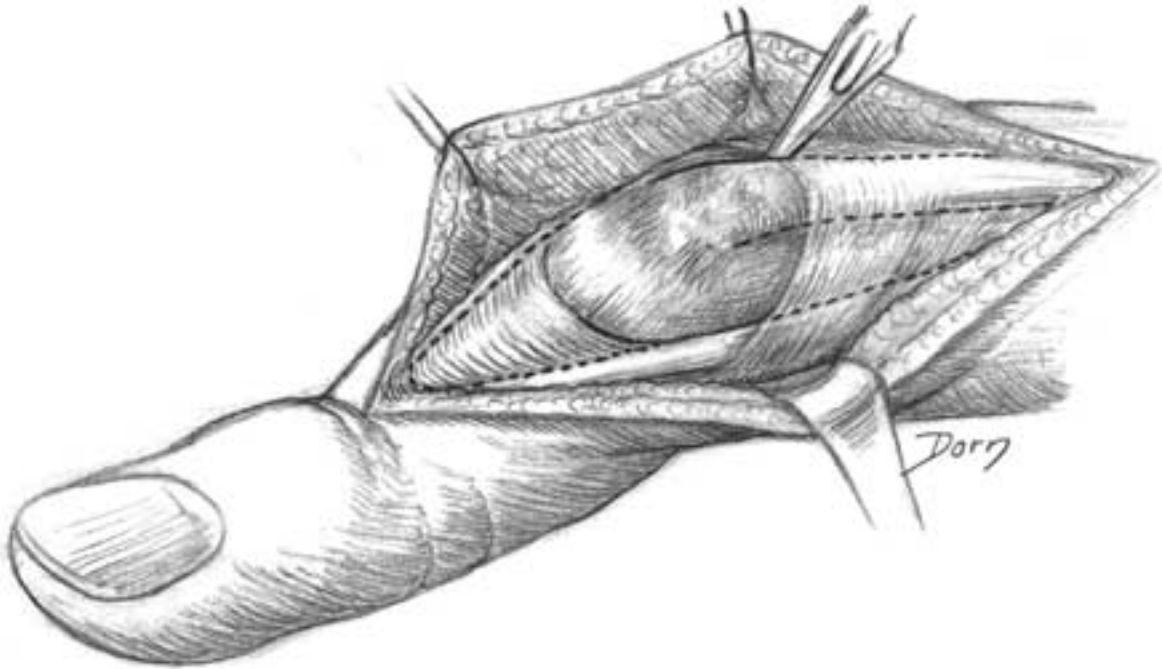
E



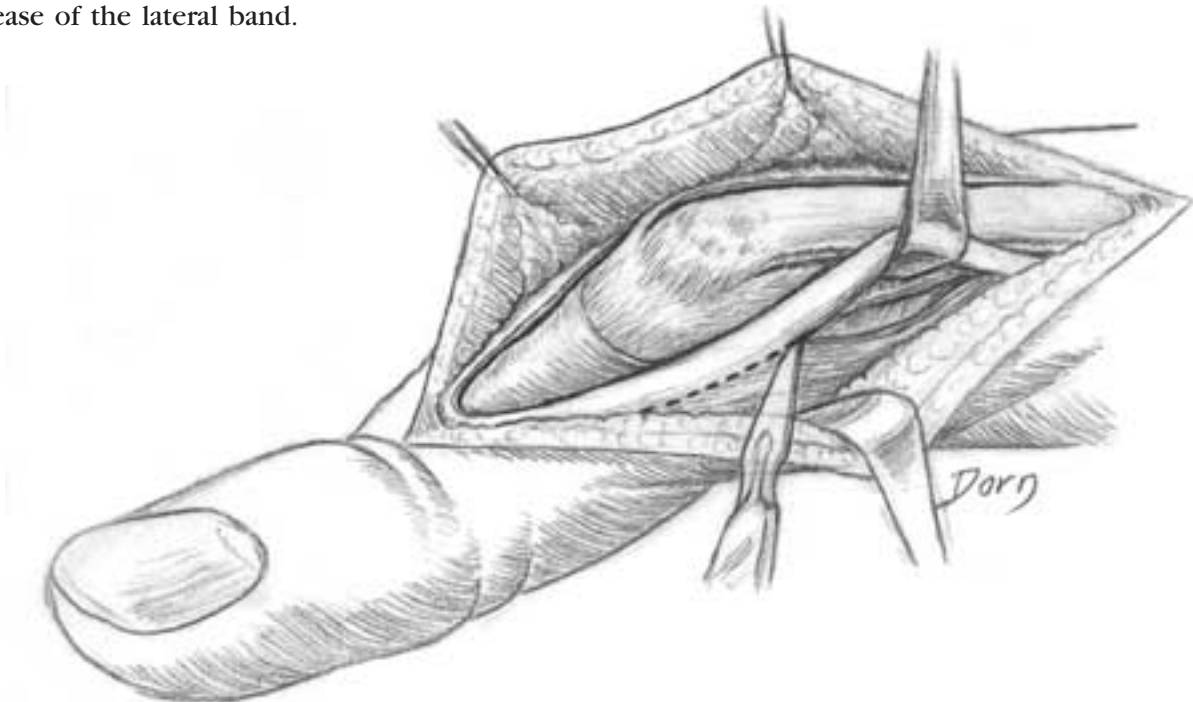
The 'boutonnière' deformity

The 'boutonnière' deformity associates flexion of the PIP joint with hyperextension of the DIP joint. It is caused by the rupture of the central band of the extensor tendon and the luxation of the lateral bands.

A Exposure of the lesions.

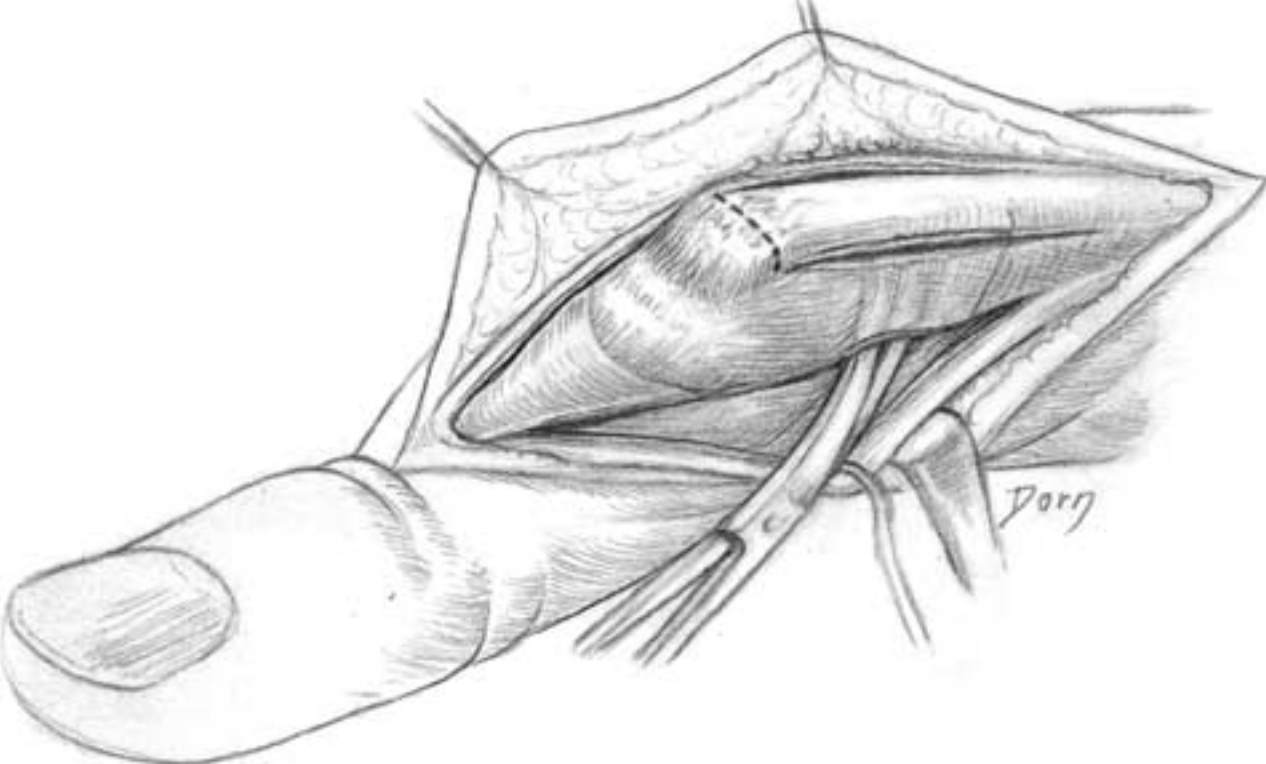


B Release of the lateral band.

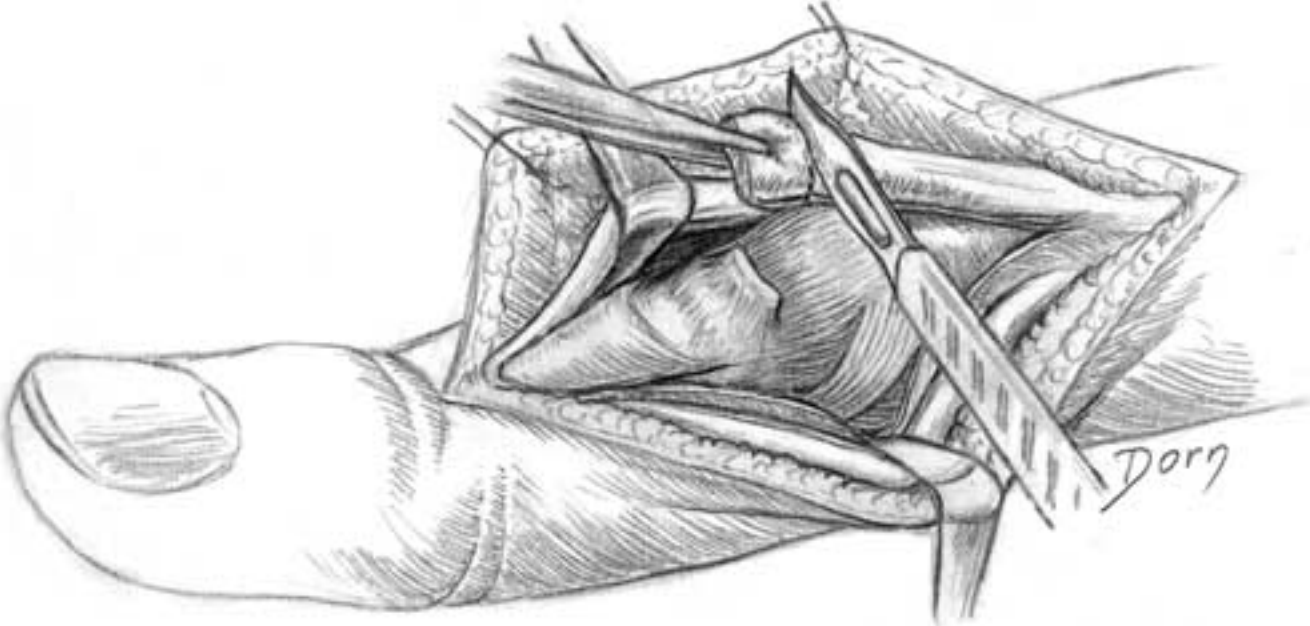


Hand and peripheral nerve surgery

C Release of the central band.

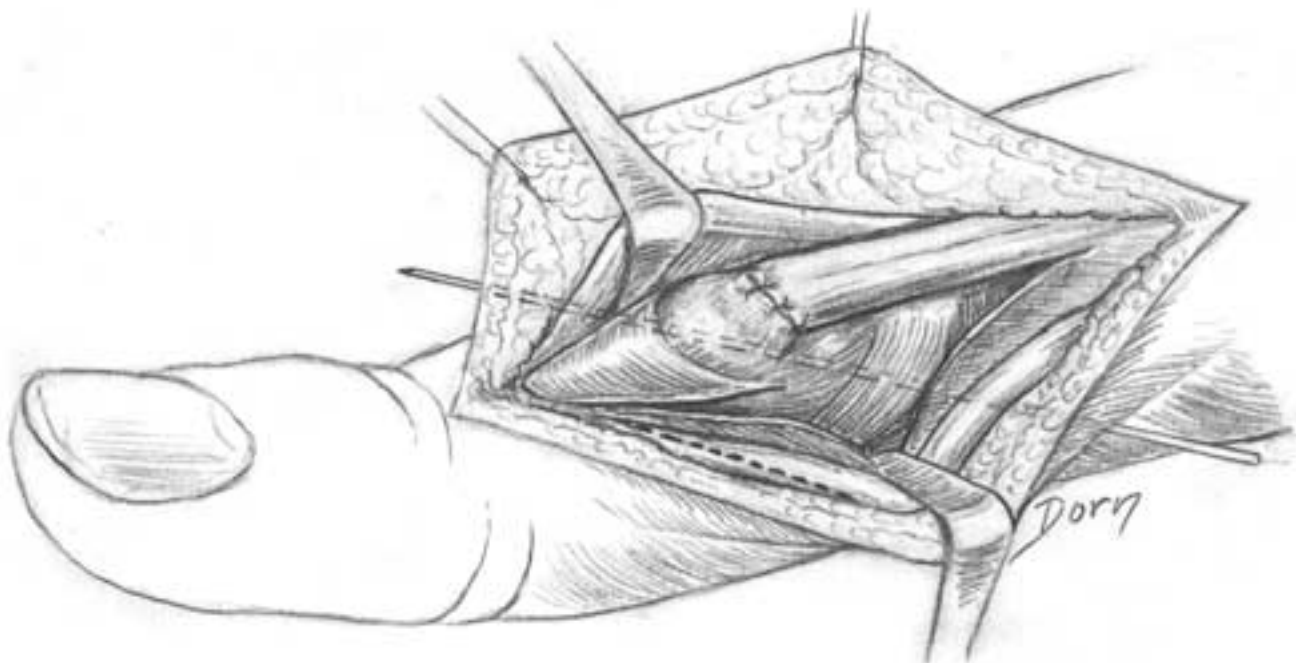


D The fibrous tissue of healing is resected to shorten the central band.

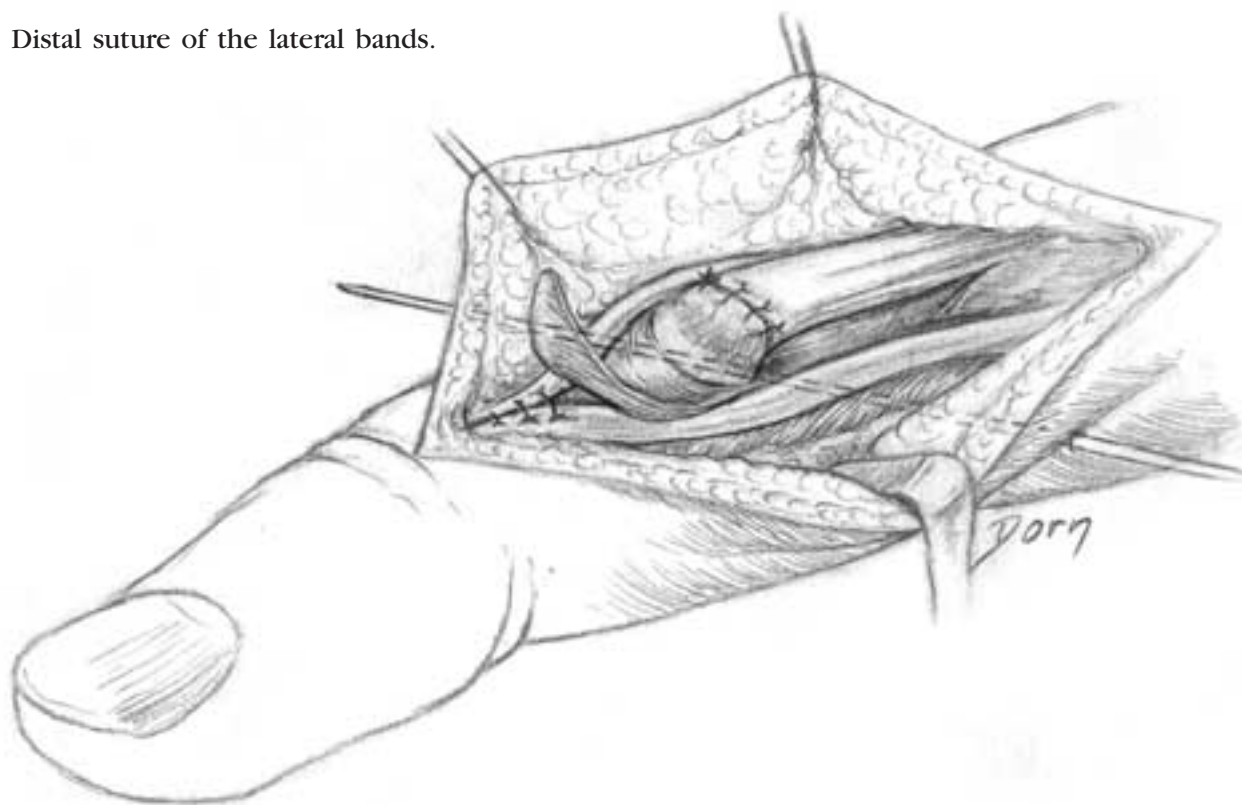


The 'boutonnière' deformity

E The PIP joint is immobilised in extension with a wire. The central band of the tendon is sutured.



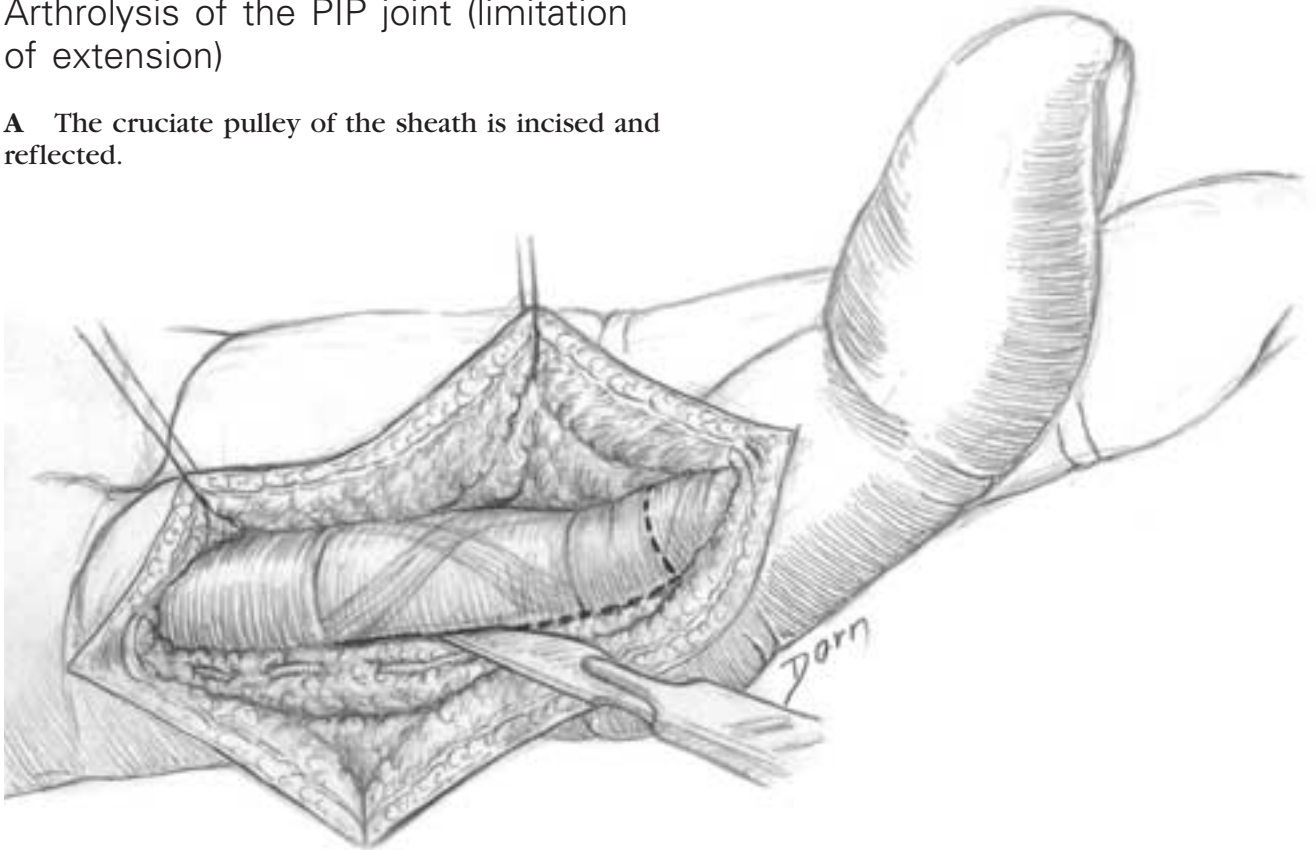
F Distal suture of the lateral bands.



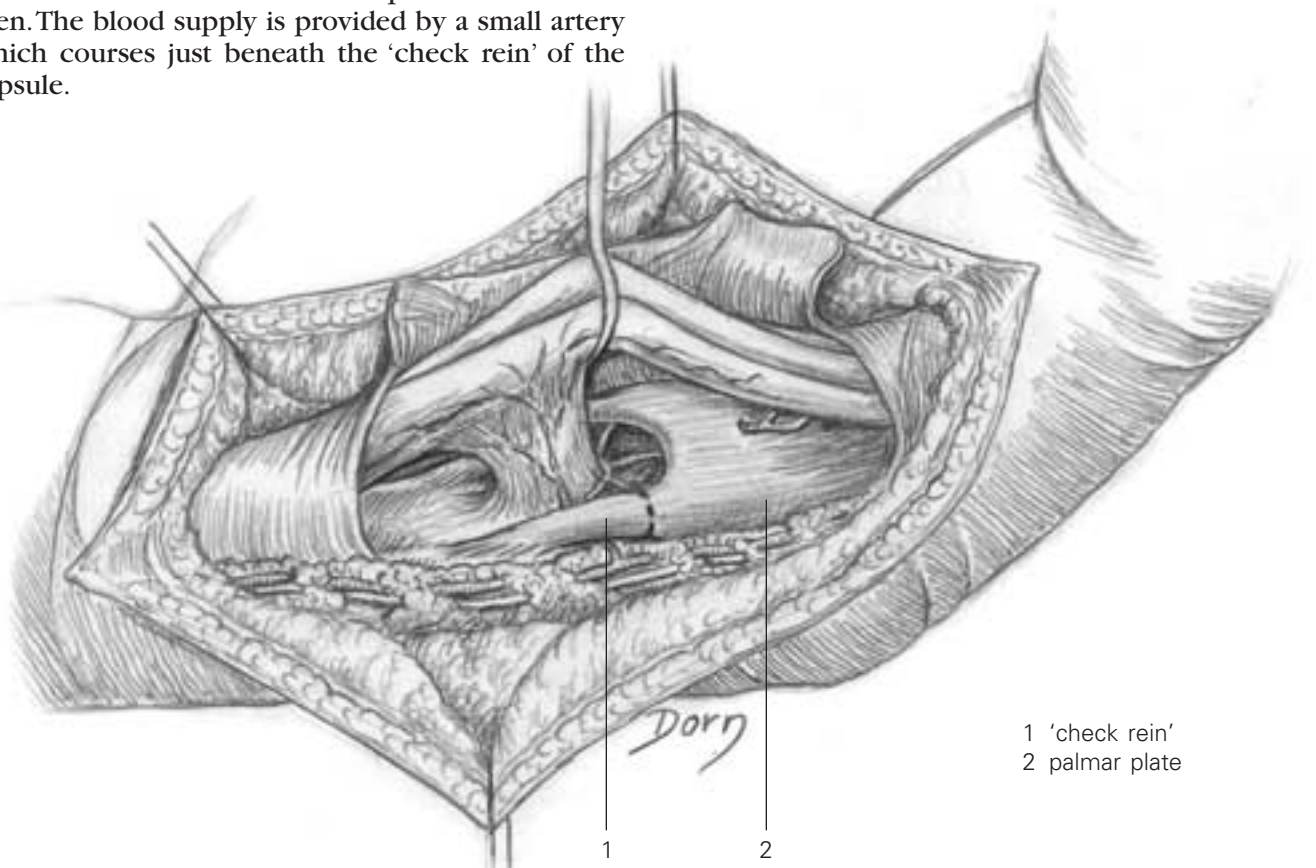
Hand and peripheral nerve surgery

Arthrolysis of the PIP joint (limitation of extension)

A The cruciate pulley of the sheath is incised and reflected.



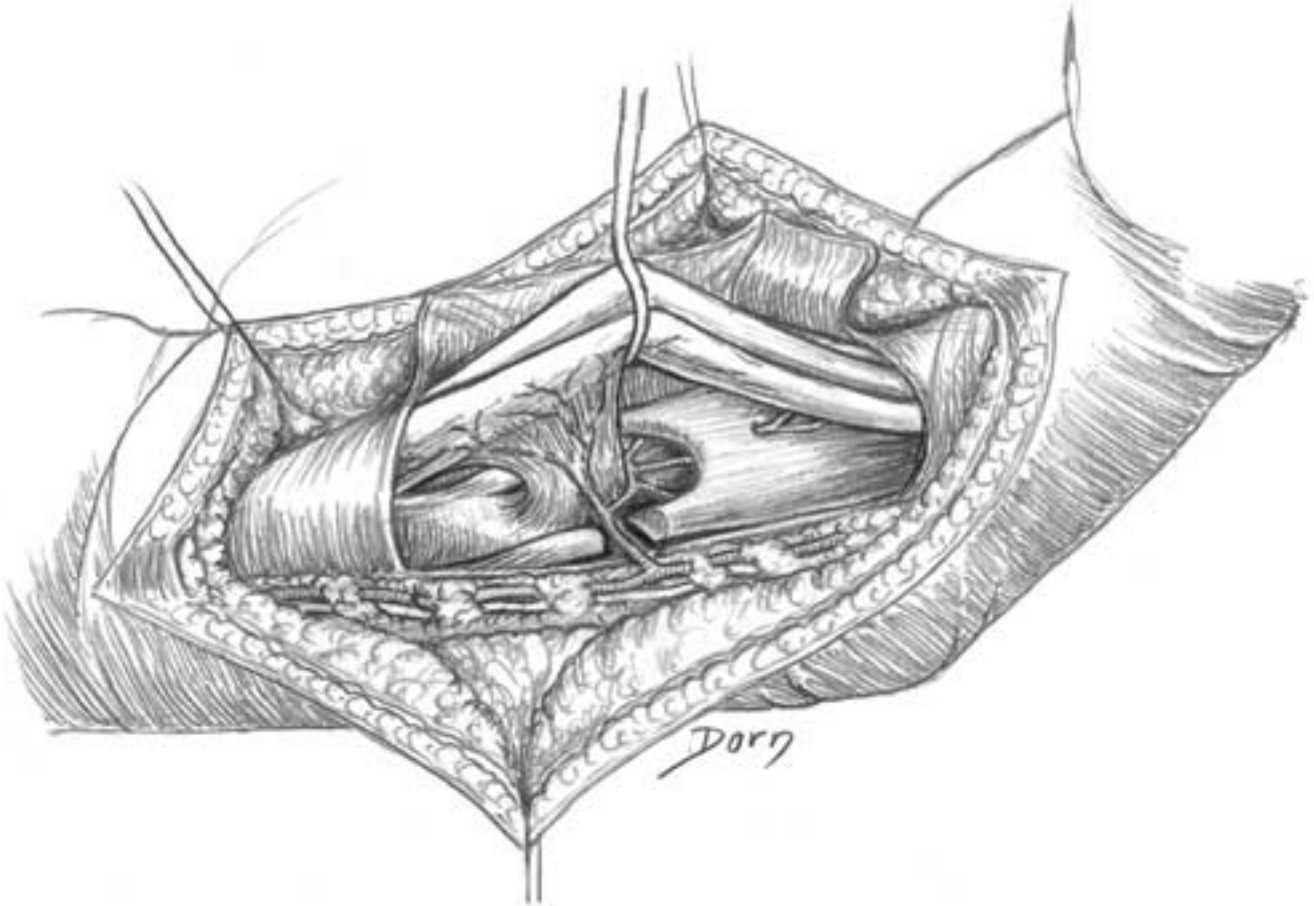
B The vincula of the flexor superficialis are well seen. The blood supply is provided by a small artery which courses just beneath the 'check rein' of the capsule.



- 1 'check rein'
- 2 palmar plate

Arthrolysis of the PIP joint (limitation of extension)

C The check rein is divided, taking care of the small artery. This constitutes the first step of the arthrolysis, and most of the time this is sufficient. If it is not, the capsule is released.

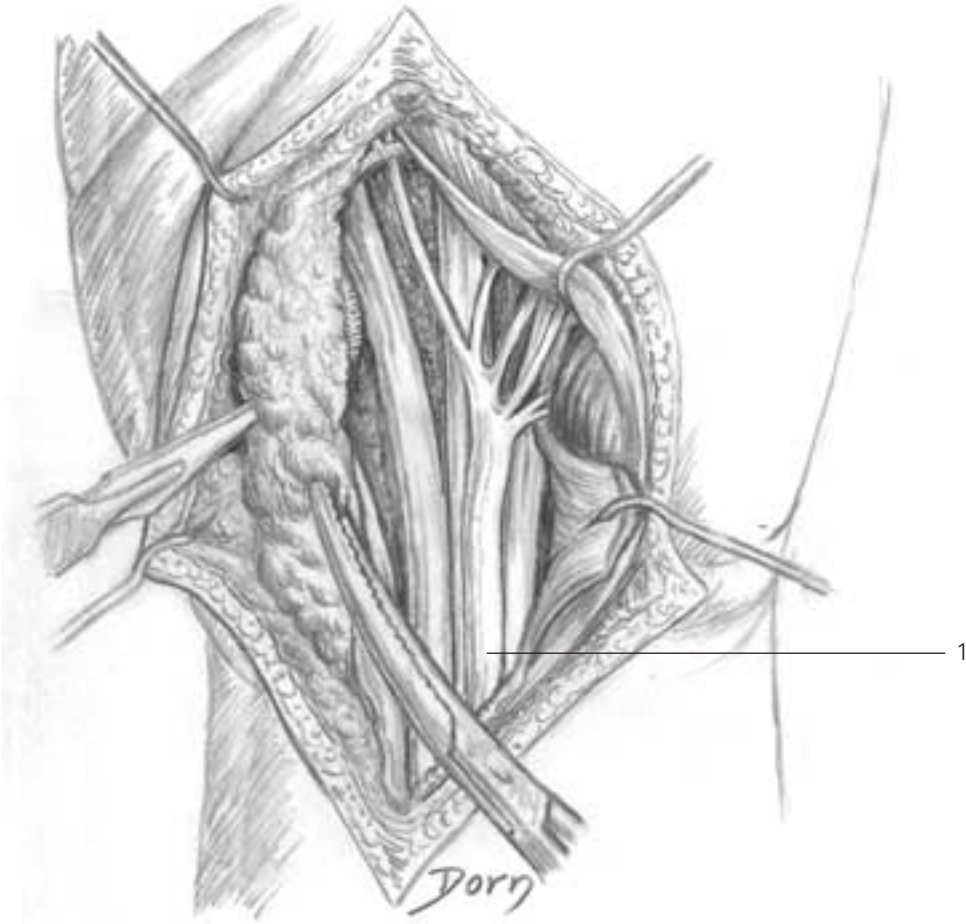


Hand and peripheral nerve surgery

Protective flap for the median nerve at the wrist

This procedure is indicated in iterative release of the median nerve in carpal tunnel syndrome.

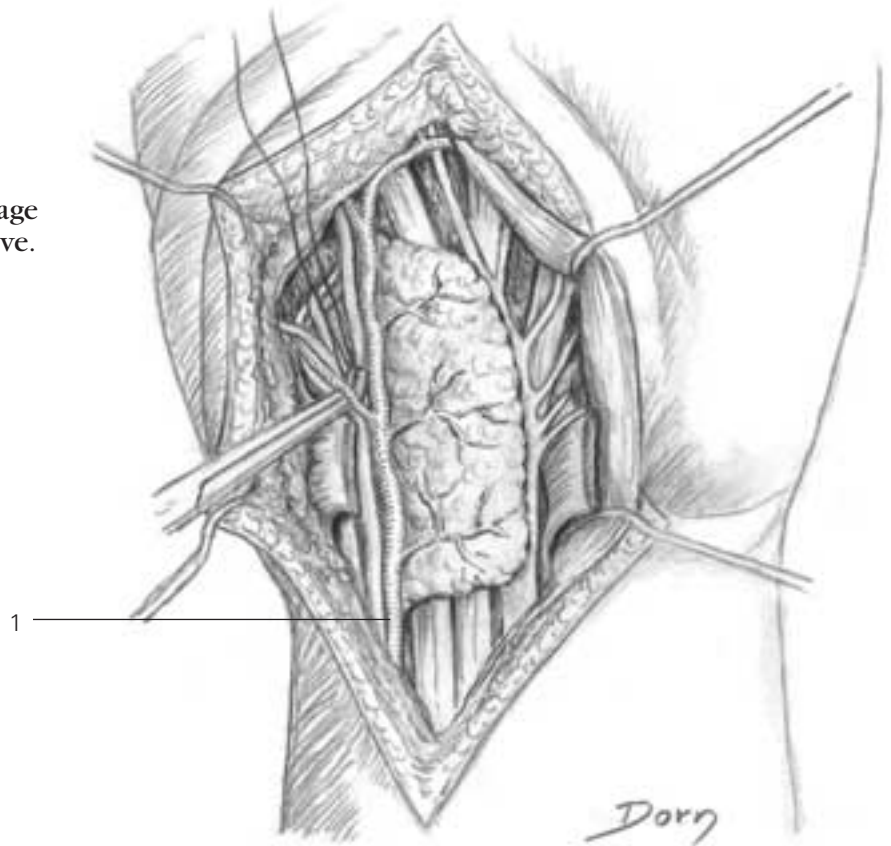
A The fat pad of Guyon's compartment is mobilised. It is supplied by the ulnar artery.



1 median nerve

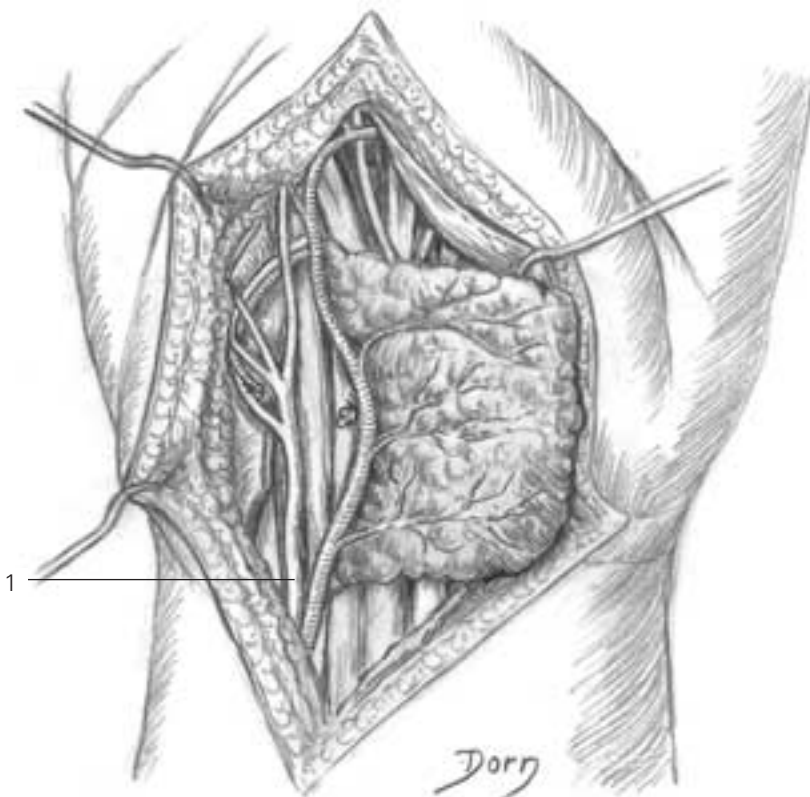
Protective flap for the median nerve at the wrist

B The fat flap is turned like a page of a book to cover the median nerve.



1 ulnar artery

C If necessary, the ulnar vessels are mobilised to increase the arc of rotation of the flap.



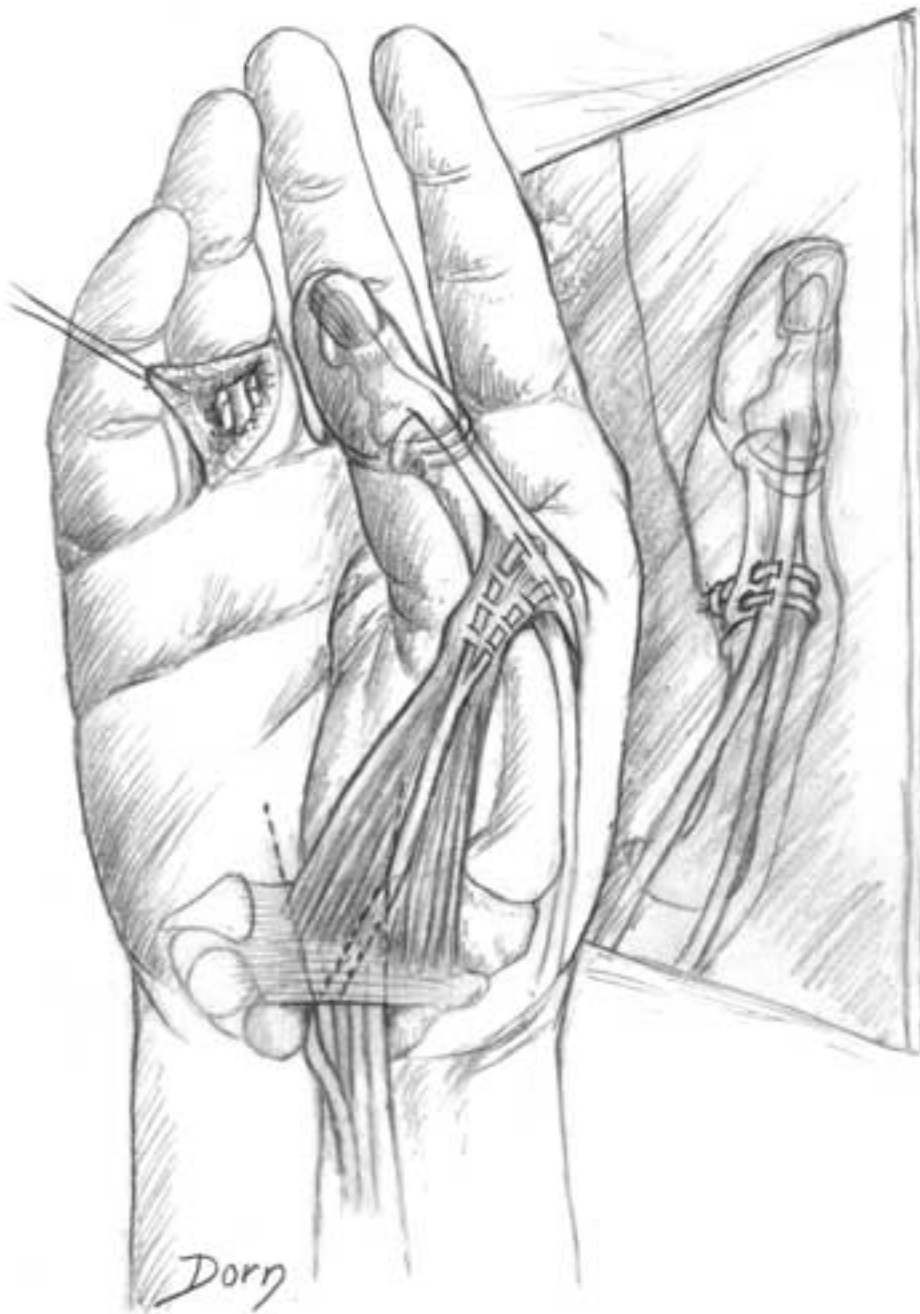
1 ulnar nerve

Hand and peripheral nerve surgery

Flexor digitorum superficialis transfer to the thumb

This procedure allows, in a single drawing, to see the opposite side of the base of the thumb. Therefore, we can see the fixation of the tendon transfer on the ulnar side of the thumb.

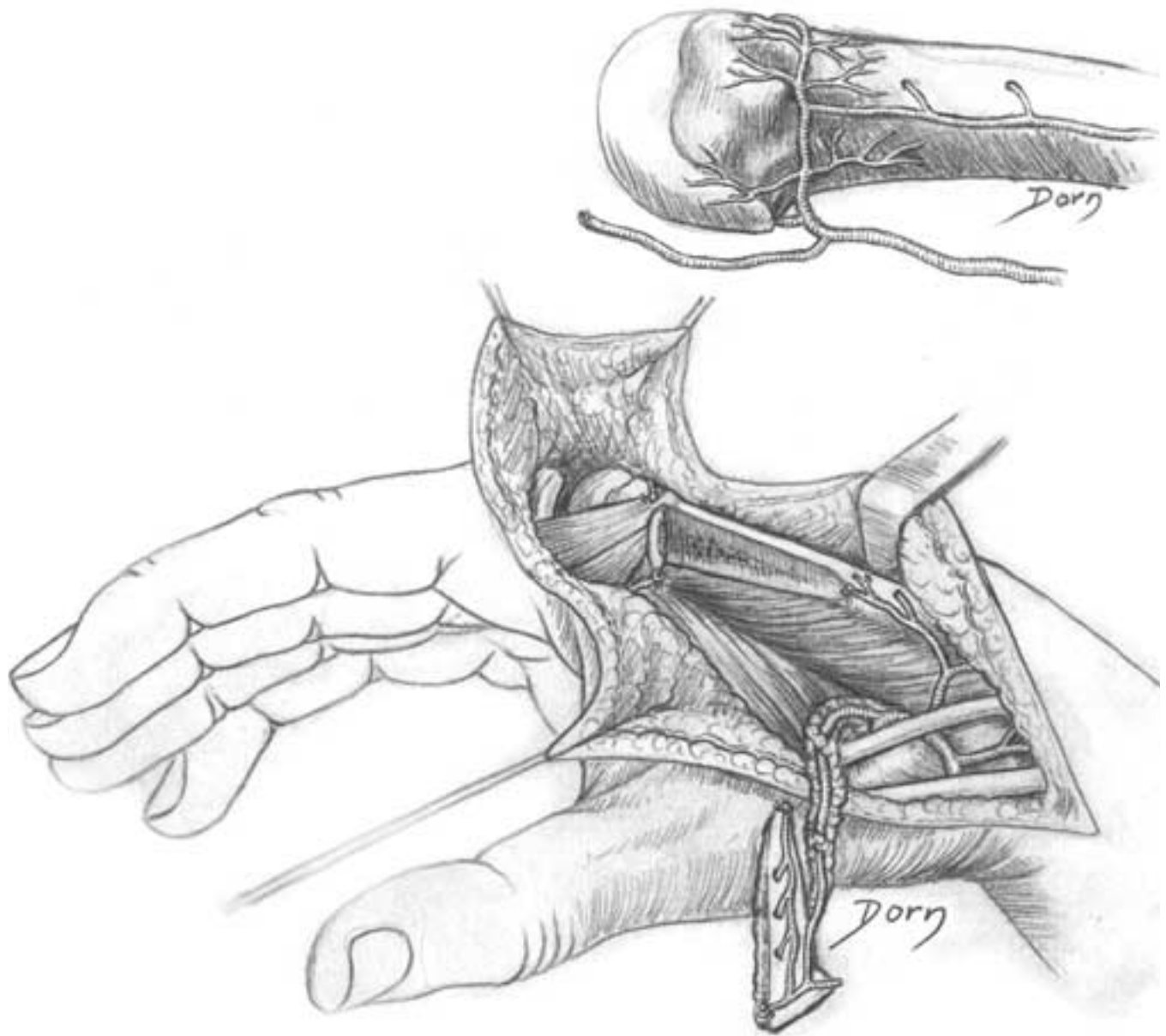
Paralysis of all intrinsic muscles of the thumb. FDS transfer to the thumb. The best site for the pulley is at the proximal pole of the pisiform. The simplest procedure consists of passing the transfer around the tendon of the FCU. However, if this muscle is paralysed, its tendon stretches and the direction of the transfer will not be maintained. In this event it is advisable to perform a tenodesis of the paralysed FCU tendon to the ulna proximal to the pulley.



Vascularised bone transfer from the second metacarpal

Vascularised bone transfer from the metaphysis of the second metacarpal

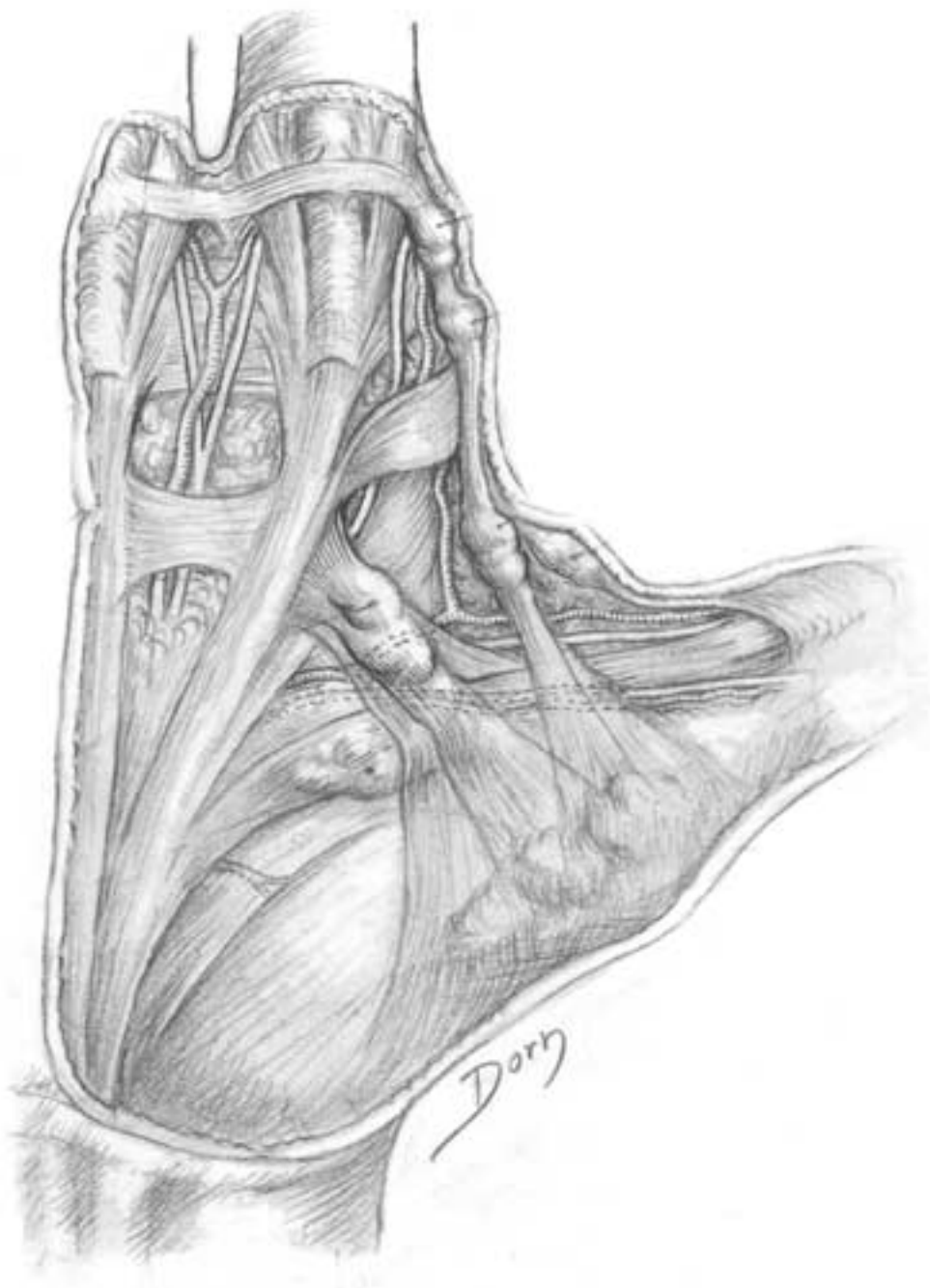
The bone block is pedicled on the first dorsal interosseous artery. This transfer can be used for atrophic non-union of the scaphoid.



Dupuytren's disease

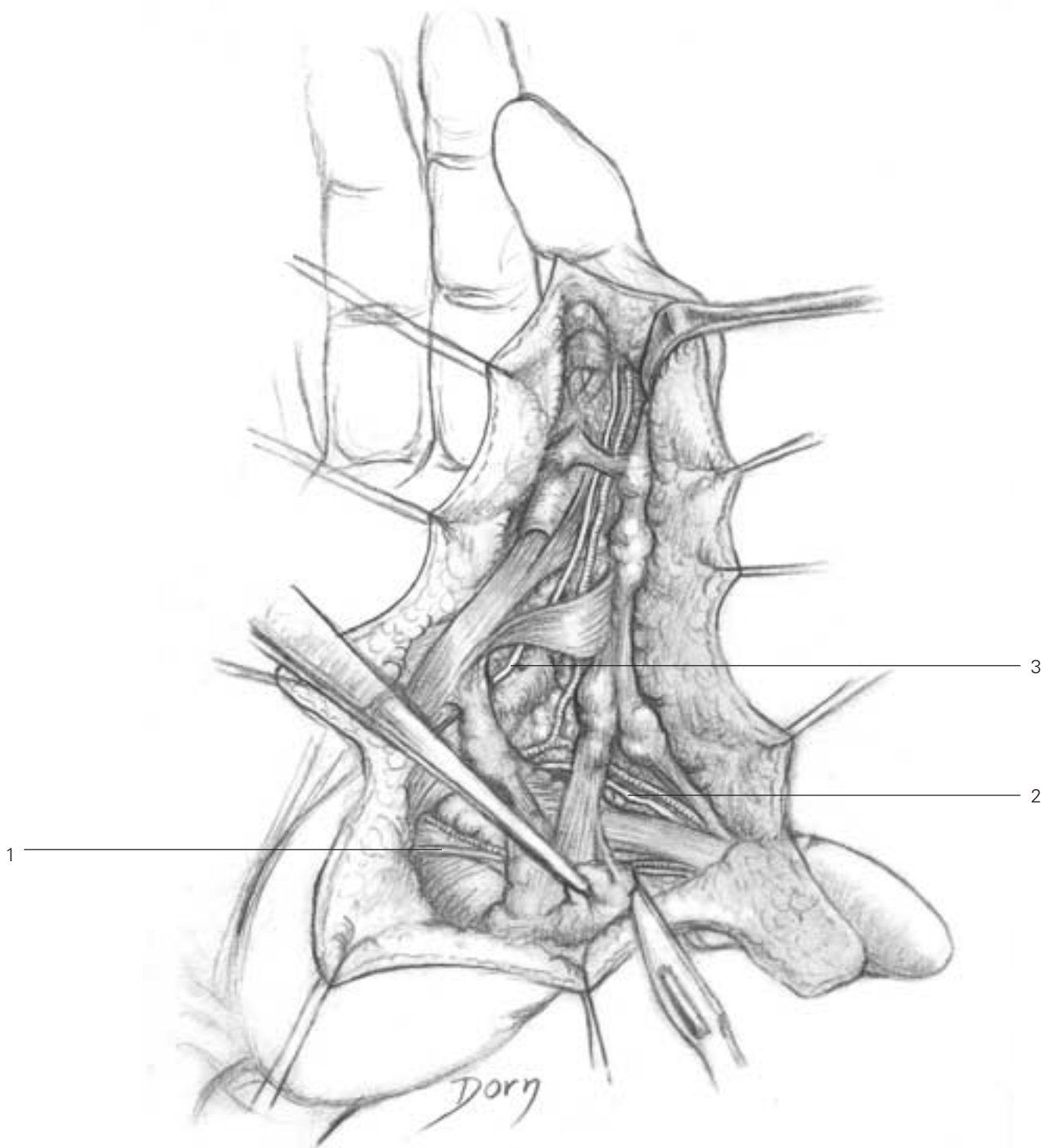
This series of illustrations is probably one of the most beautiful of all of Léon Dorn's drawings. The amount of work needed for representing the lesions is impressive. The drawings are based on the vast experience of Raoul Tubiana, and the fibrous bands are not a product of imagination.

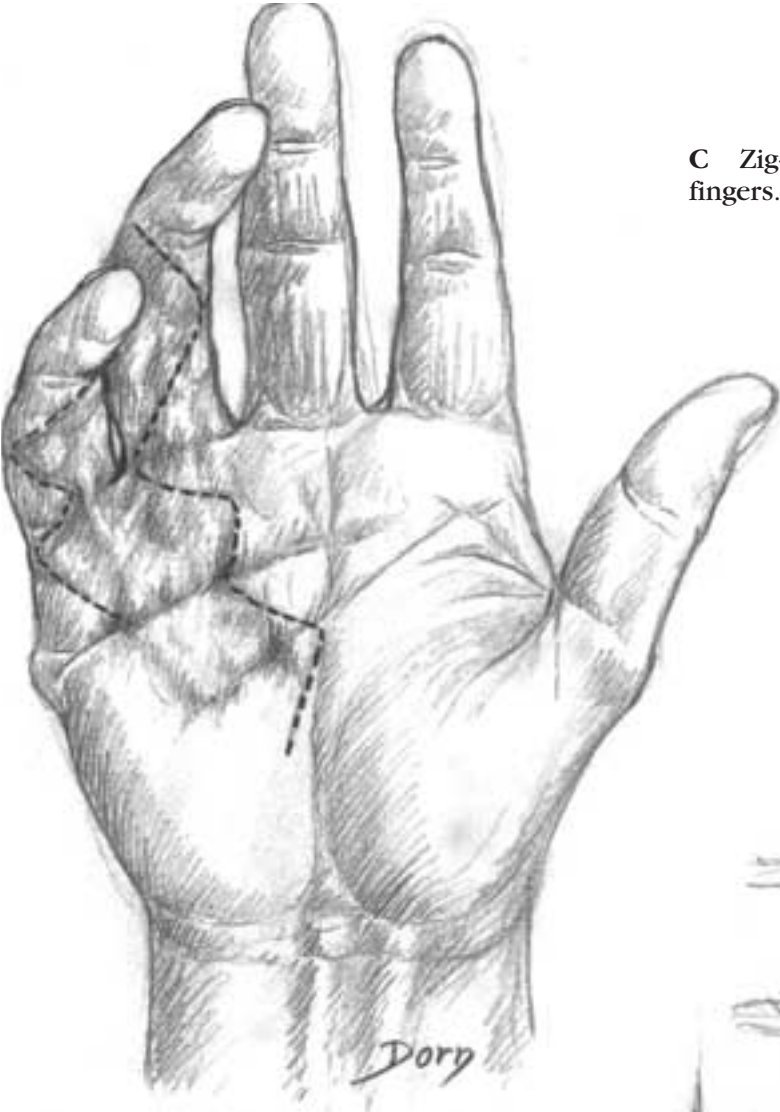
A Radial side lesions.



B At the digitopalmar junction and in the finger, pathological tissue is often very thick. It is necessary to identify the arteries and nerves at the level of the finger.

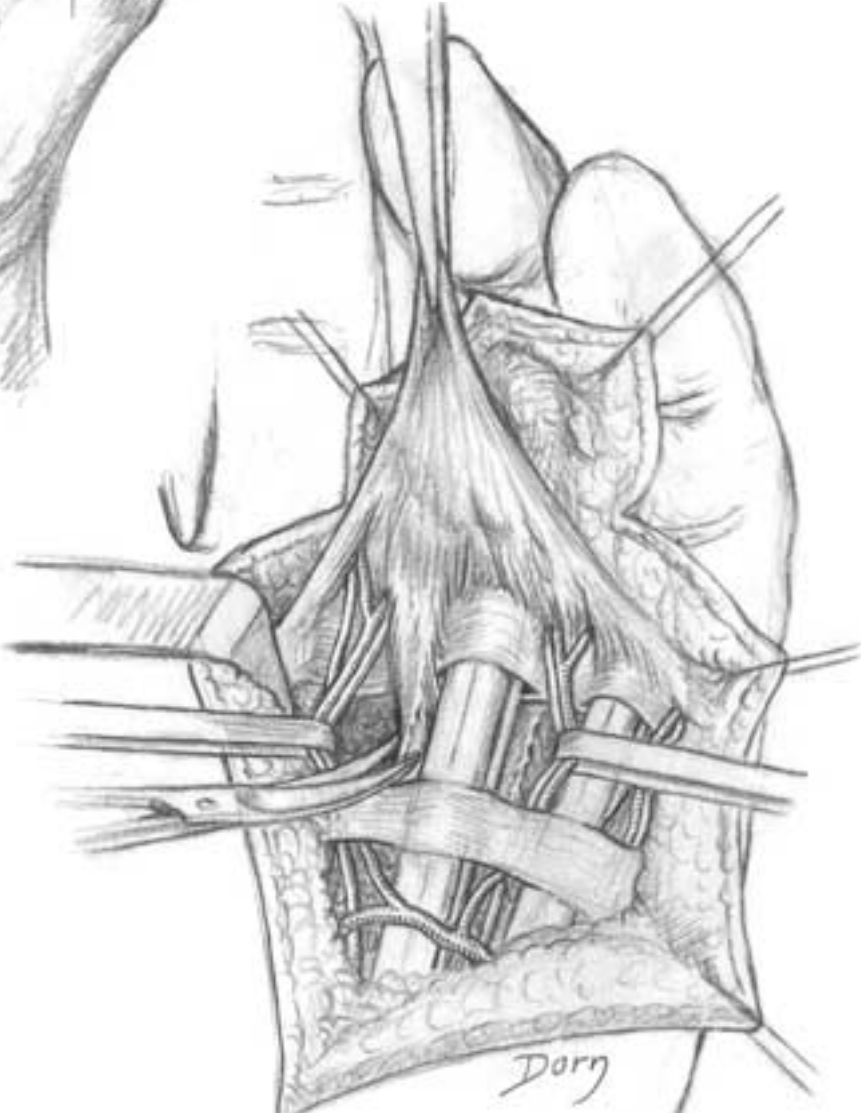
- 1 radial collateral nerve of the thumb
- 2 ulnar vascular bundle of the thumb
- 3 radial collateral nerve of the index finger



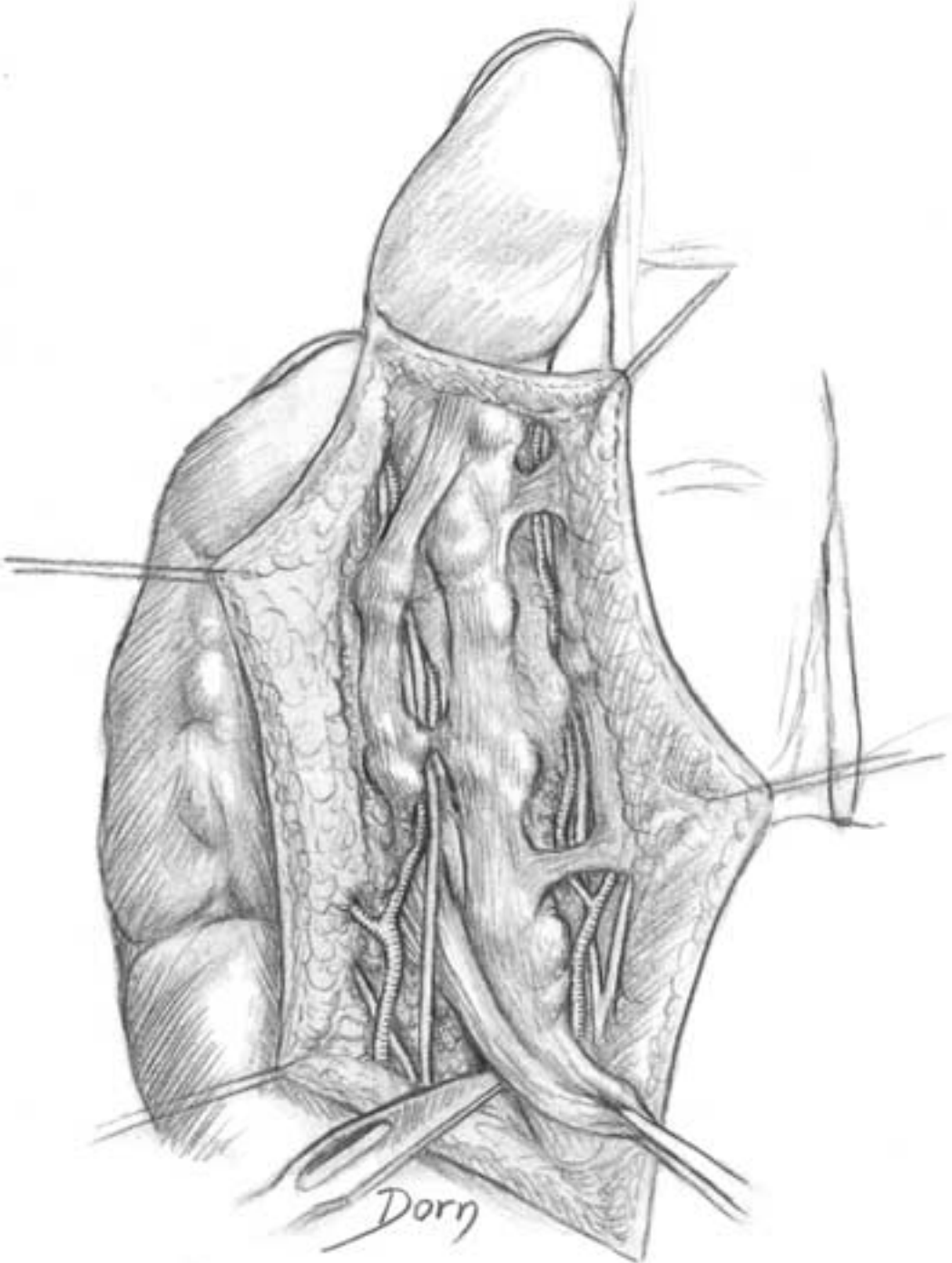


C Zig-zag digitopalmar incisions on two adjacent fingers.

D At the digitopalmar junction and in the finger, pathological tissue is often very thick. It is necessary to identify the arteries and nerves at the level of the finger.



E Division of the vertical septae.

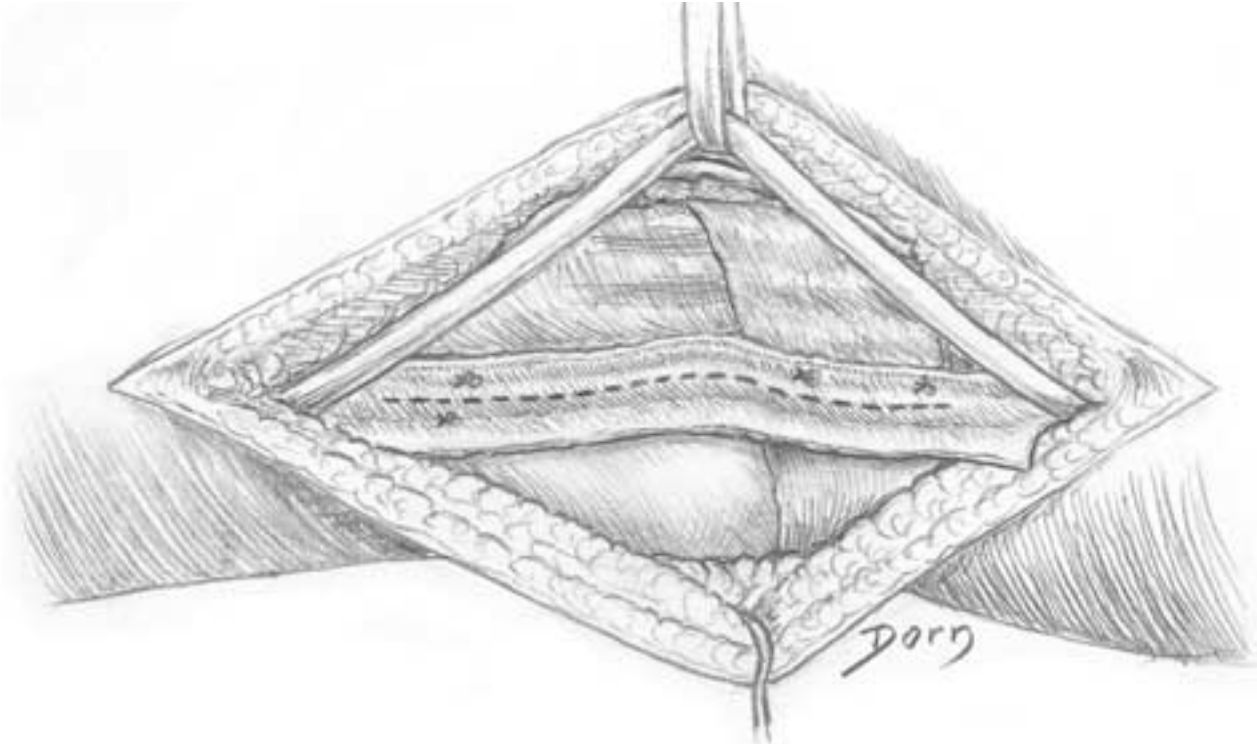


Hand and peripheral nerve surgery

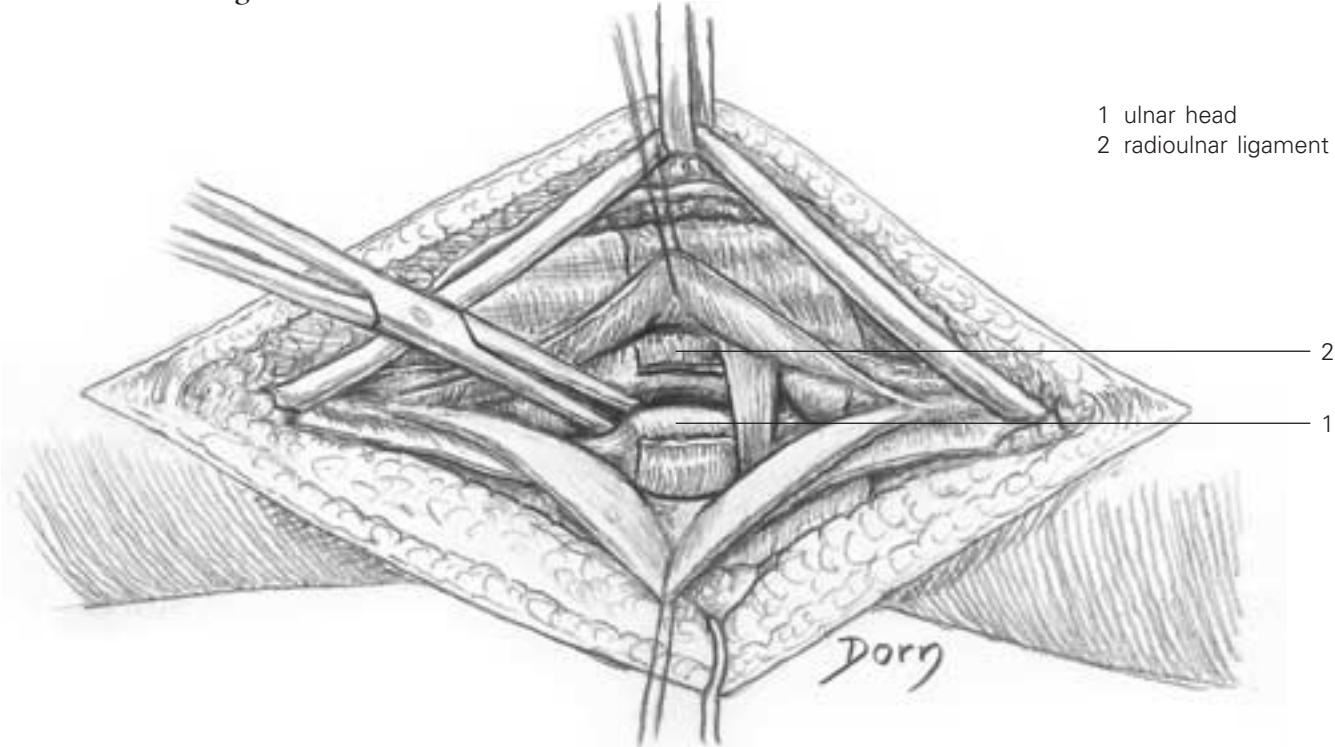
Surgery of the wrist

Approach to the distal radioulnar joint.

A The fifth compartment of extensor tendons has been opened. The tendon of extensor digit minimi is retracted and the floor of the sheath is incised.



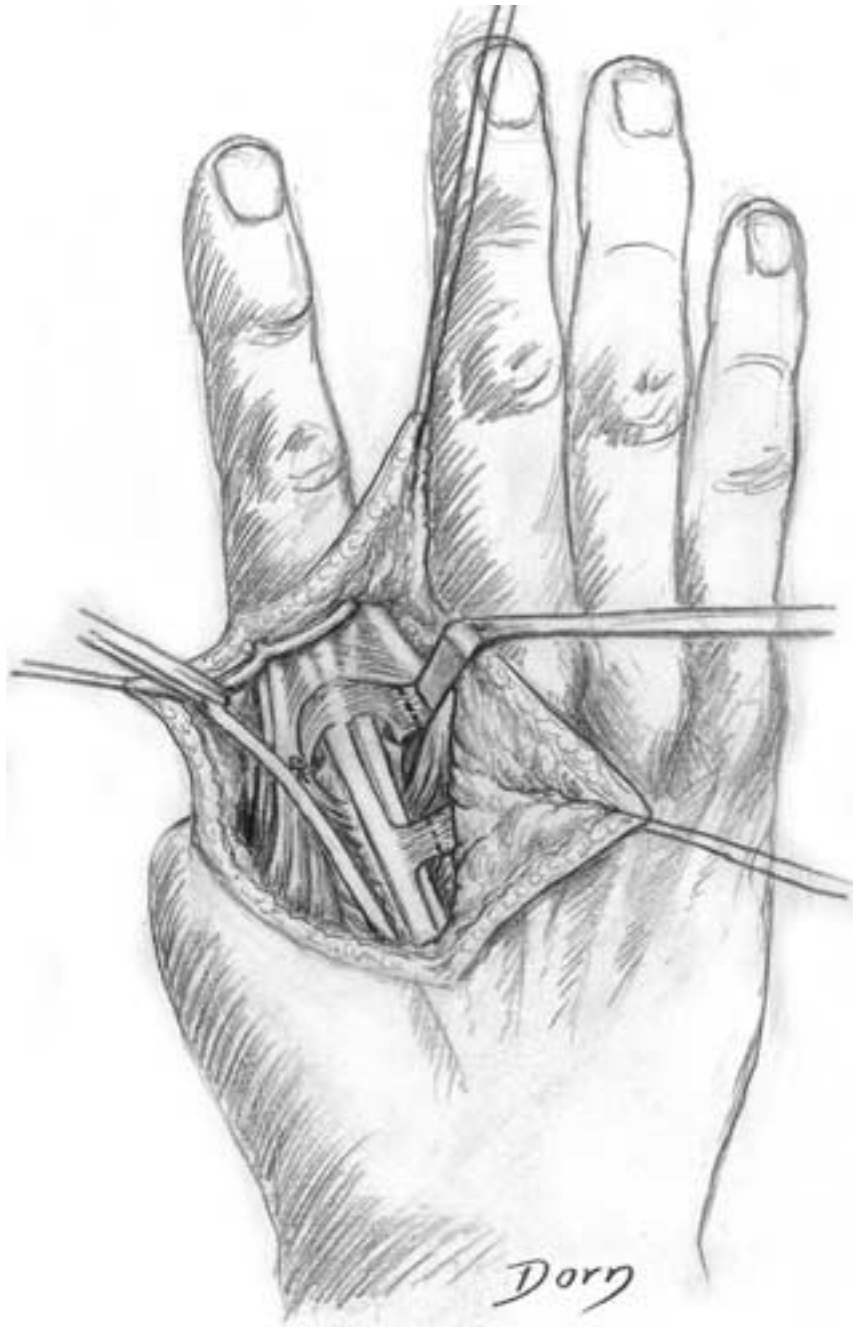
B The joint is exposed. Note rupture of the posterior radioulnar ligament.



Pollicisation of the index finger

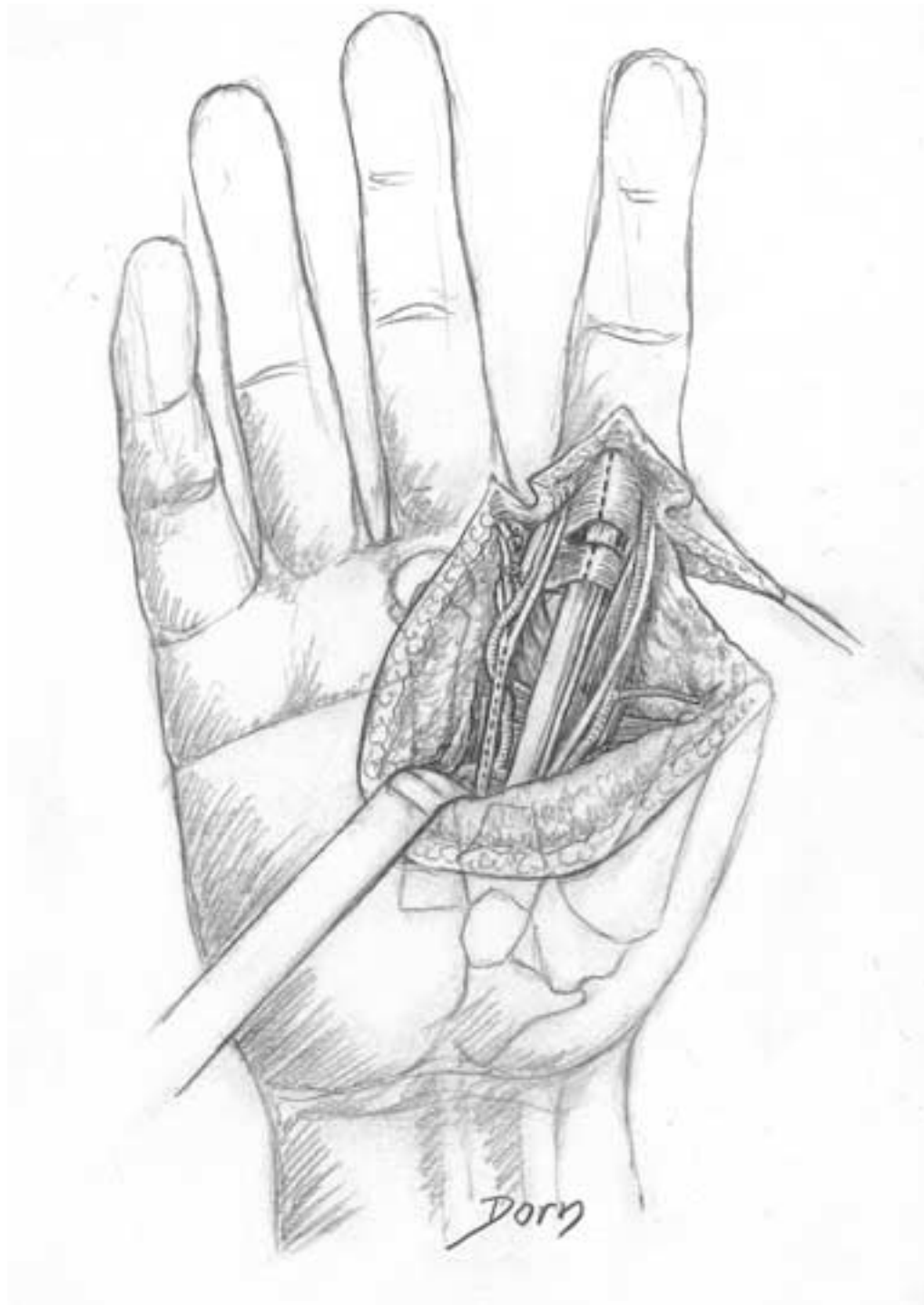
The procedure of pollicisation consists of transferring a finger to replace a missing thumb. It is one of the most difficult techniques in surgery of the hand. The skin incision should be precisely designed, dissection must be accurate and cautious and the result should be assessed cosmetically and functionally. The series of drawings shows pollicisation of the index finger, which is the most frequently performed.

A Dissection of the dorsal aspect, skin flaps being reflected.



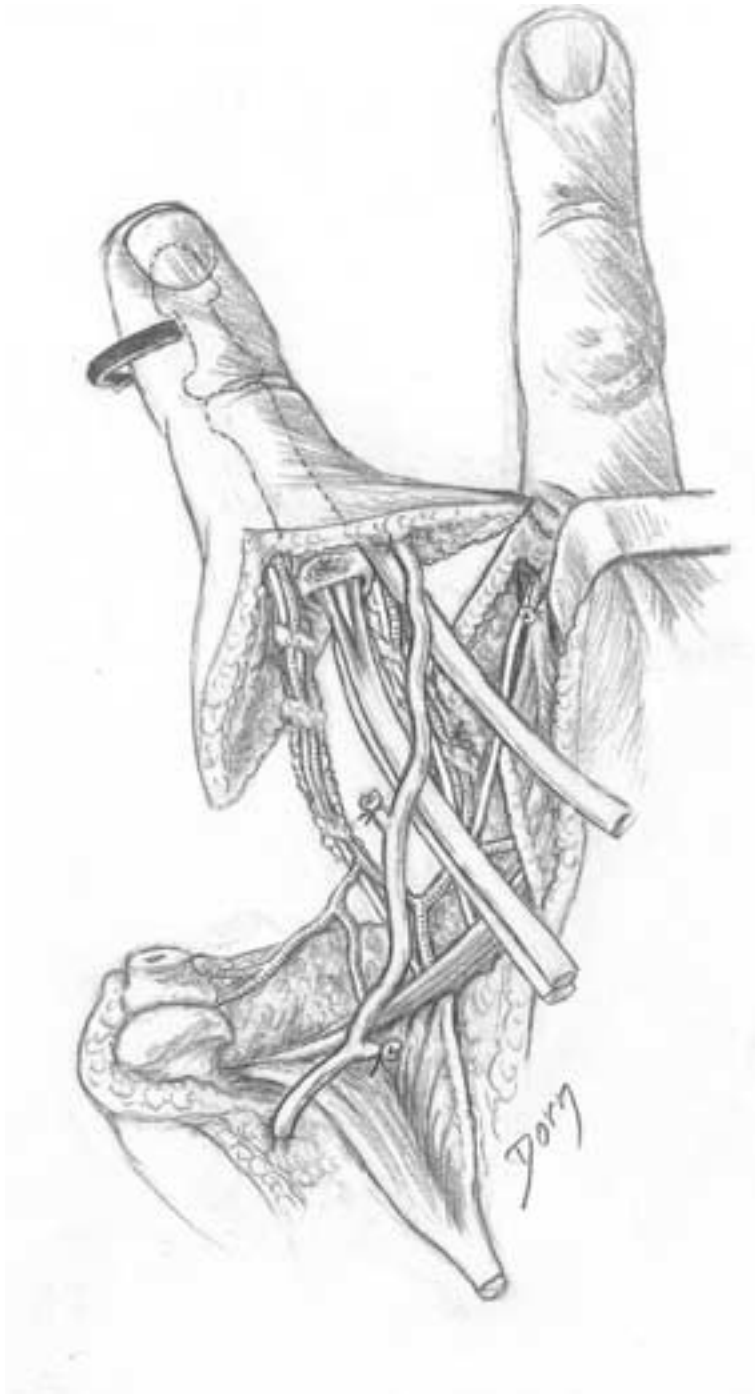
Hand and peripheral nerve surgery

B Dissection of the palmar structures. Care should be taken to spare the neurovascular pedicles. Note that the common digital nerve should be split (by intraneural dissection) to allow the mobilisation of the finger.



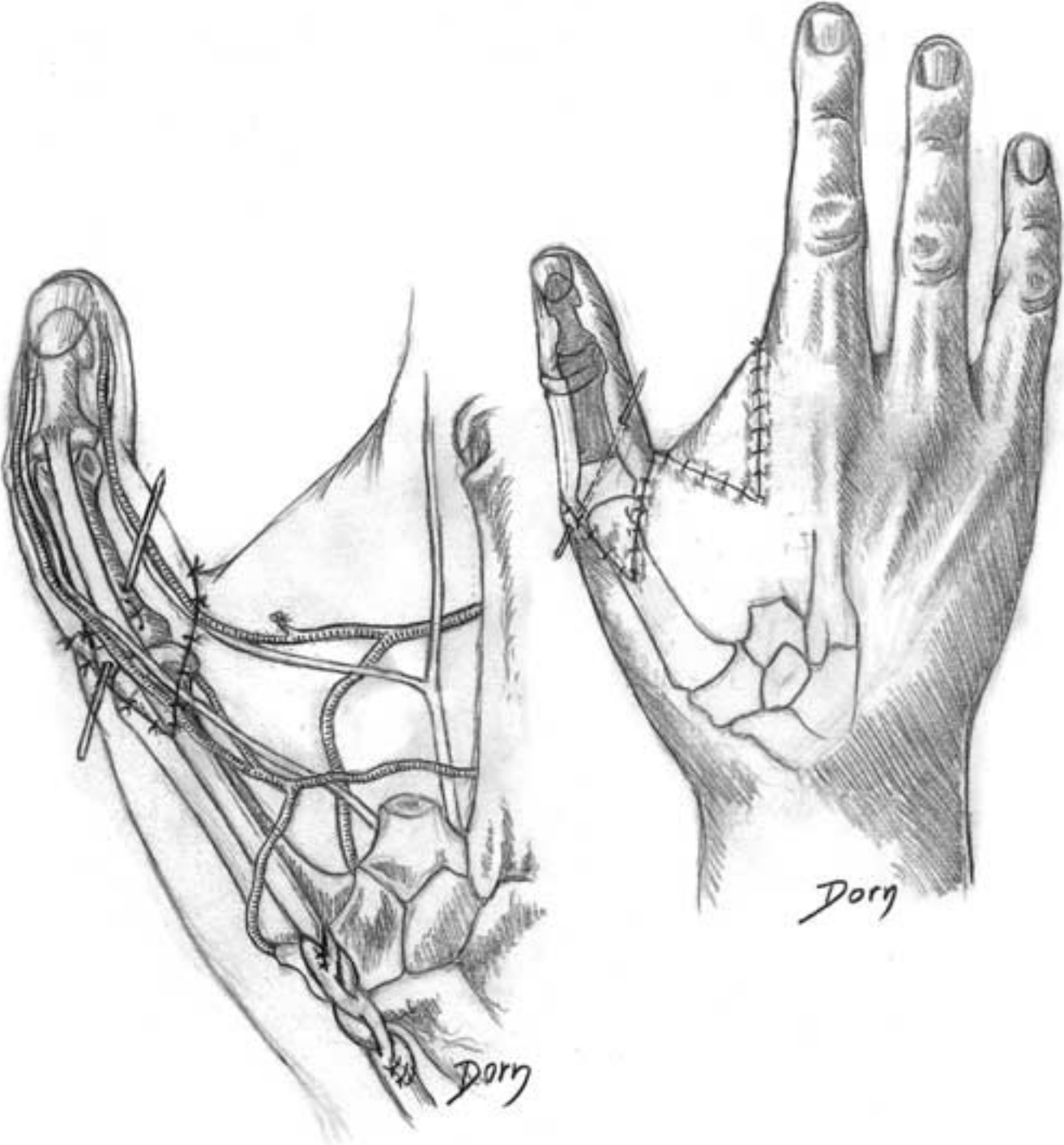
Pollicisation of the index finger

C The finger remains pedicled only on its neurovascular bundles: palmar pedicles and dorsal vein. The tendons are severed to be sutured on the recipient site. The index finger should be rotated without twisting the pedicles. Note that the first phalanx has been removed.



Hand and peripheral nerve surgery

D Fixation of bone and sutures of the tendons. The second metacarpal has been excised to increase the width of the first web.

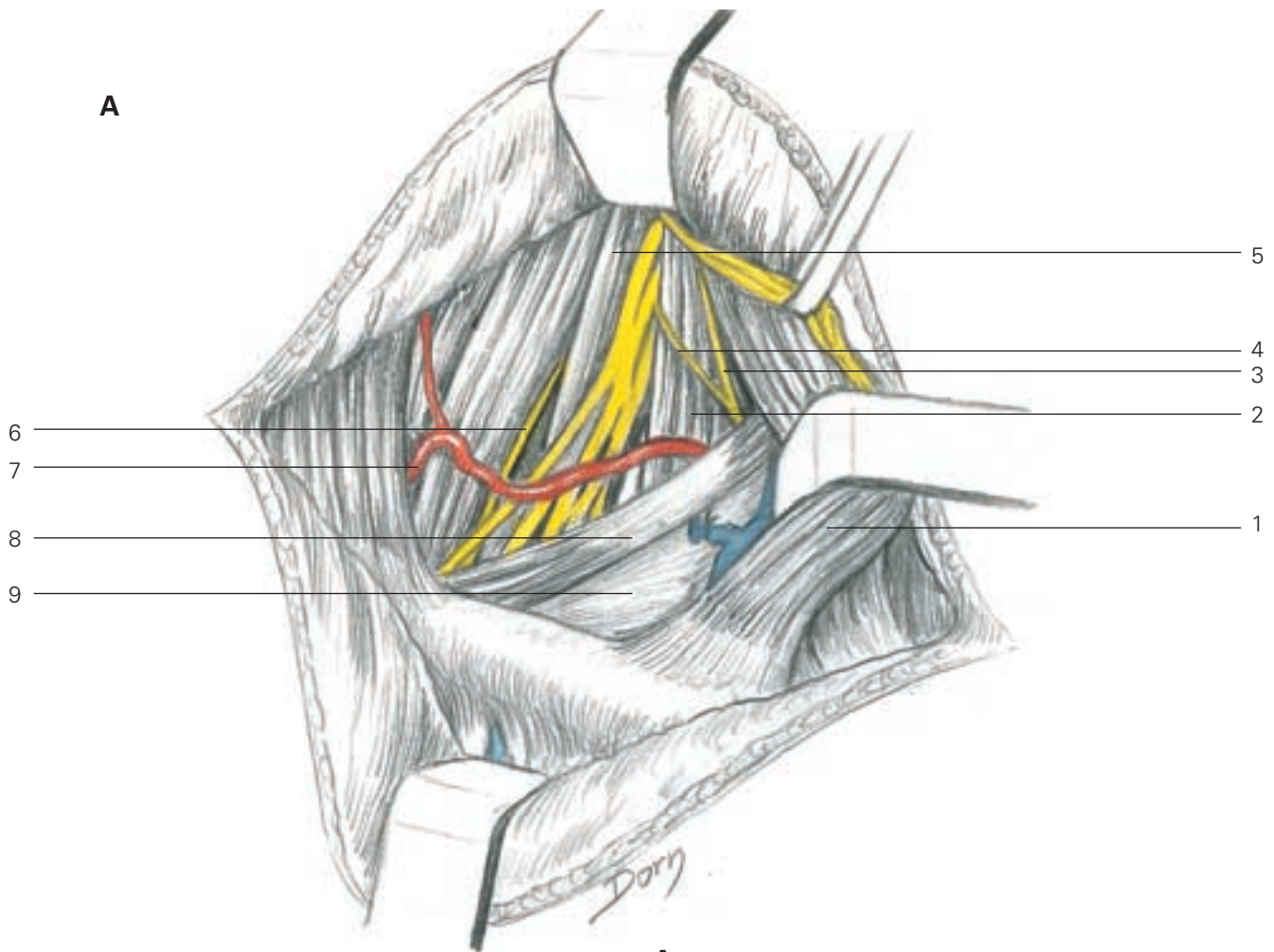


Surgery of the peripheral nerves

Nerve surgery is particularly important in the upper limb, as the ultimate purpose of the upper extremity is the function of the hand. Tunnel syndromes are frequent (median nerve at the wrist, ulnar nerve at the elbow, etc) and cause pain and disability. Traumatic lesions require exploration and repair either by direct suturing or by nerve grafts. One of the most dramatic lesions is the partial or total paralysis of the brachial plexus as a result of trauma. The first figure shows the exposure of the brachial plexus.

Brachial plexus

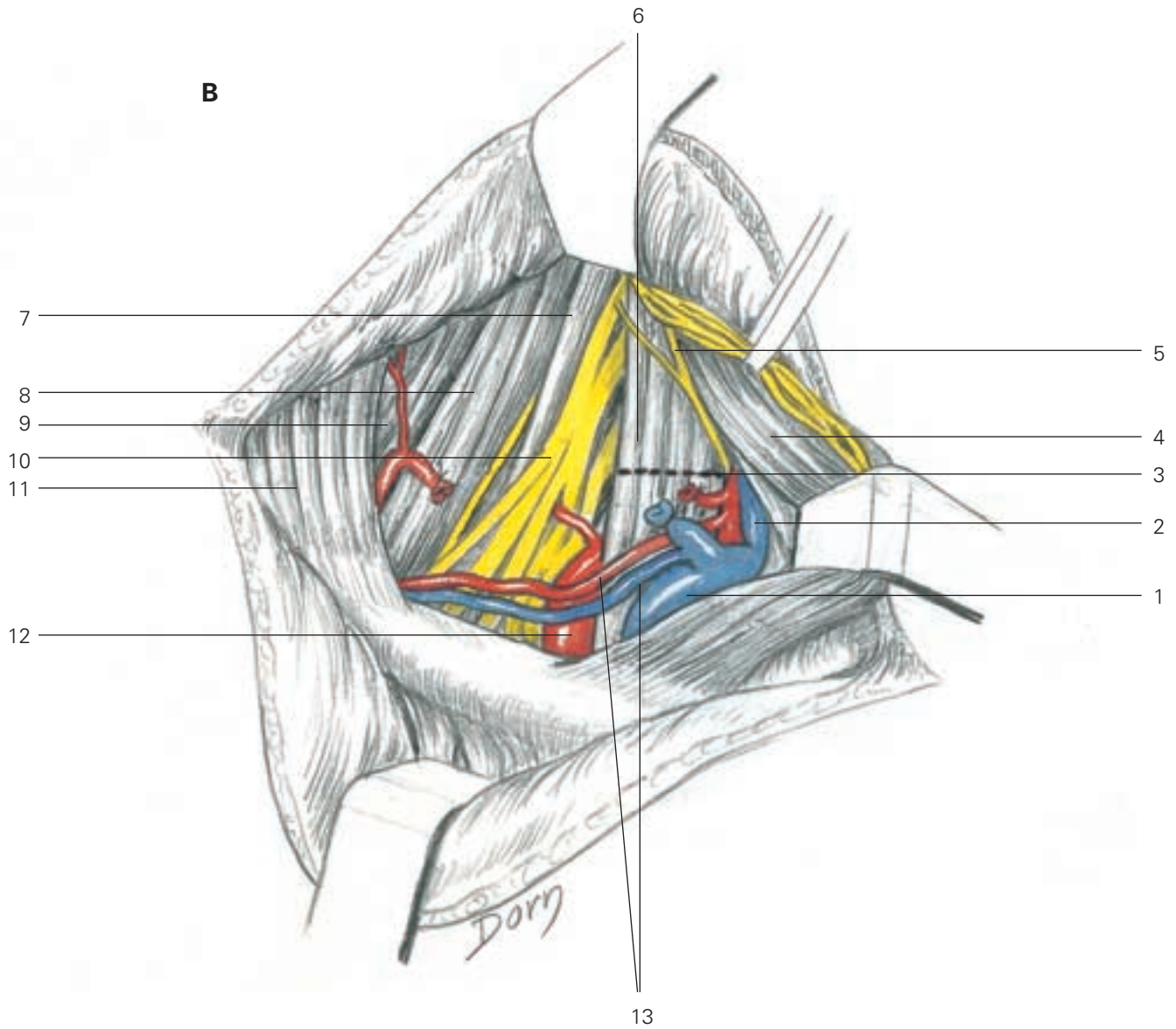
A, B Supraclavicular approach. The two drawings show the progressive dissection to the plexus, severing the omohyoideus (a) and then the scalenus anterior (b). Note the coloured neurovascular structures which form a key point for the rough drawings.



A

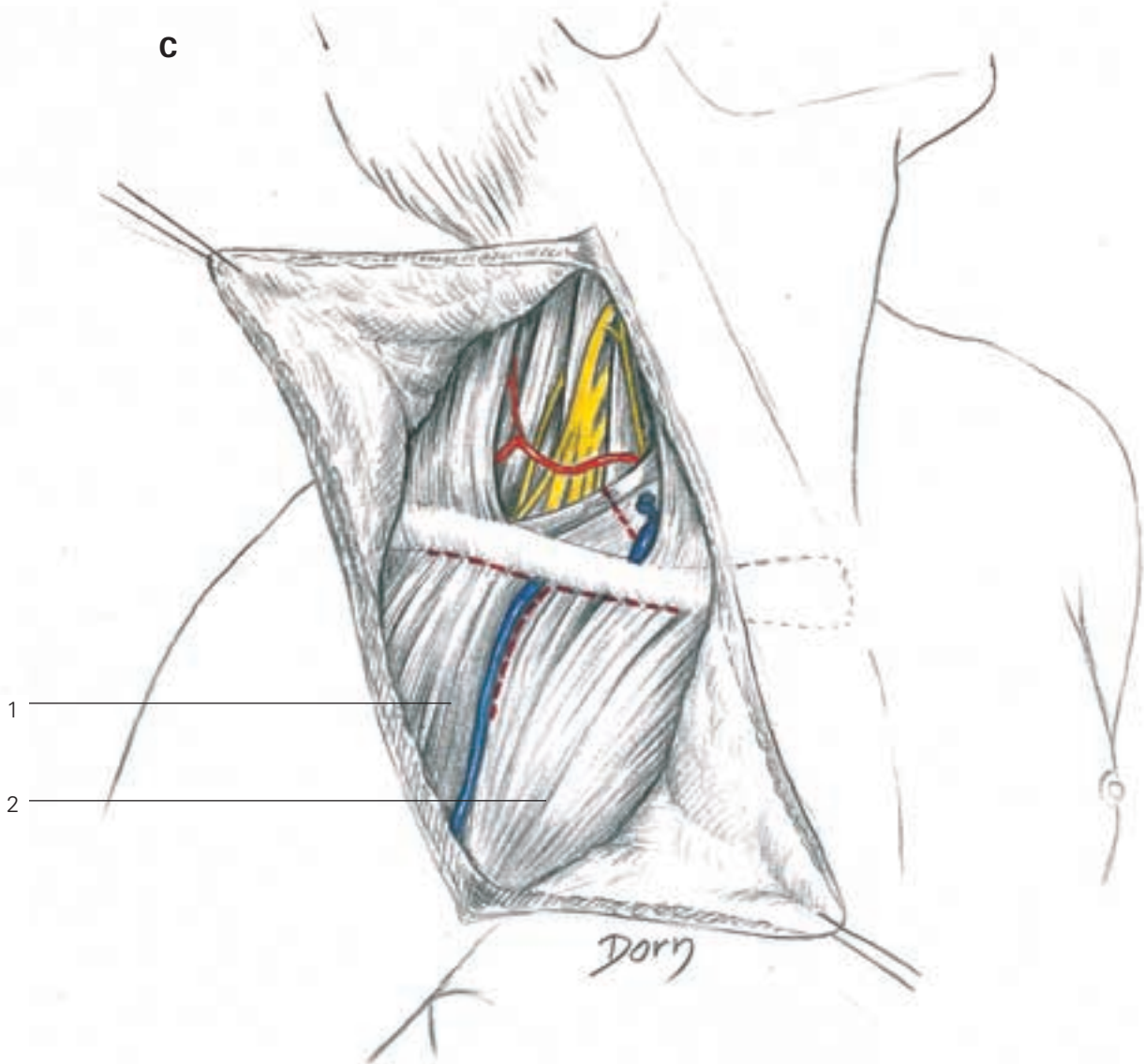
- 1 retracted sternocleidomastoid
- 2 scalenus anterior
- 3 phrenic nerve
- 4 accessory phrenic nerve
- 5 scalenus medius
- 6 branch to rhomboid and levator scapular
- 7 superficial cervical artery
- 8 omohyoideus
- 9 omohyoideus fascia

Hand and peripheral nerve surgery



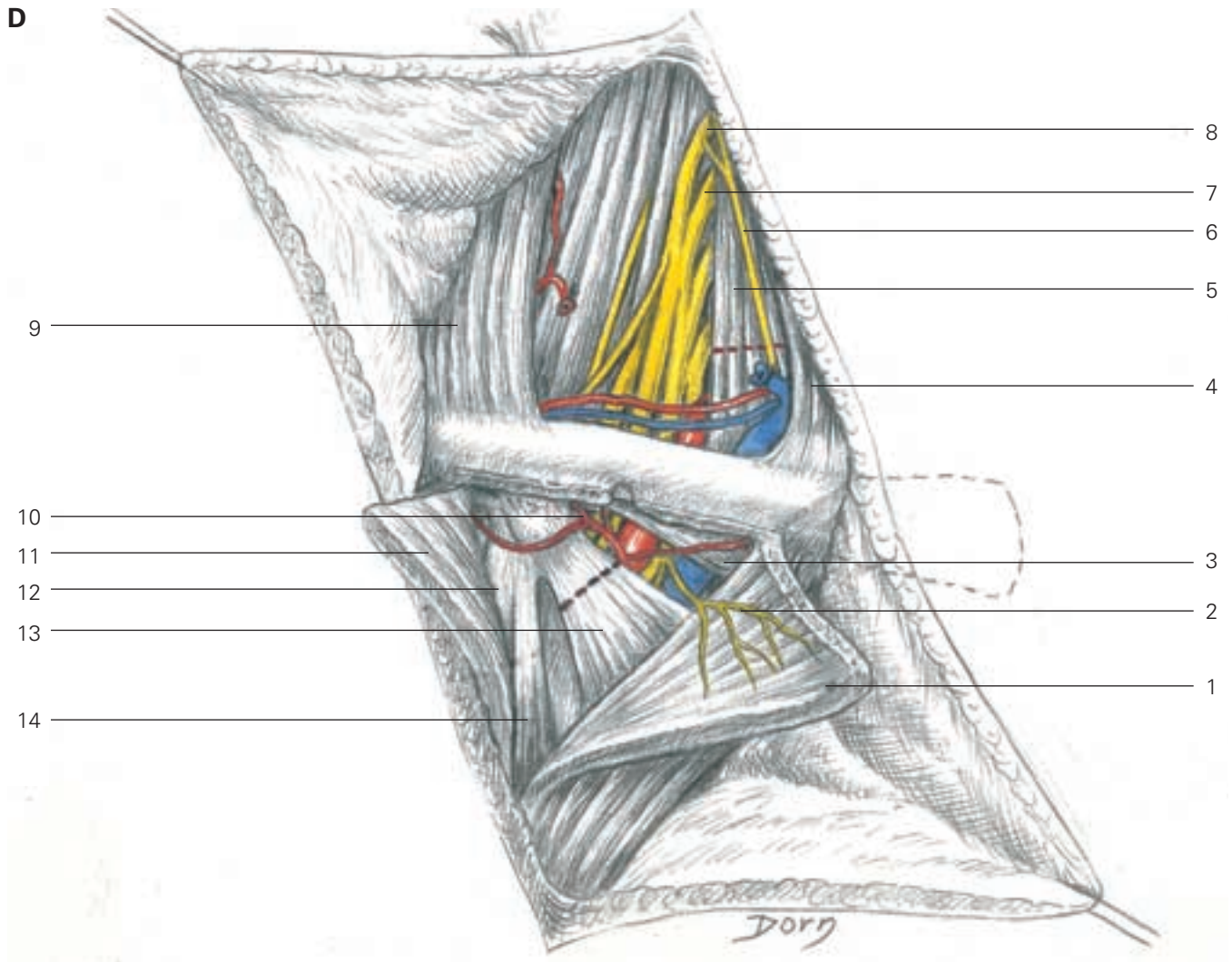
- B**
- 1 subclavian vein
 - 2 int. jugular vein
 - 3 line of division of scalenus ant.
 - 4 sterno-cleidomastoid retracted
 - 5 phrenic nerve retracted
 - 6 scalenus anterior
 - 7 scalenus medius
 - 8 levator scapula
 - 9 splenius capitis
 - 10 brachial plexus
 - 11 trapezius
 - 12 subclavian artery
 - 13 supra-scapular artery and vein

C, D Supraclavicular and infraclavicular approach. Pectoralis minor is severed to expose the divisions of the plexus. If necessary the clavicle can also be osteotomised.



- 1 deltoid
- 2 pectoralis major

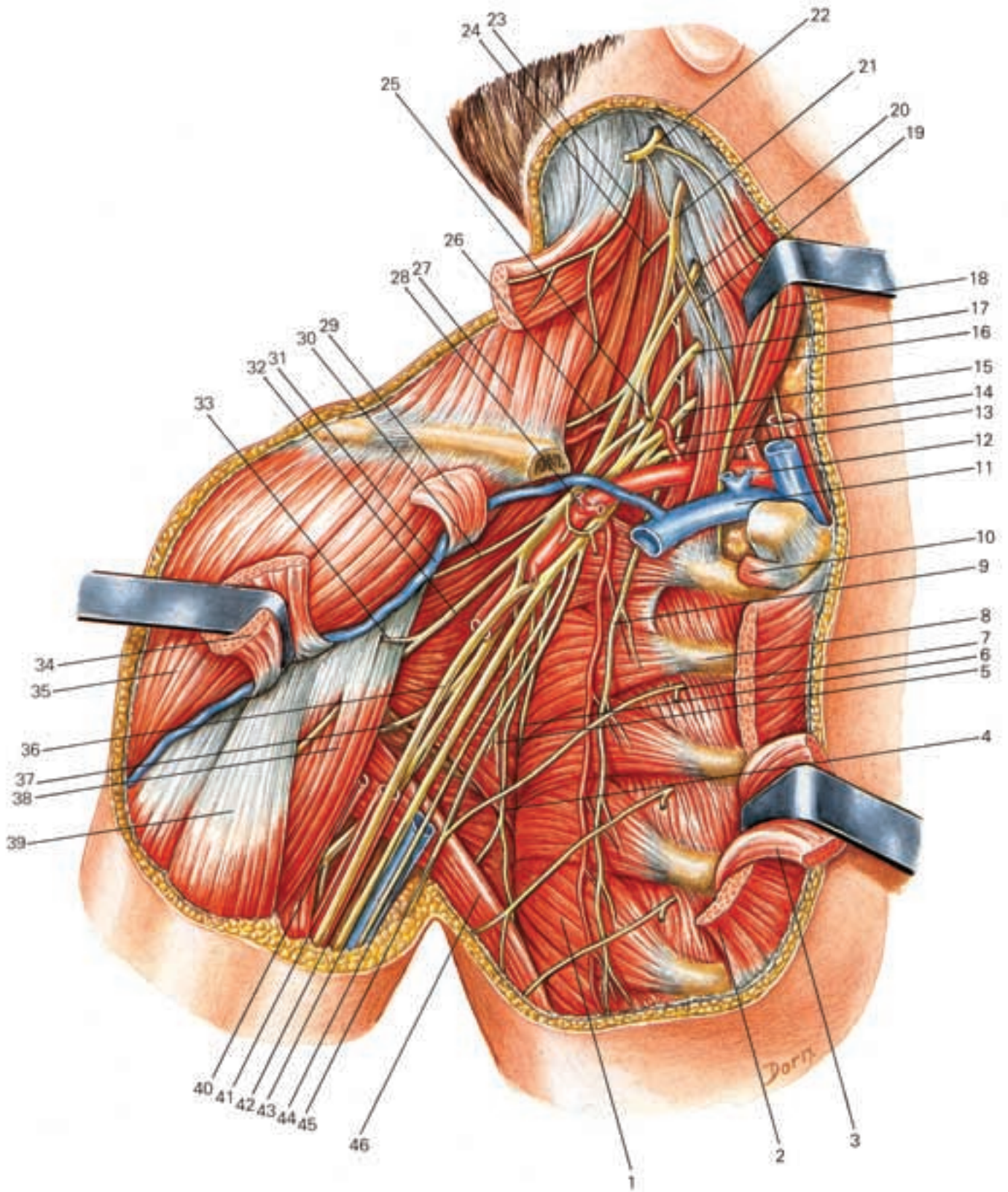
Hand and peripheral nerve surgery



- D**
- | | | |
|------------------------|---------------------|----------------------------|
| 1 pectoralis major | 5 scalenus anterior | 10 thoraco-acromial artery |
| 2 lat. pectoral nerve | 6 phrenic nerve | 11 deltoid |
| 3 subclavius | 7 C6 | 12 short head biceps |
| 4 sterno-cleidomastoid | 8 C5 | 13 pectoralis minor |
| | 9 trapezius | 14 coraco brachial |
-
- E**
- | | | |
|------------------------------|----------------------------|---|
| 1 serratus anterior | 17 C7 | 33 nerve to coracobrachialis |
| 2 pectoralis major | 18 phrenic nerve | 34 pectoralis major |
| 3 pectoralis minor | 19 branch to phrenic nerve | 35 deltoid |
| 4 thoracodorsal nerve | 20 C6 | 36 median nerve |
| 5 inferior subscapular nerve | 21 C5 | 37 axillary nerve |
| 6 superior subscapular nerve | 22 C4 | 38 coracobrachialis |
| 7 second intercostal nerve | 23 accessory nerve | 39 biceps brachii |
| 8 second rib | 24 branch to rhomboids | 40 profunda brachii |
| 9 long thoracic nerve | 25 subclavius nerve | 41 axillary artery |
| 10 subclavius muscle | 26 suprascapular nerve | 42 radial nerve |
| 11 subclavian vein | 27 trapezius | 43 ulnar nerve |
| 12 subclavian artery | 28 acromiothoracic artery | 44 axillary vein |
| 13 T1 | 29 pectoralis minor | 45 medial brachial cutaneous nerve of arm |
| 14 suprascapular artery | 30 upper subscapular nerve | 46 latissimus dorsi |
| 15 C8 | 31 cephalic vein | |
| 16 scalenus anterior | 32 musculocutaneous nerve | |

Surgery of the peripheral nerves

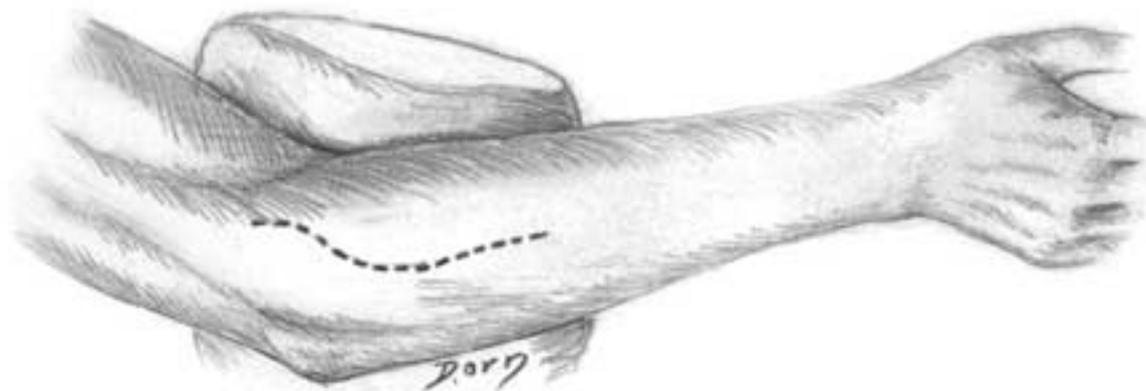
E Anatomical view of all structures.



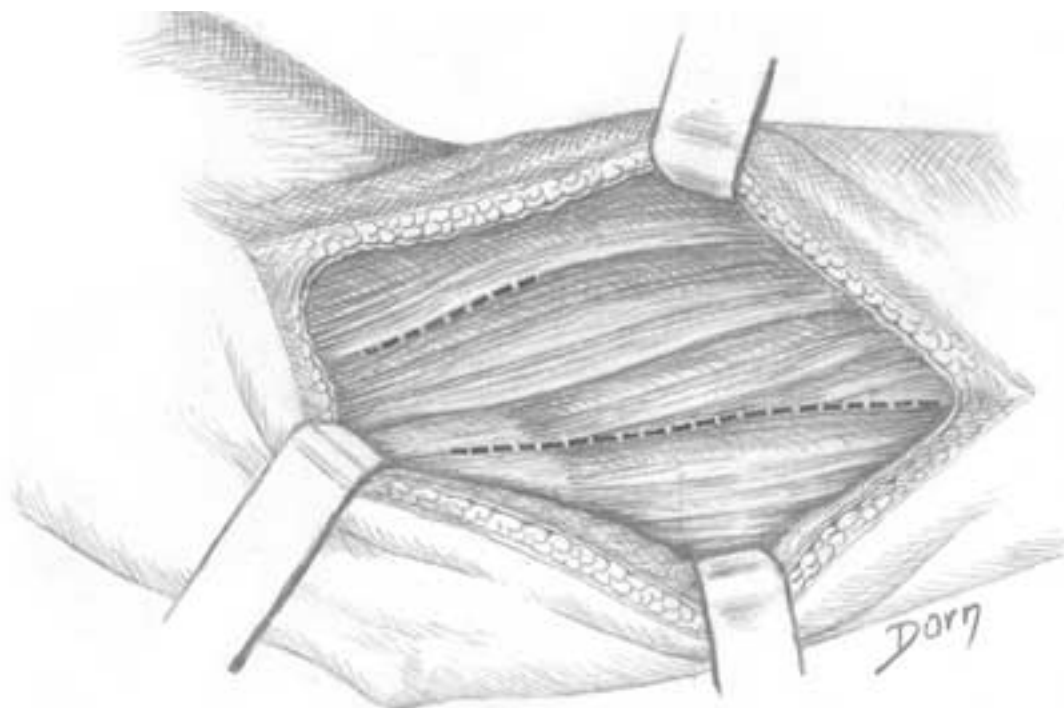
Hand and peripheral nerve surgery

Exposure of the interosseous nerve
(posterior motor branch of the radial
nerve)

A Skin incision on the posterolateral aspect of the
forearm.

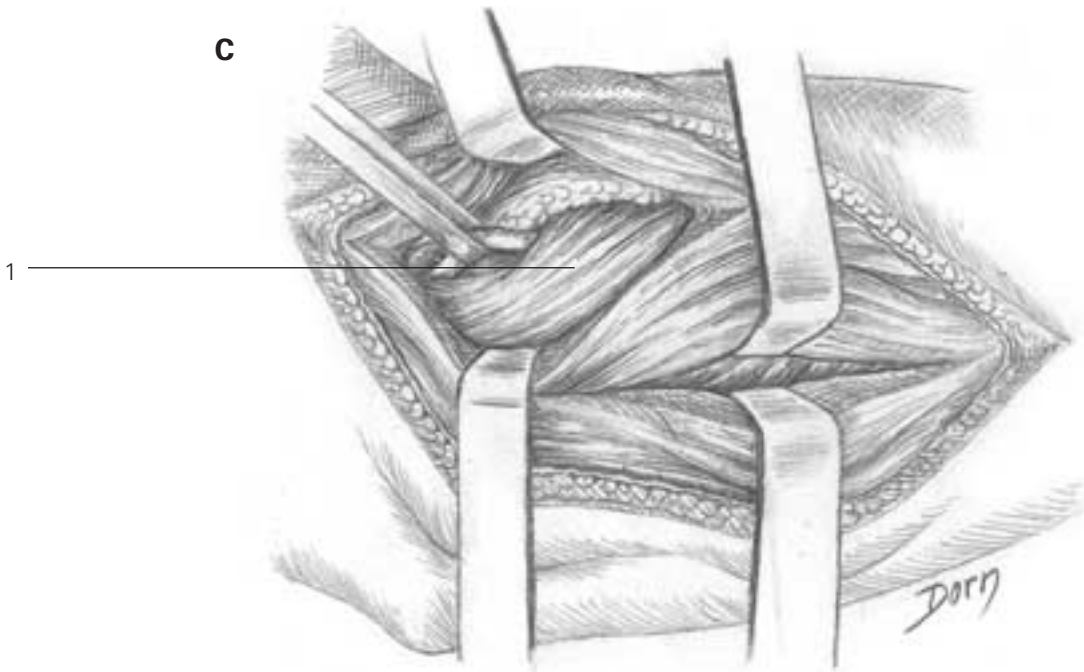


B Muscles are exposed. Two approaches are
mandatory: the first one between the extensors of
the carpus and the extensor digitorum communis
and the second one between the extensors of the
fingers and extensor carpi ulnaris.



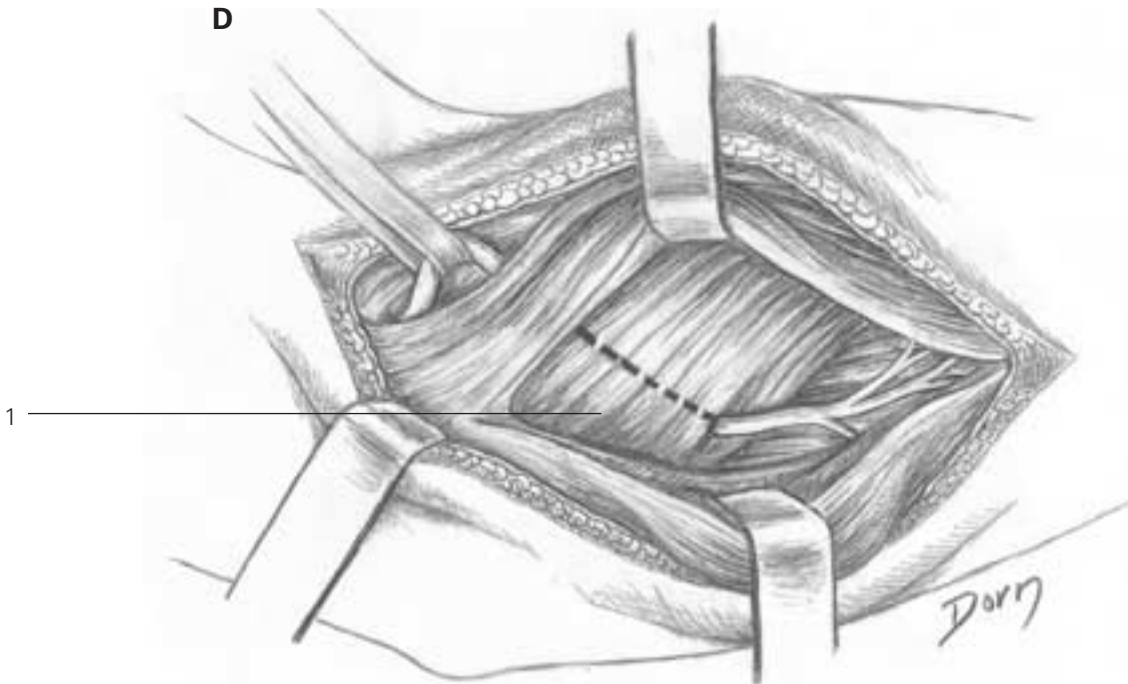
C, D The posterior radial nerve is identified proximally and distally to the supinator muscle.

C



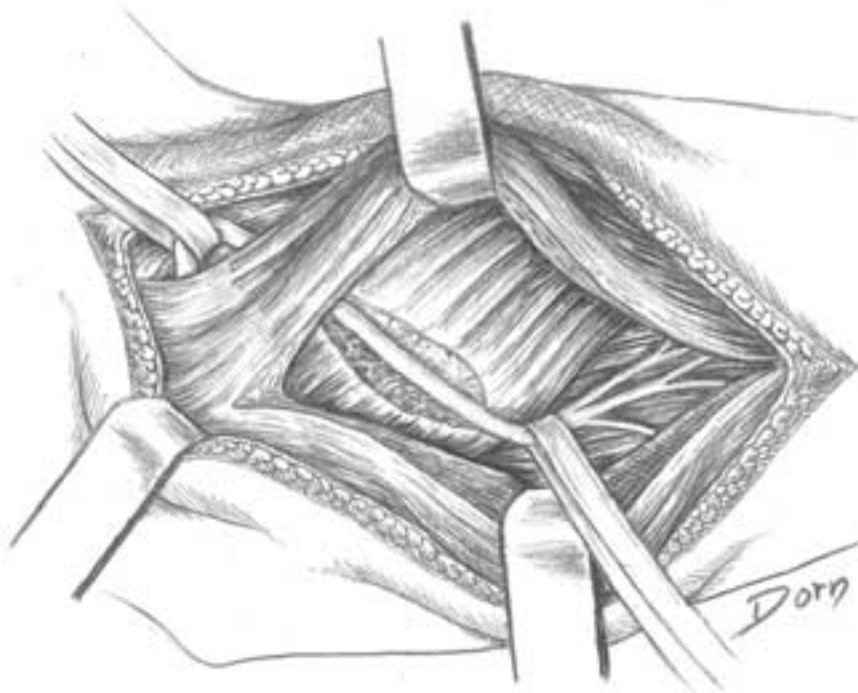
1 supinator

D



Hand and peripheral nerve surgery

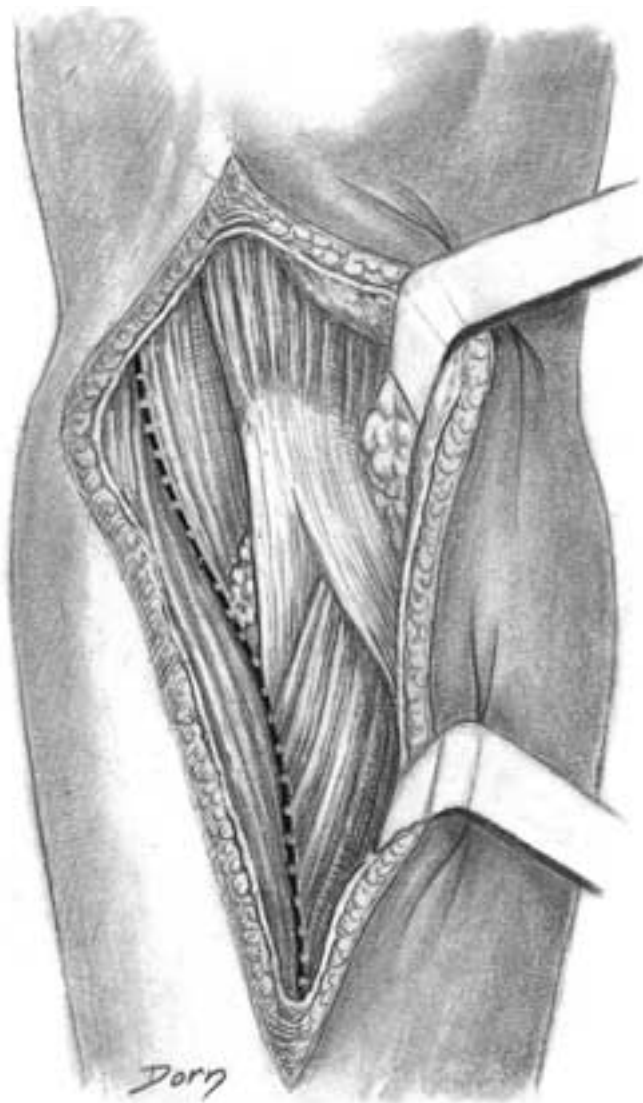E Superficial head of the supinator has been severed to release the nerve.



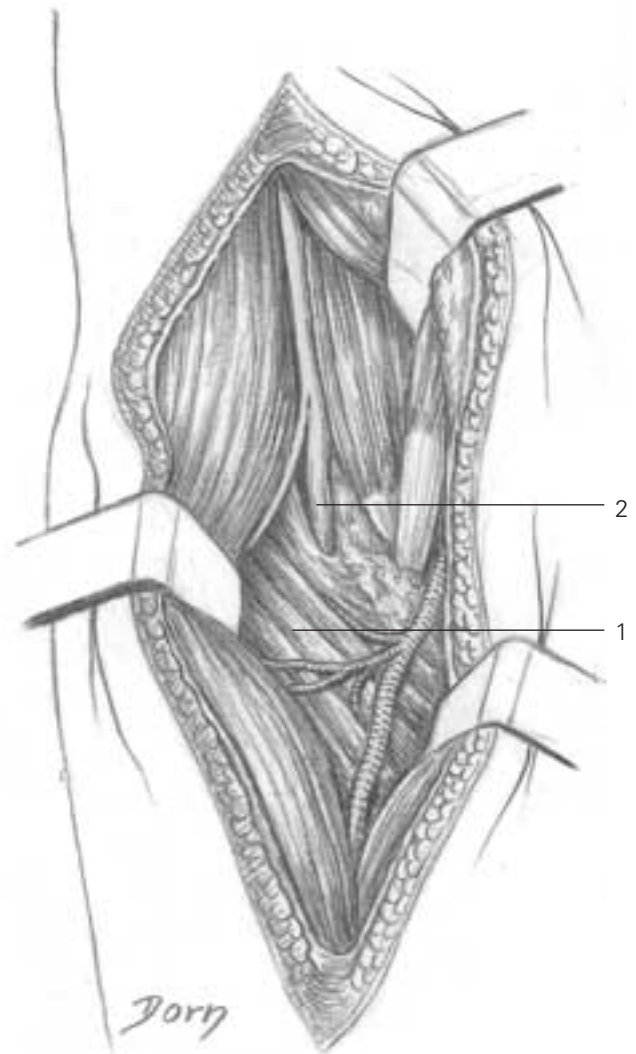
Surgery of the peripheral nerves

Exposure of the radial nerve at the elbow (common trunk and its division into anterior and posterior branches)

A The plane between the brachioradialis and brachialis is developed.



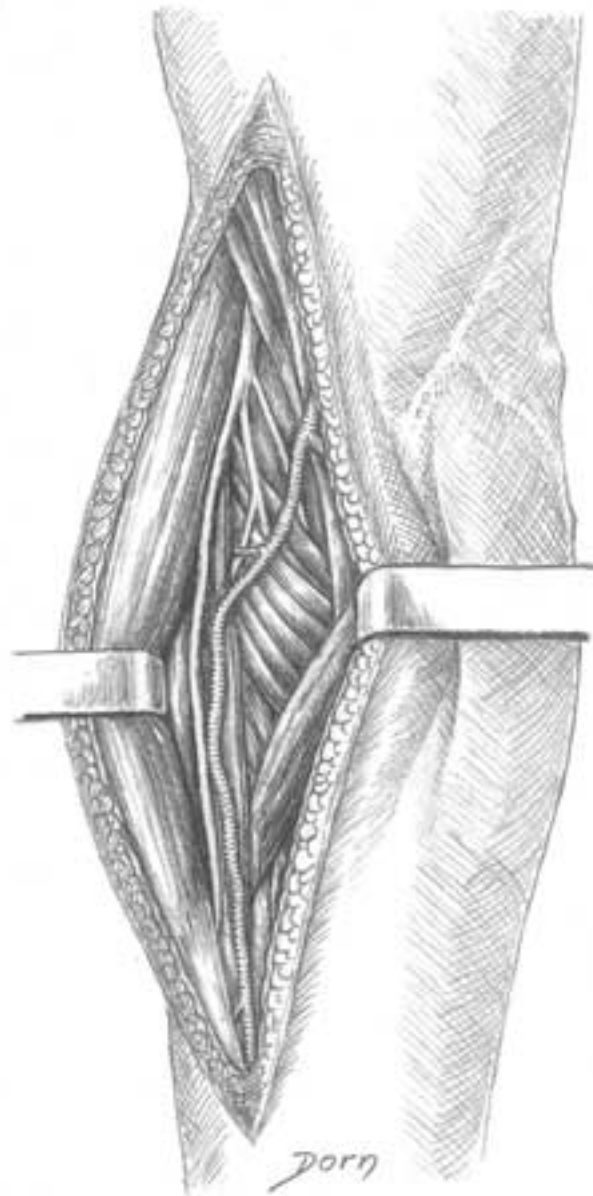
B Medially the biceps and the pronator teres muscles are retracted. The radial nerve and its division are exposed. The posterior branch courses beneath the superficial head of the supinator muscle.



- 1 supinator
- 2 radial nerve

Hand and peripheral nerve surgery

C By reflecting the brachioradialis muscle, the anterior branch is exposed. It courses near the radial artery.



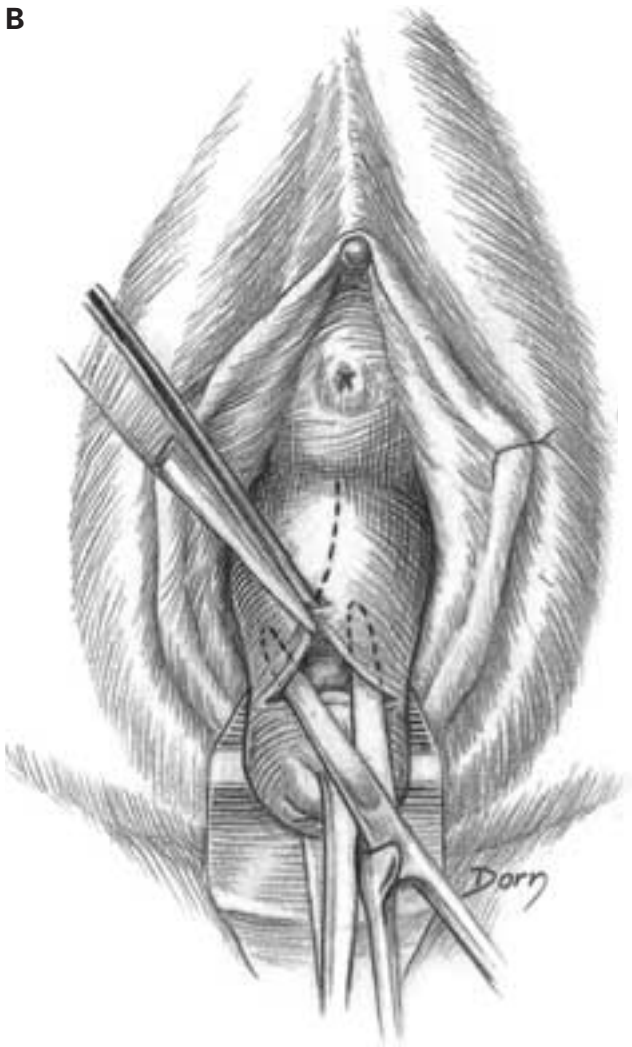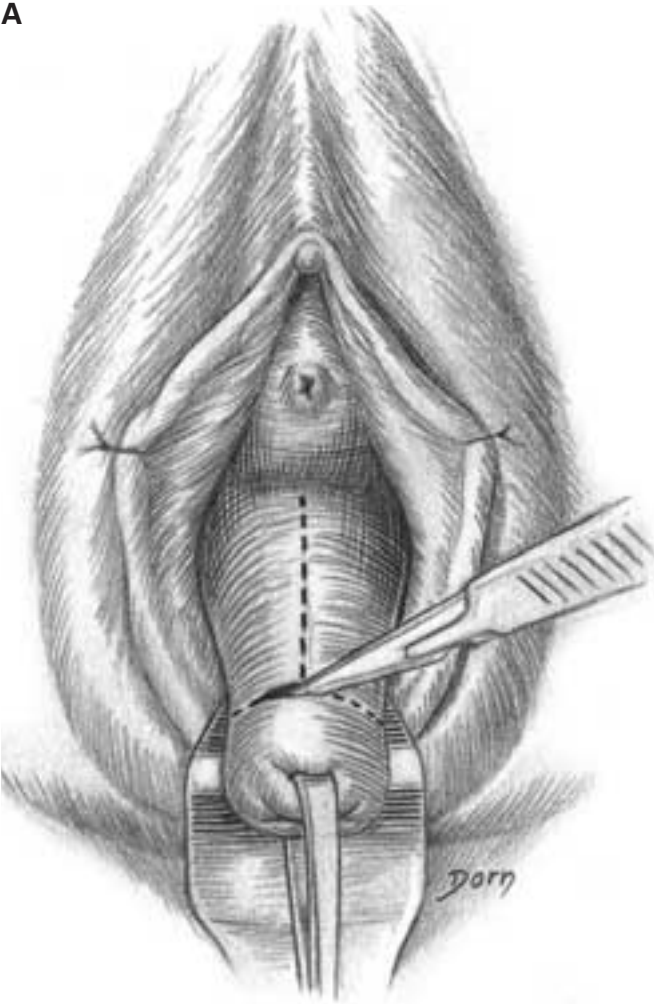
Gynaecological surgery

Some of these drawings have been made from rough sketches made in the operating theatre. They illustrate the numerous techniques for treating genital prolapse.

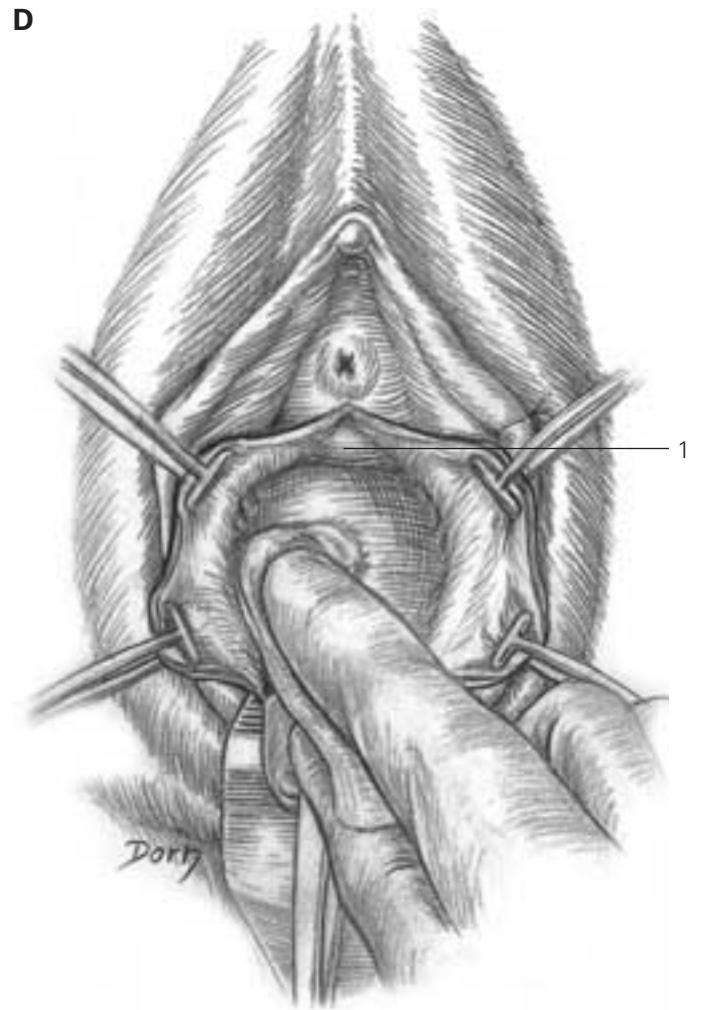
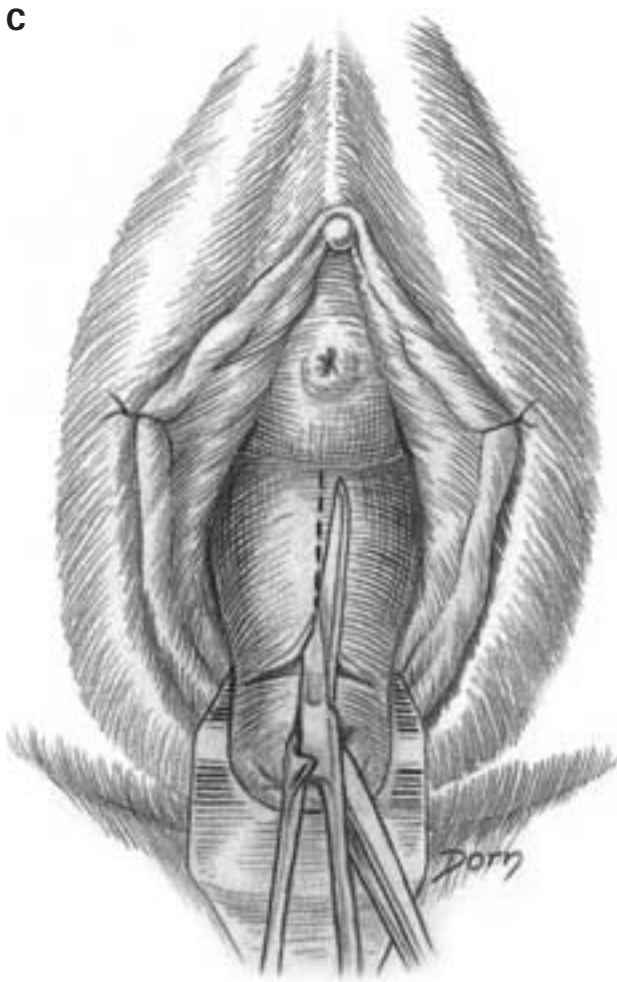
Gynaecological surgery

The lower approach of the genital prolapse and the separation of the vagina and the bladder

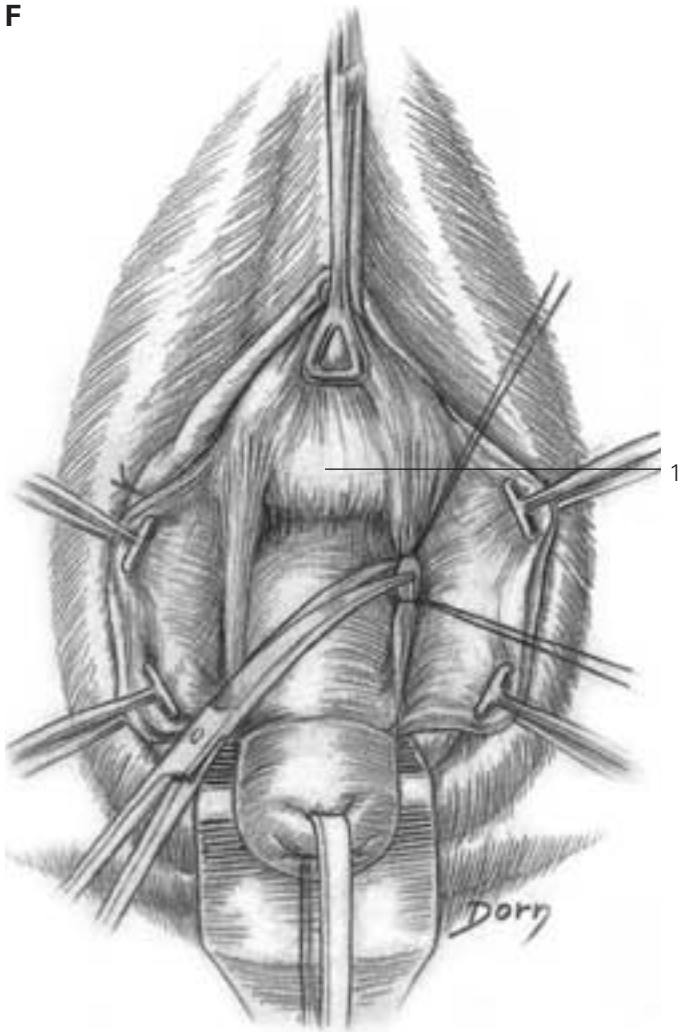
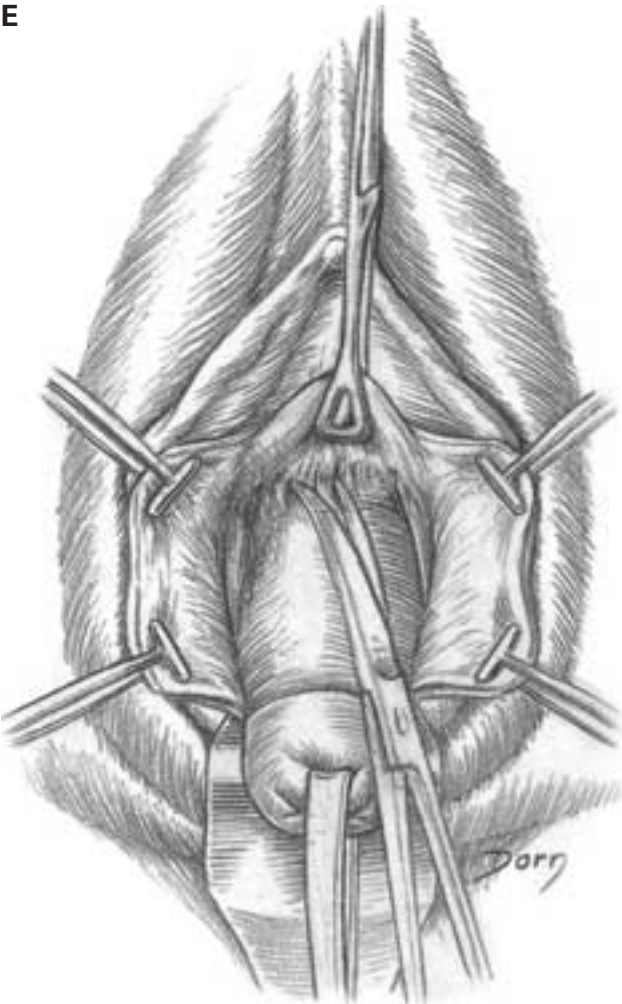
A–C The anterior aspect of the vagina is incised and the plane of dissection between the vagina and the bladder is developed.



D-F The separation between the vagina and the bladder is pursued; the long forceps holds the bladder.



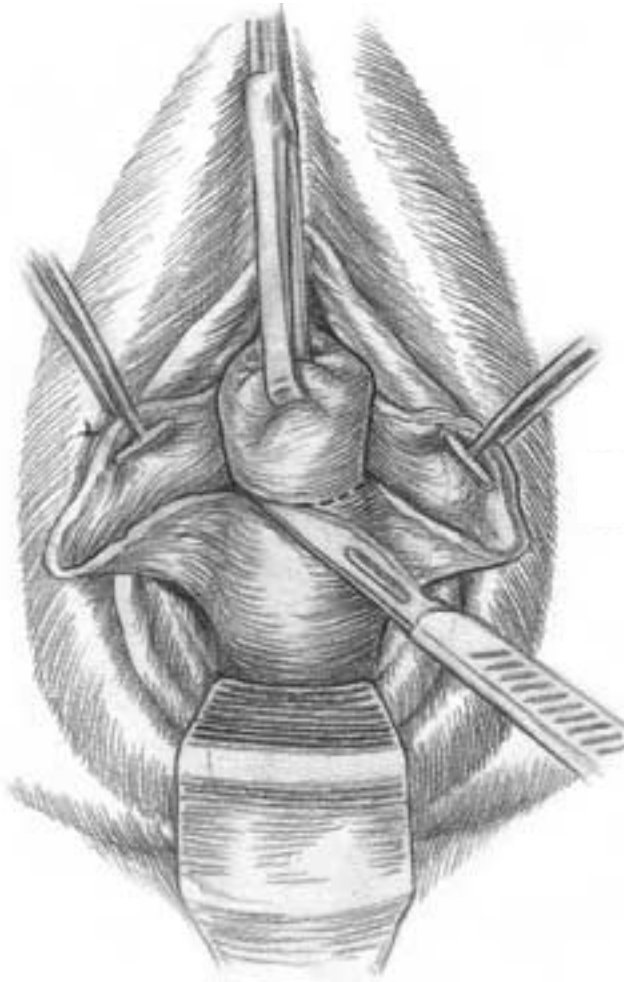
1 bladder



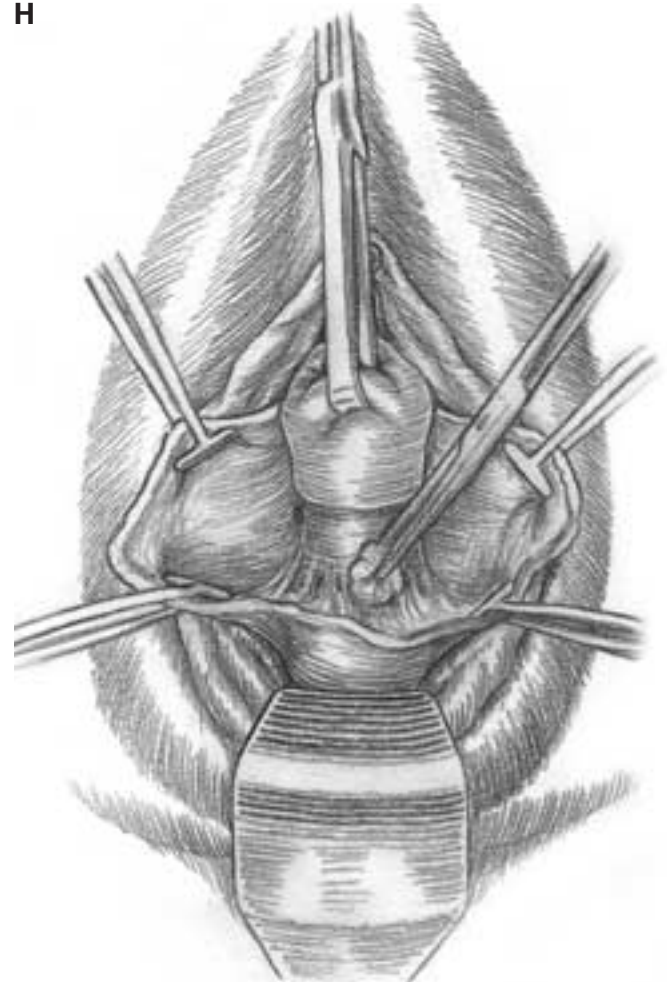
1 bladder

G, H Separation of the posterior aspect of the vagina.

G

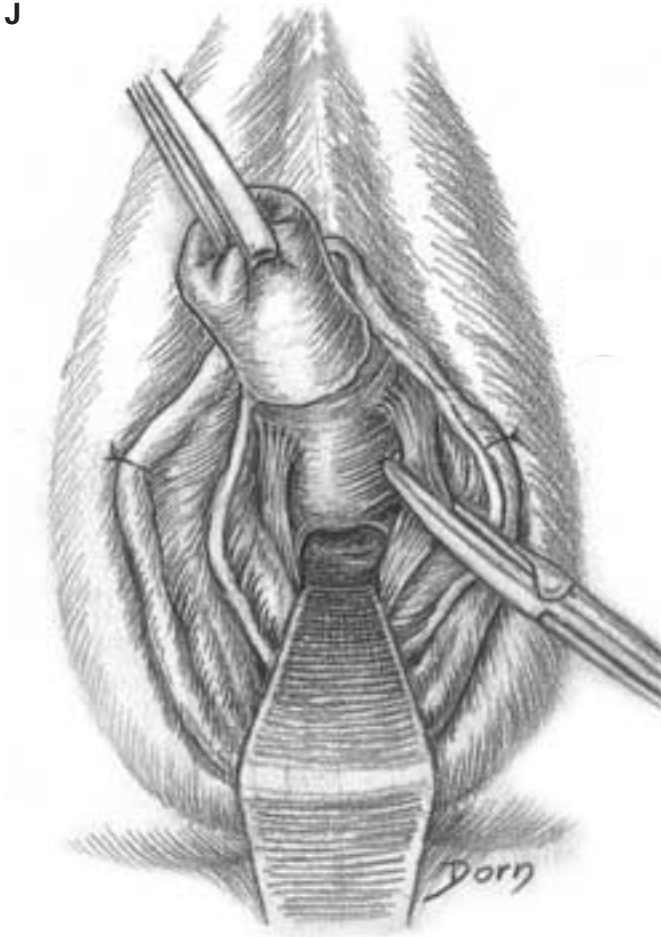
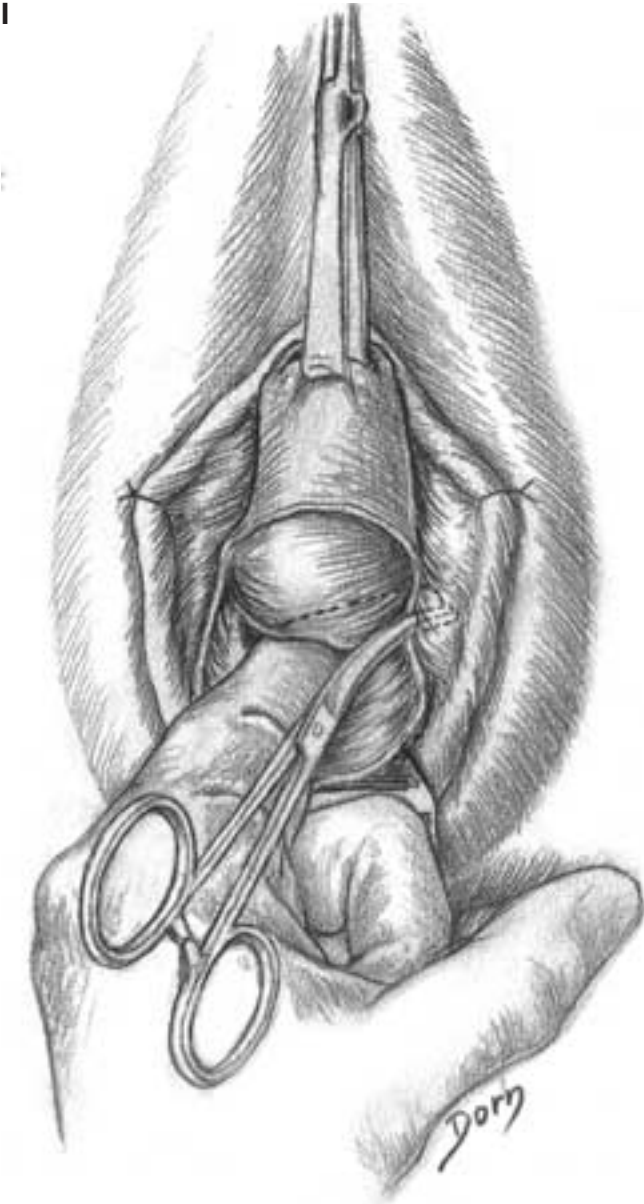

H



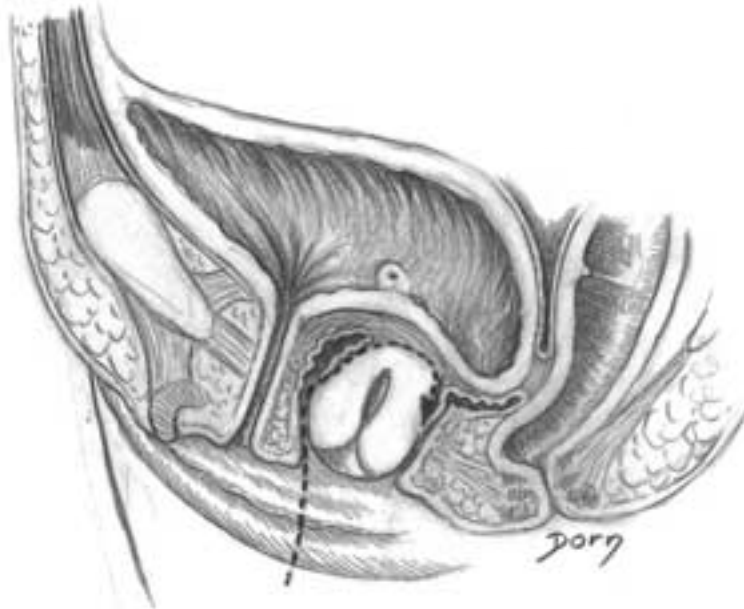
Gynaecological surgery

I, J The cul-de-sac of Douglas is opened and the uterosacral ligaments are ligated and cut.

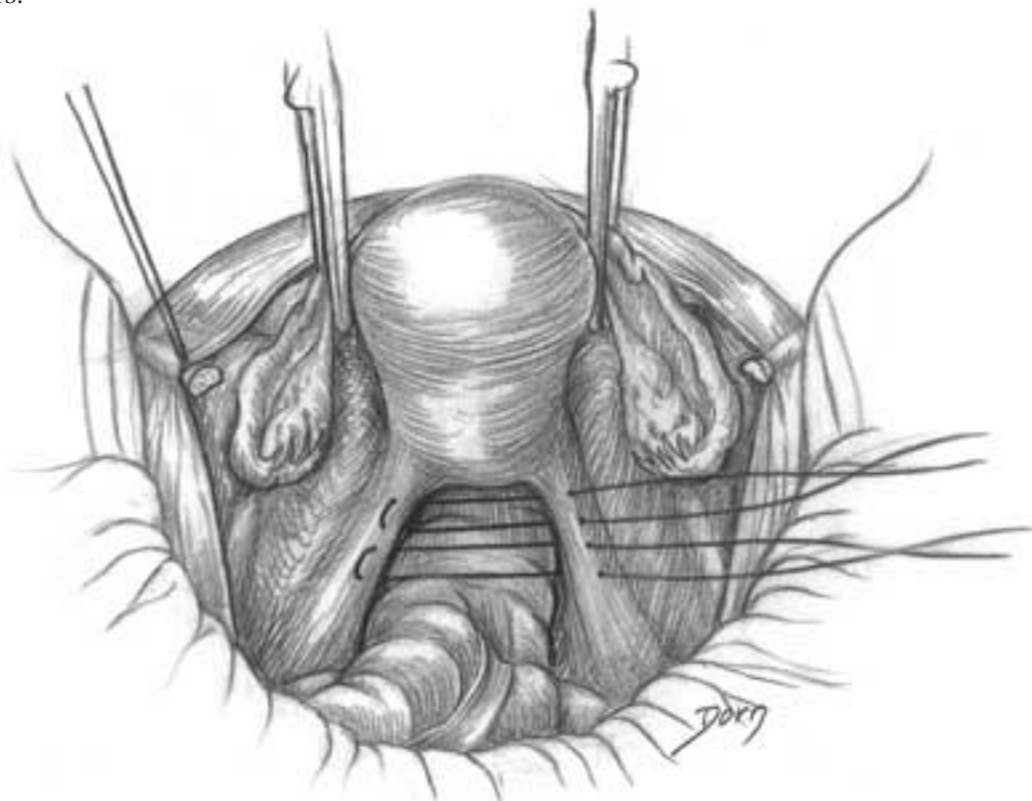


Treatment of genital prolapse after hysterectomy

A In this procedure care should be taken of the bladder which can overlap behind the cervix of the uterus (after a hysterectomy).



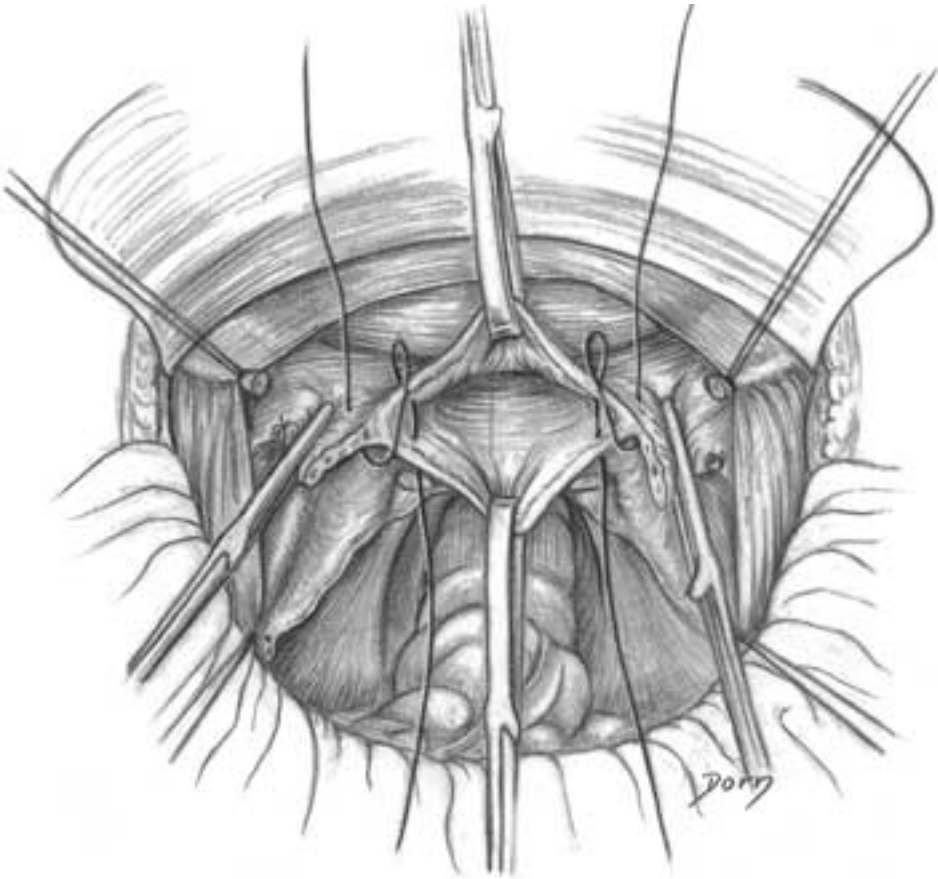
B Just before the hysterectomy, the threads are passed through the uterosacral ligaments, taking care of the ureters.



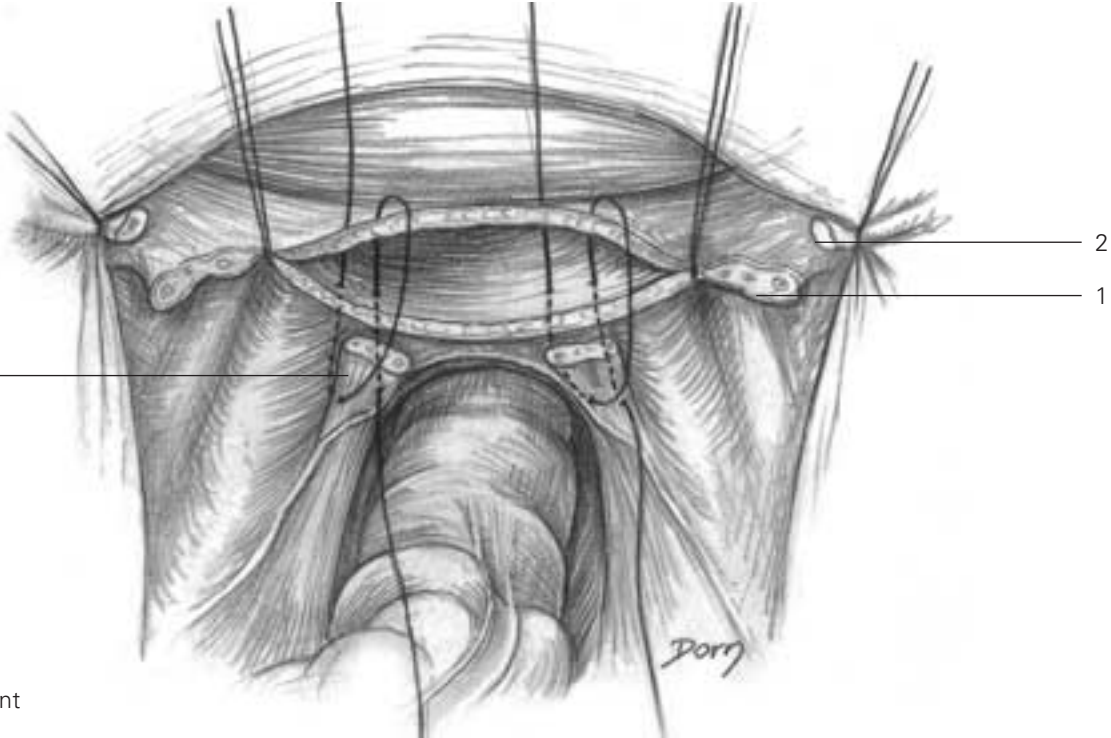
Gynaecological surgery

C-E The hysterectomy is completed by an upper approach.

C

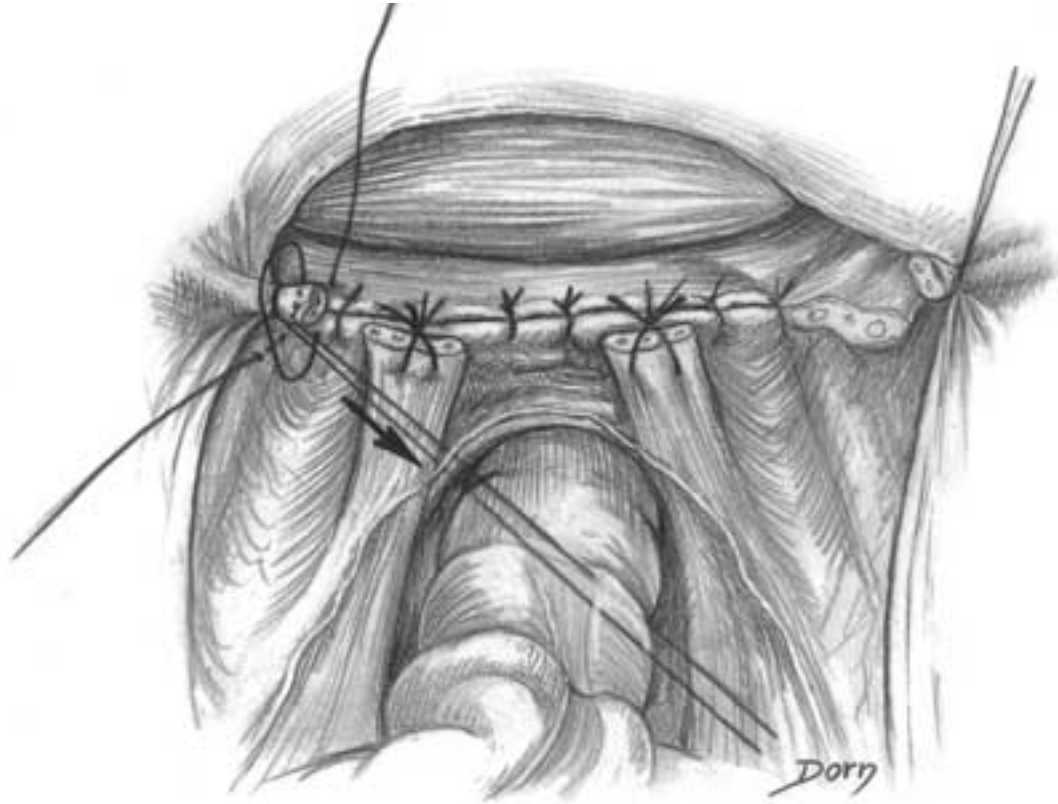


D

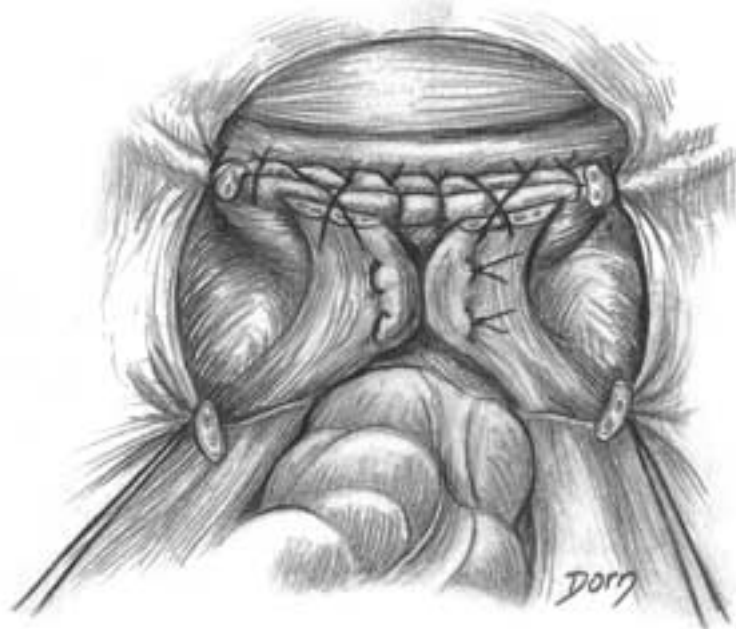

- 1 cardinal ligament
- 2 round ligament
- 3 uterosacral ligament

E



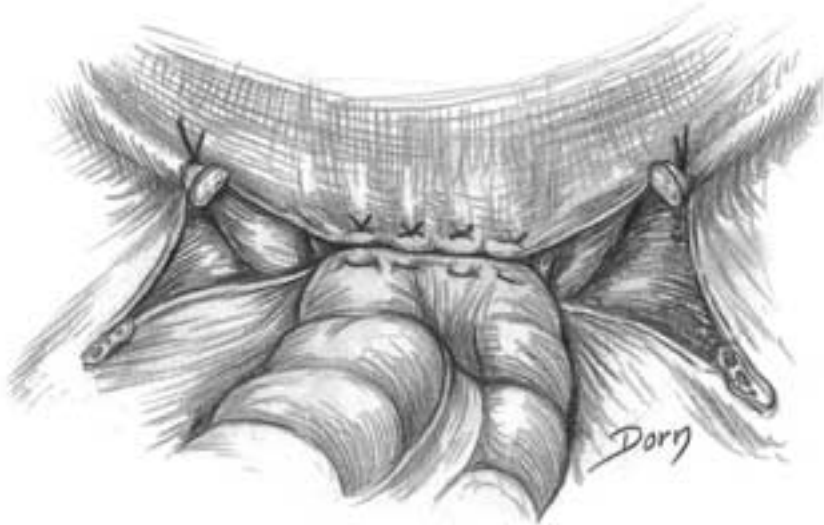
F The vagina is sutured and the uterosacral ligaments are sutured to the vagina.



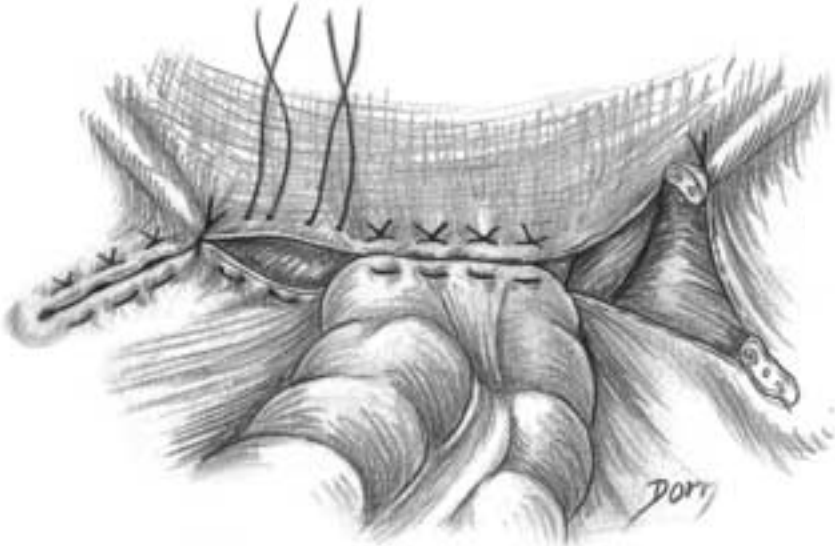
Gynaecological surgery

G-J The closure of the cul-de-sac of Douglas to prevent an ehytrocele.

G

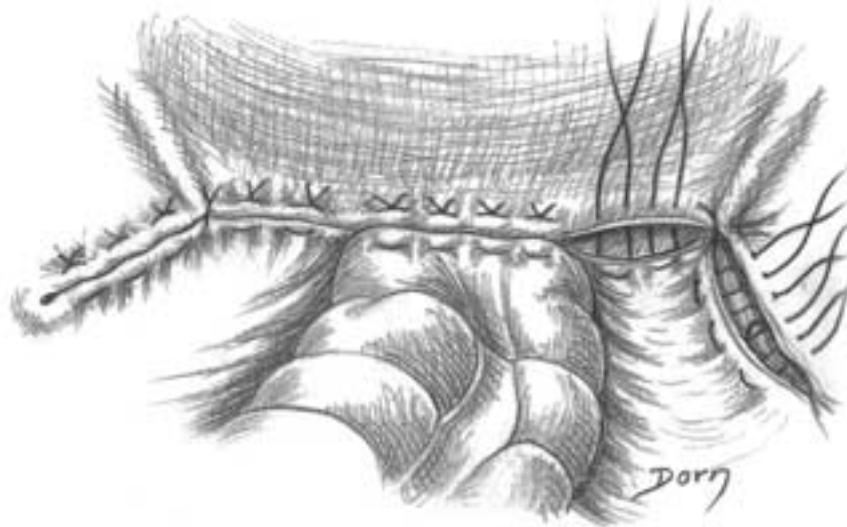


H

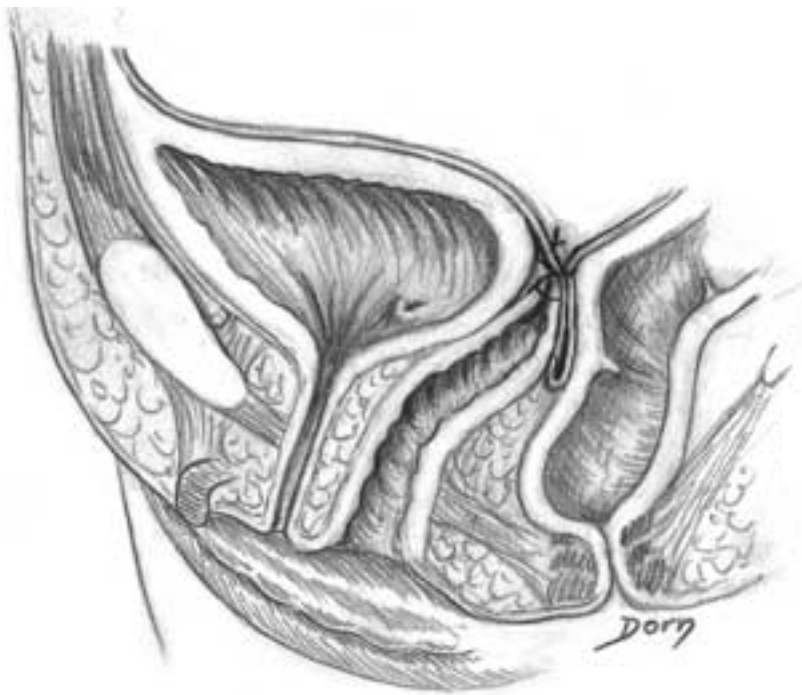


The perineum is sutured.

I



J

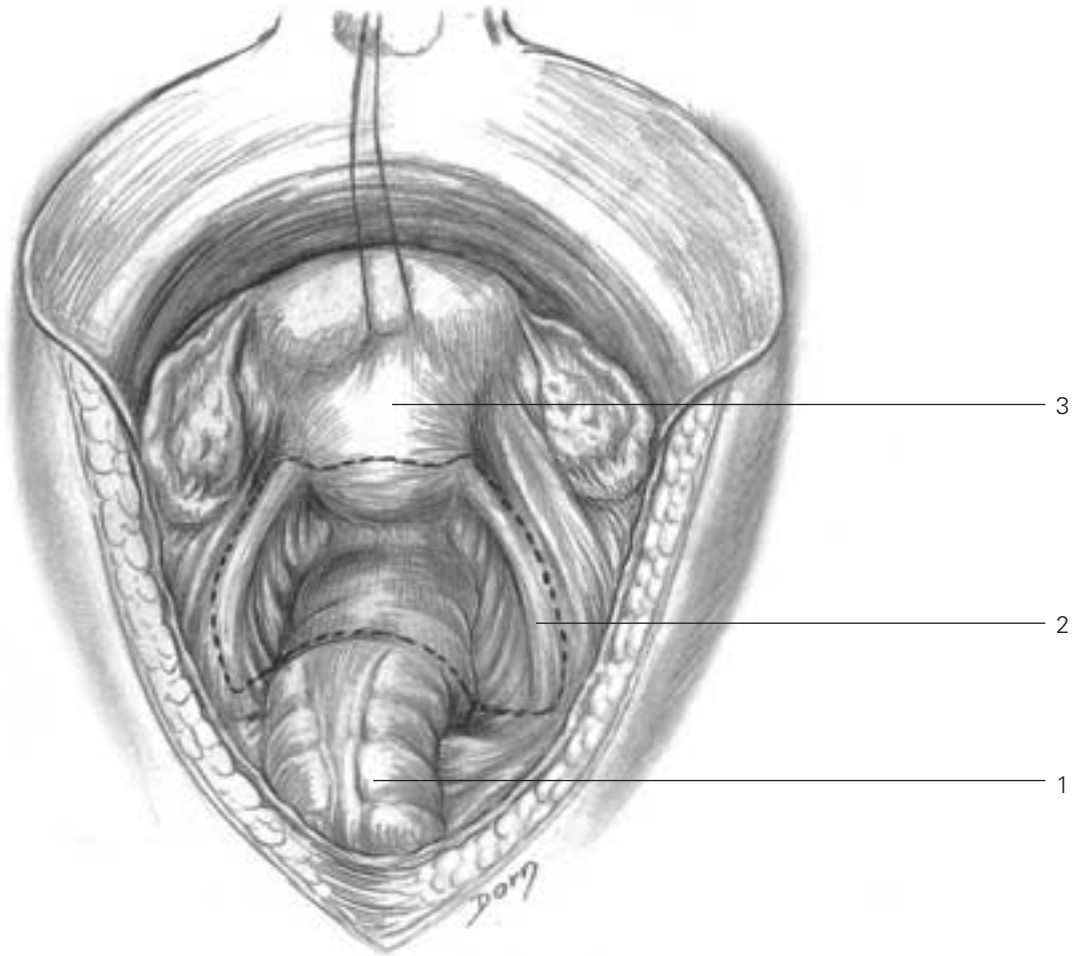


Gynaecological surgery

Surgical treatment of the elythrocele

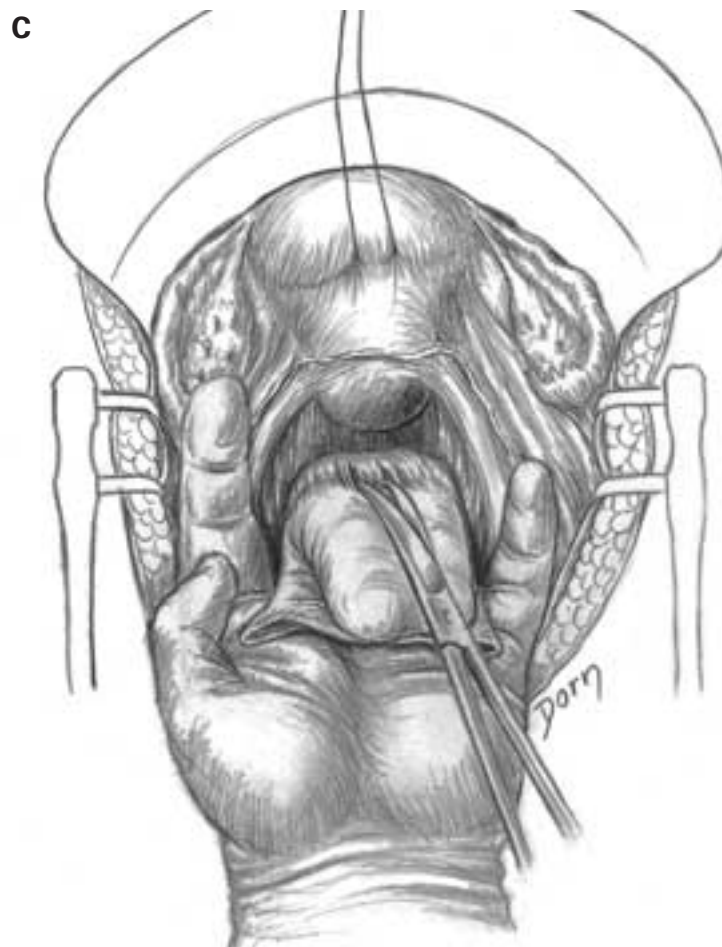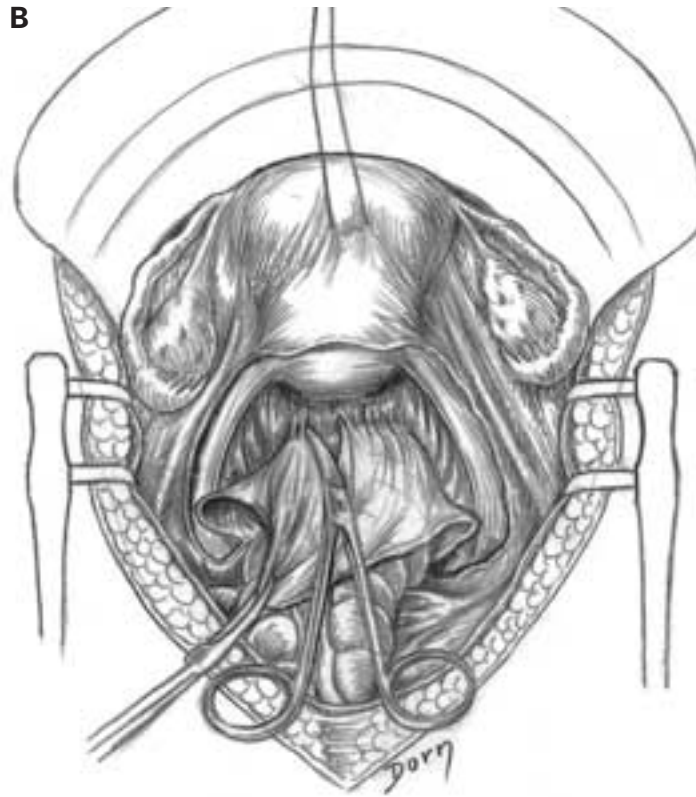
The elythrocele is the interposition of the cul-de-sac of Douglas between the vagina and the rectum. The surgery is performed by the abdominal approach.

A The uterus is held by threads; the dotted line is the landmark for the dissection. Care should be taken to spare the ureters.

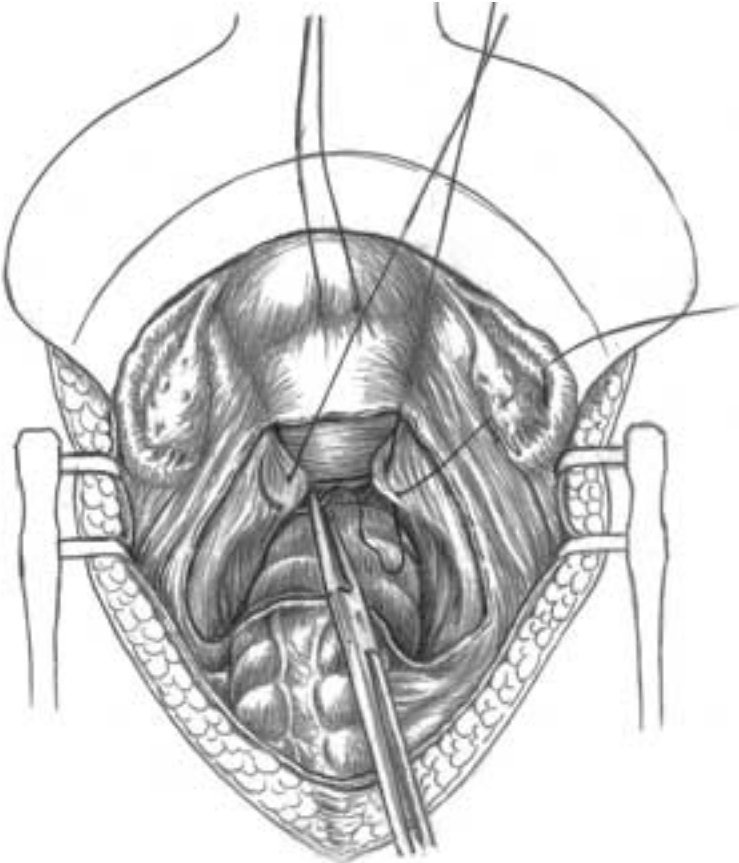


- 1 rectum
- 2 uterosacral ligament
- 3 uterus

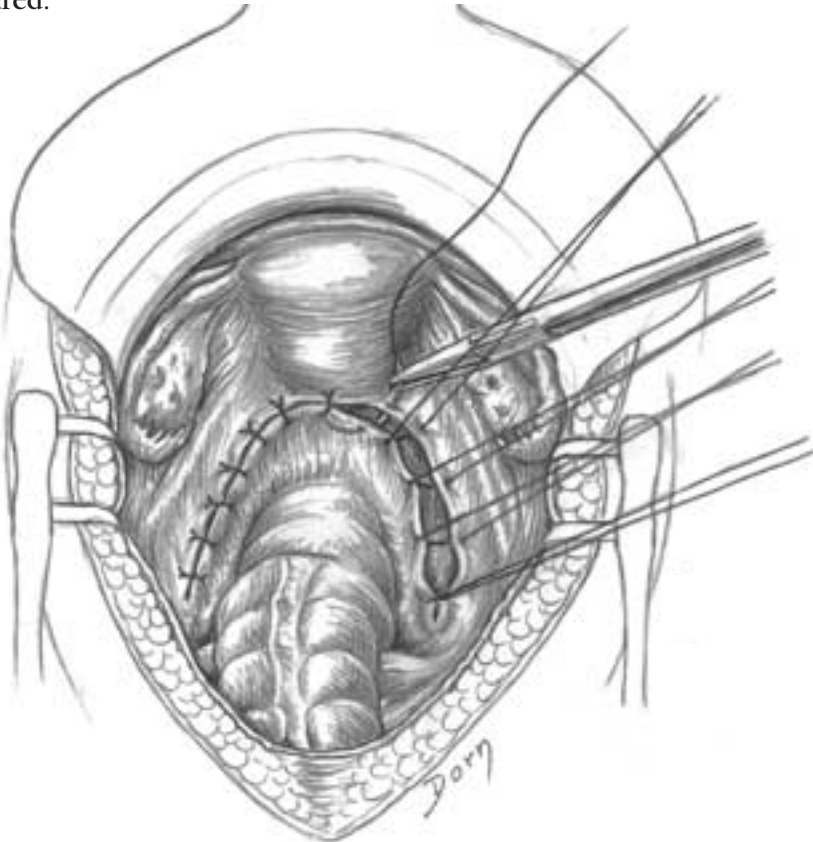
B, C The plane of dissection is developed between the posterior aspect of the uterus and the rectum.



D The uterosacral ligaments are sutured together.



E The peritoneum is sutured.



Urological surgery

Urology is a surgical specialty covering a large number of indications and procedures.

Transplantation of the kidney was the first successful allotransplantation to be performed a short time after the Second World War. This extraordinary achievement marked the start of the modern era of organ transplantation aided by the

advances in immunology. Urology is also concerned with reconstructive procedures involving loss of substance irrespective of the aetiology: tumour, congenital, traumatic, etc.

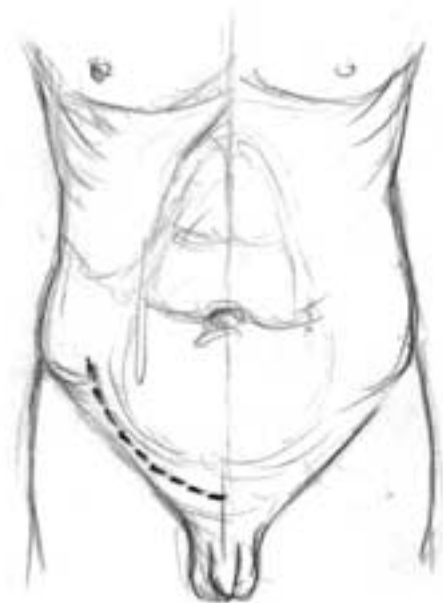
The last section of this chapter covers surgery of the sexual organs in sex modification.

Urological surgery

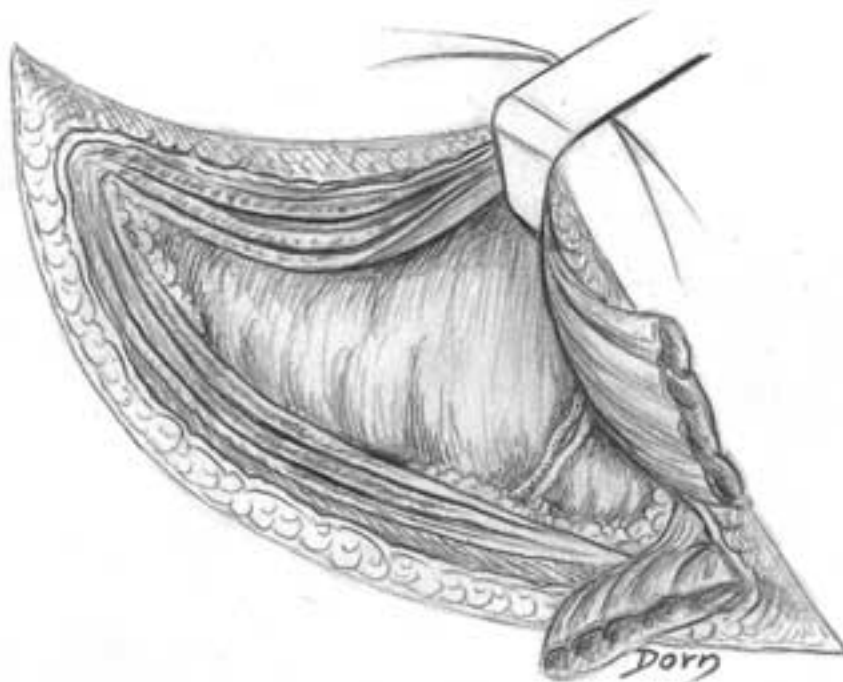Allotransplantation of the kidney

The various steps are shown in the drawings: surgical approach, preparation of the vessels and vascular anastomoses.

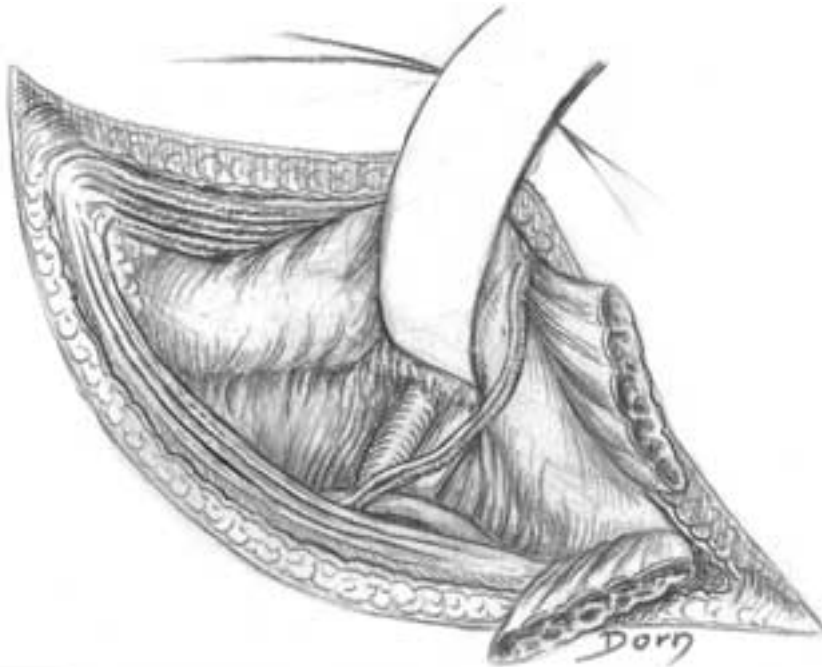A Skin incision.



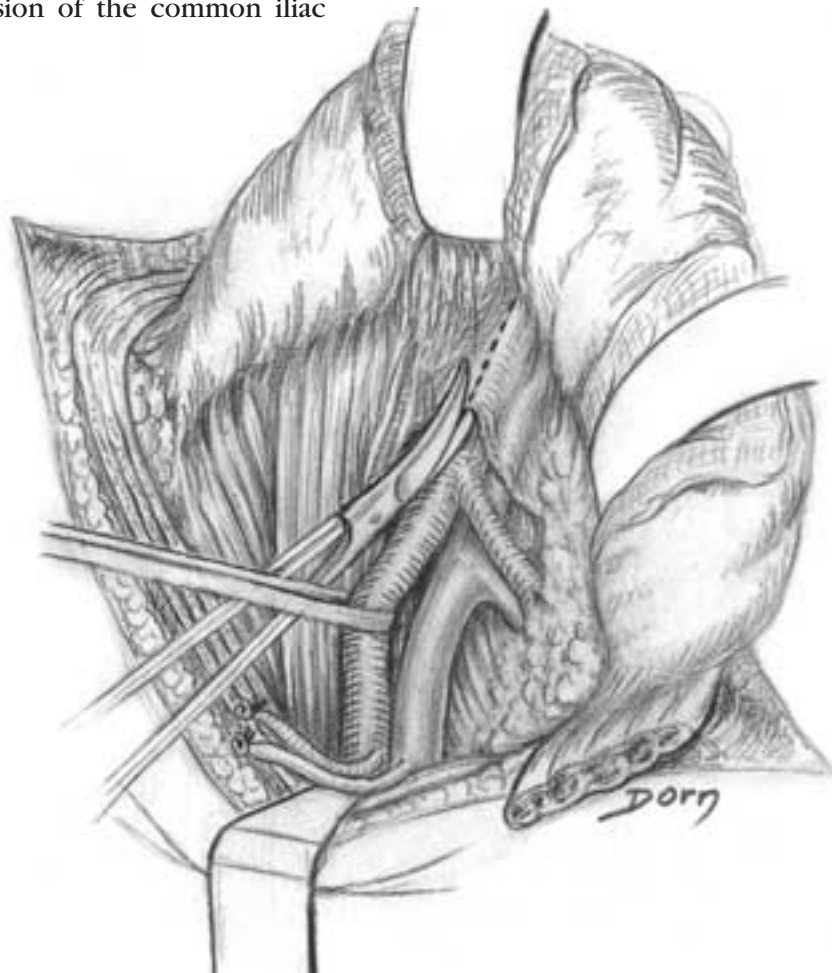
B The abdominal muscular wall is incised.



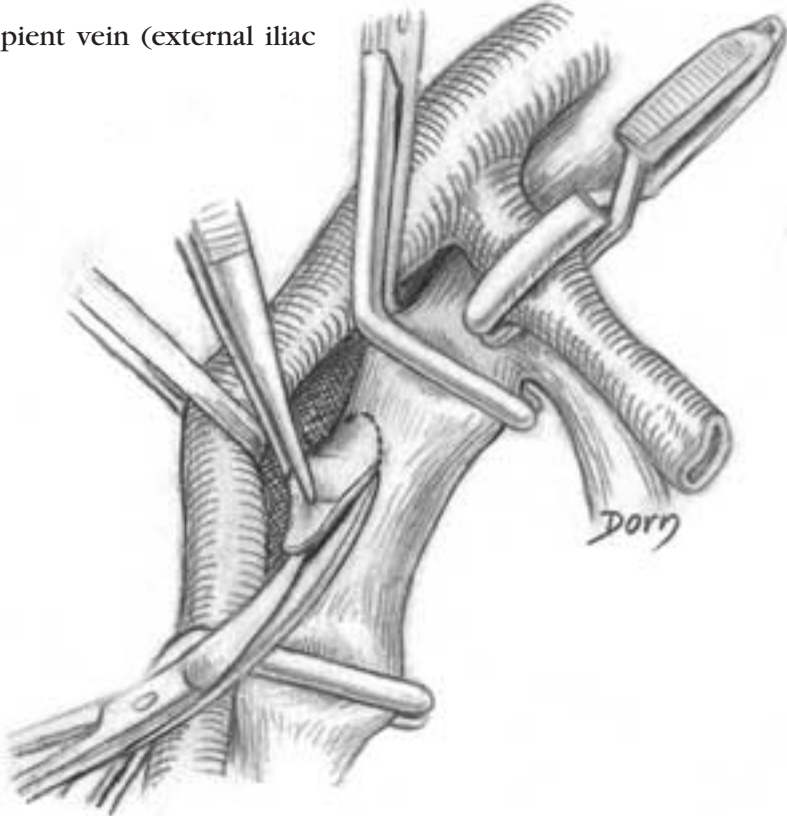
C The peritoneum is retracted which allows the dissection of the internal iliac vessels.



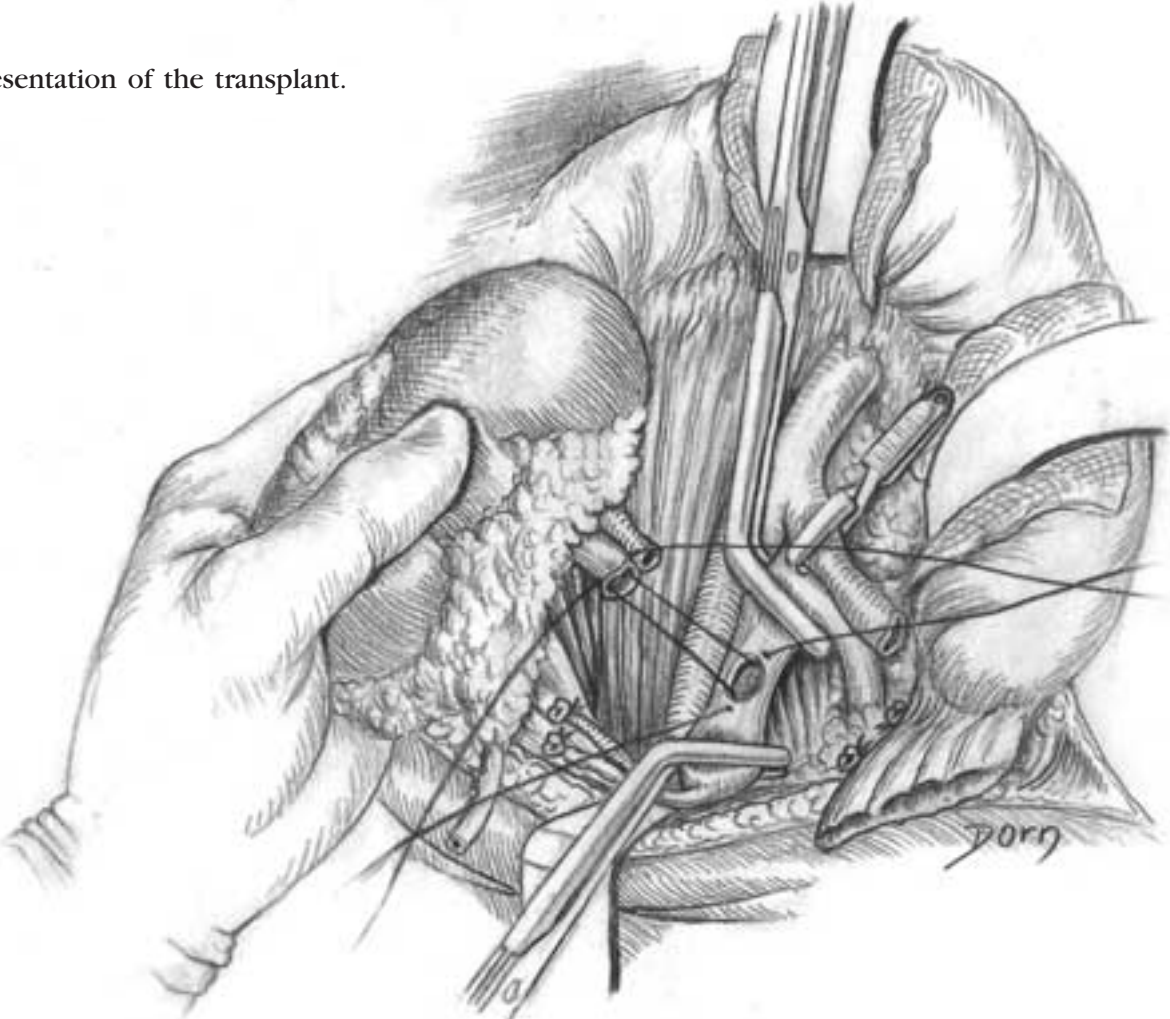
D Exposure of the division of the common iliac artery.



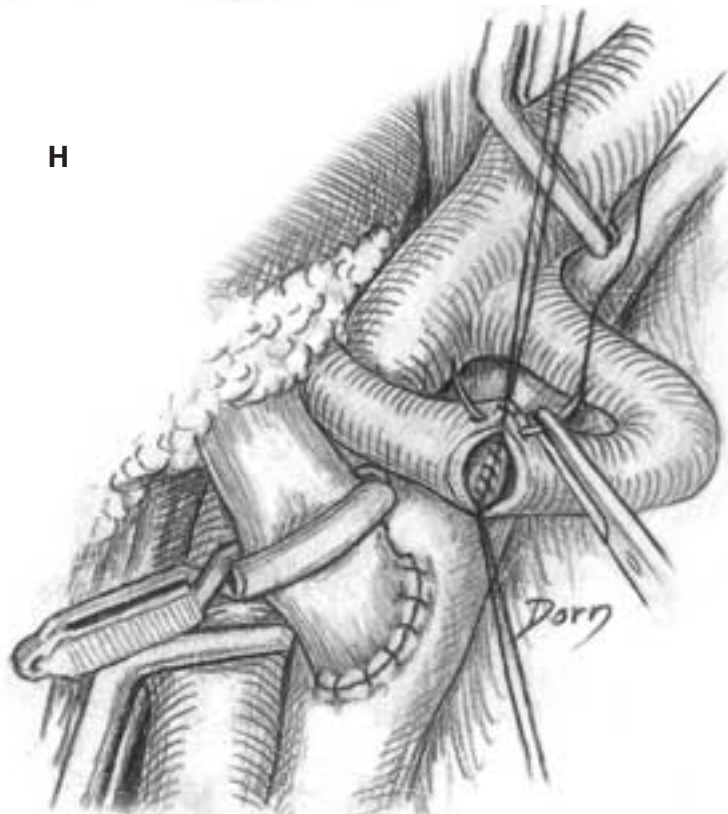
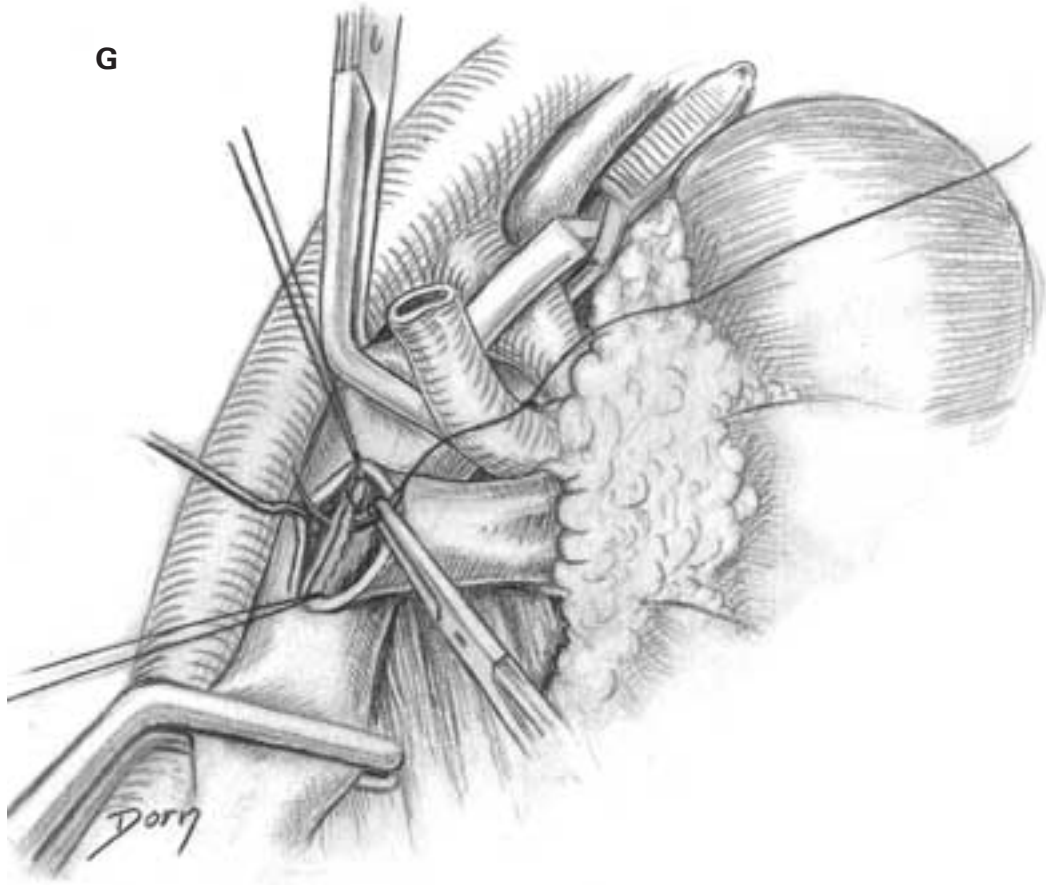
E Preparation of the recipient vein (external iliac vein).



F Presentation of the transplant.

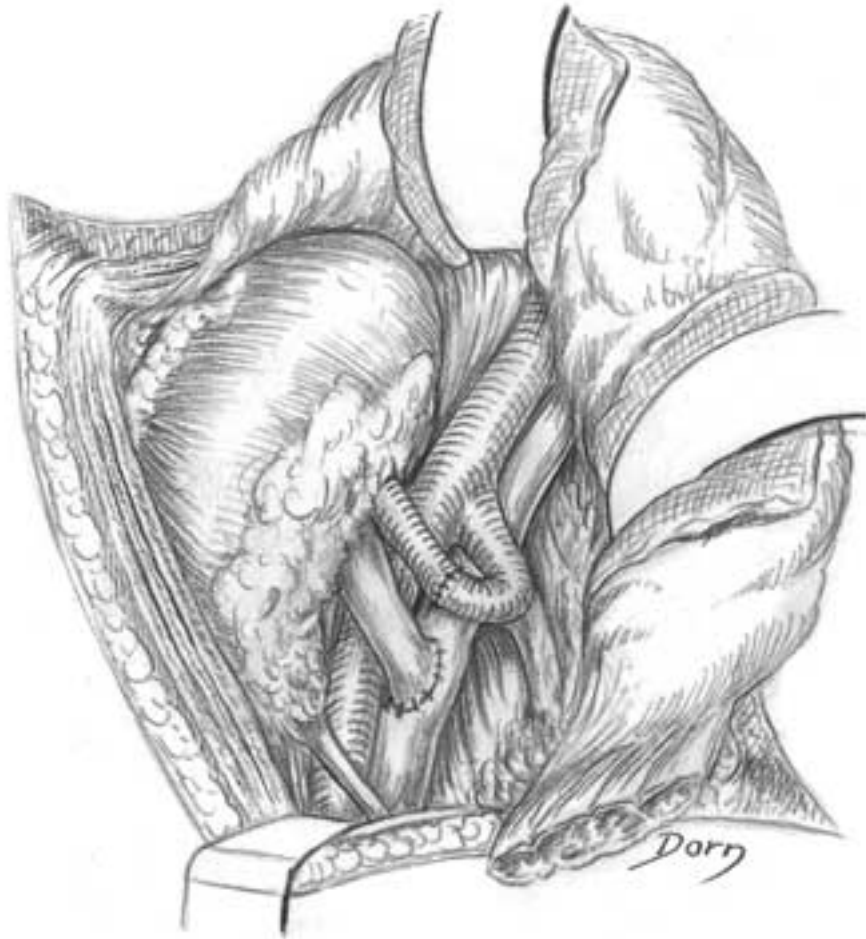


G, H Suturing the vessels. The first to be done is the anastomosis of the veins.



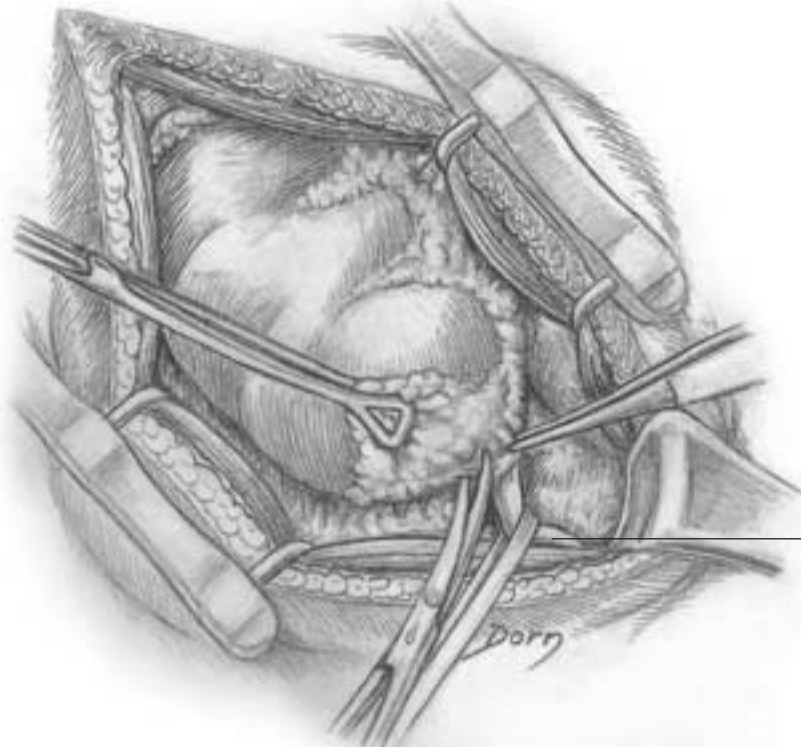
Urological surgery

I The final aspect of the vascular sutures. Then the ureter is reimplanted in the bladder.



Surgery of renal lithiasis

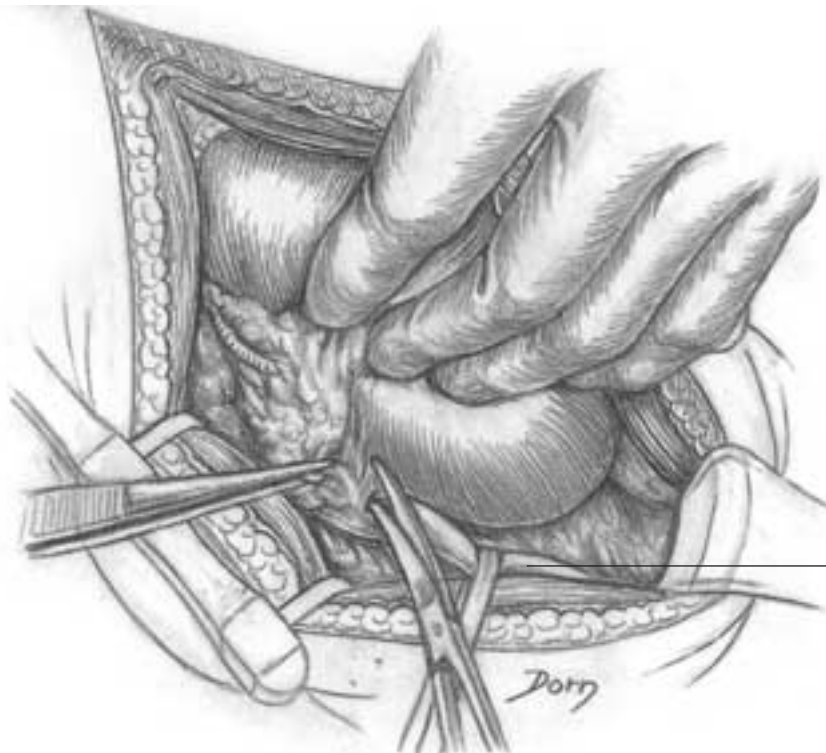
A The compartment of the kidney has been opened. The ureter is identified.



1

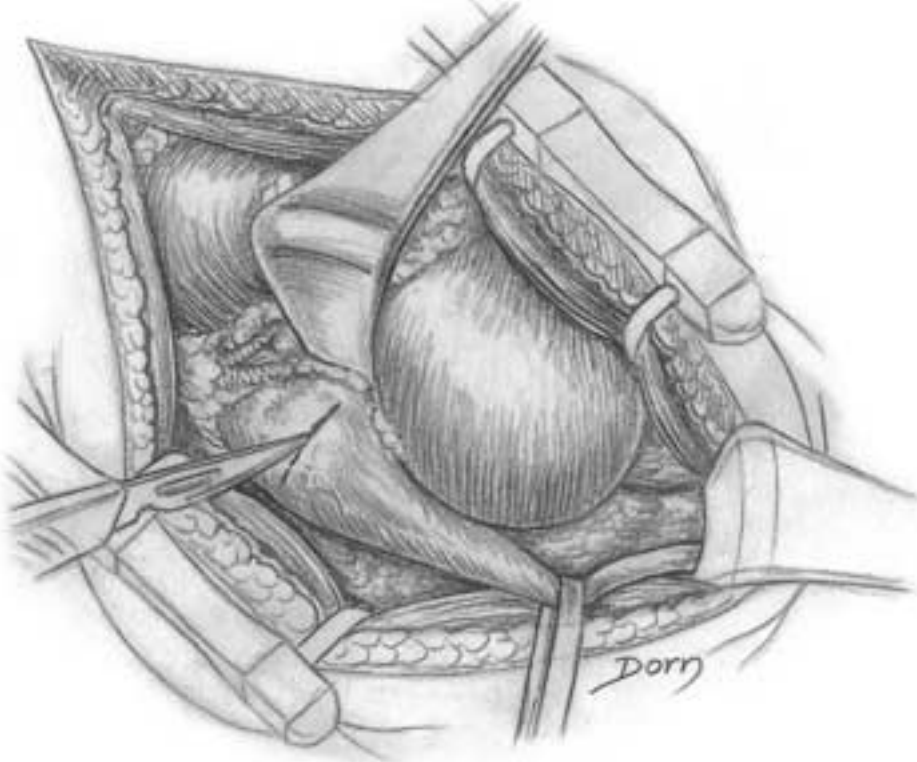
B Dissection of the ureter allows access to the renal pelvis.

1 ureter

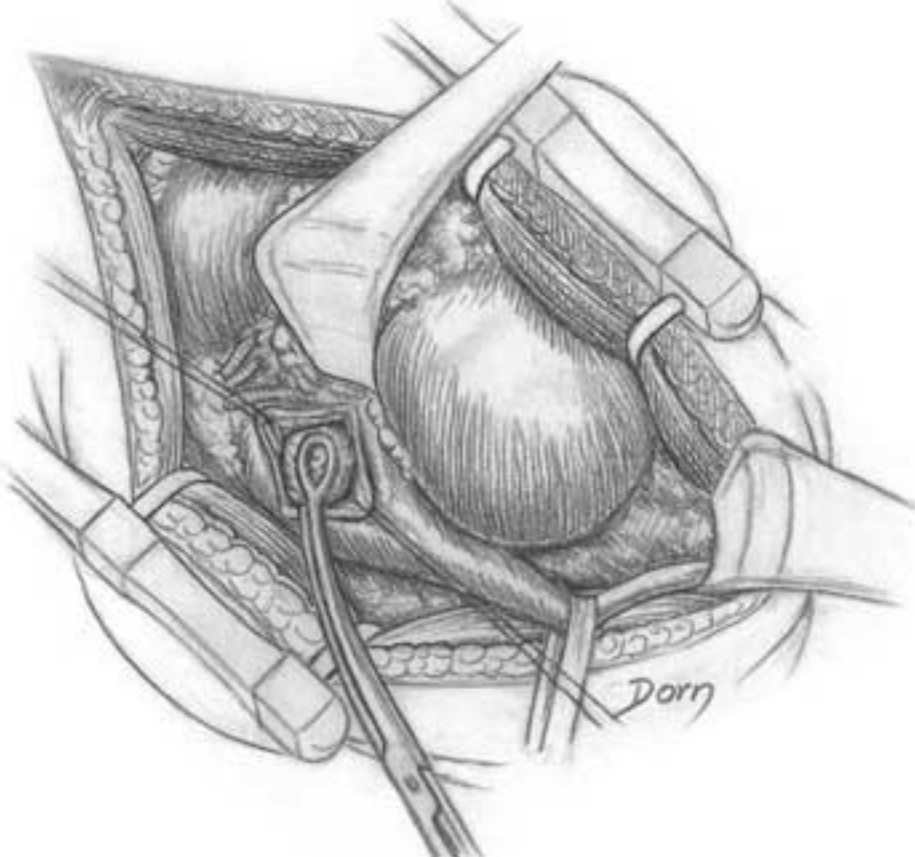


1

C Incision of the renal pelvis.

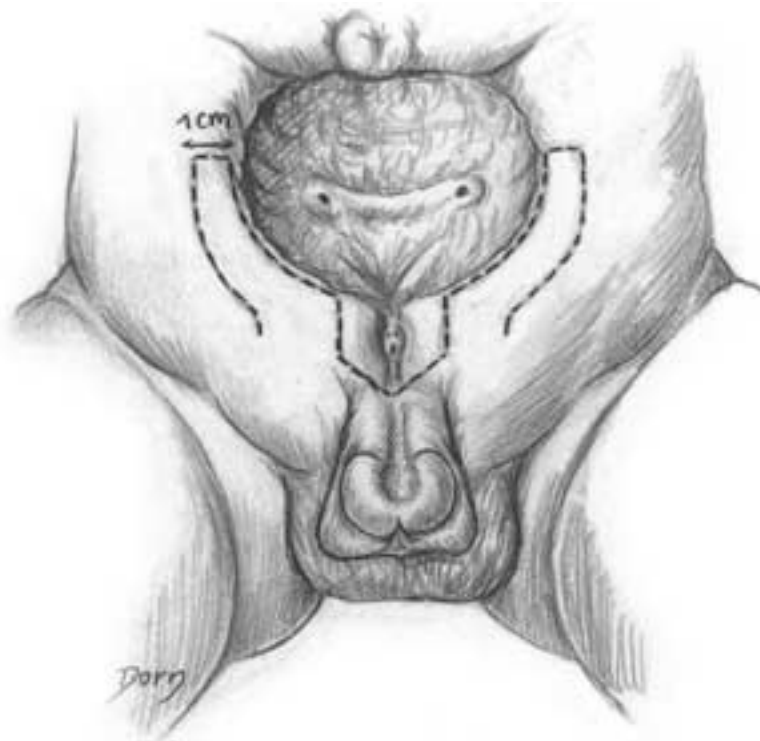


D Removing the lithiasis.

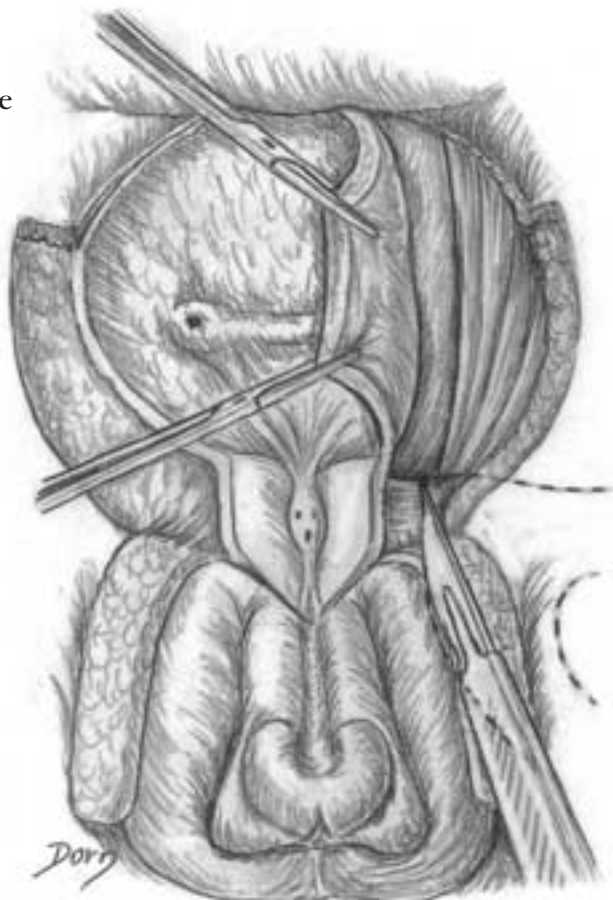

Extrophy of the bladder in a young boy

A The incisions. Two skin flaps are delineated.

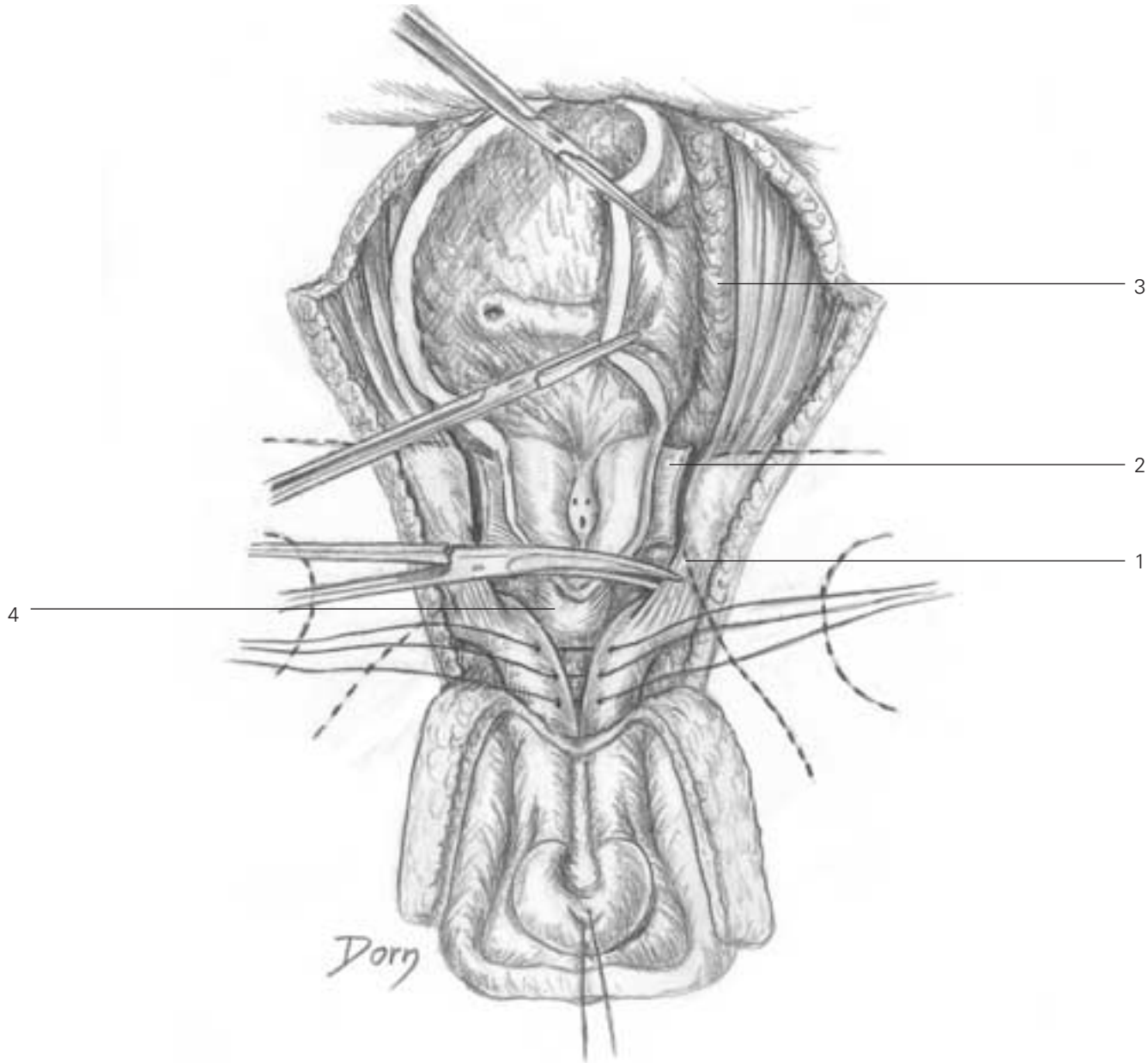


B The lateral aspects of the bladder are released.



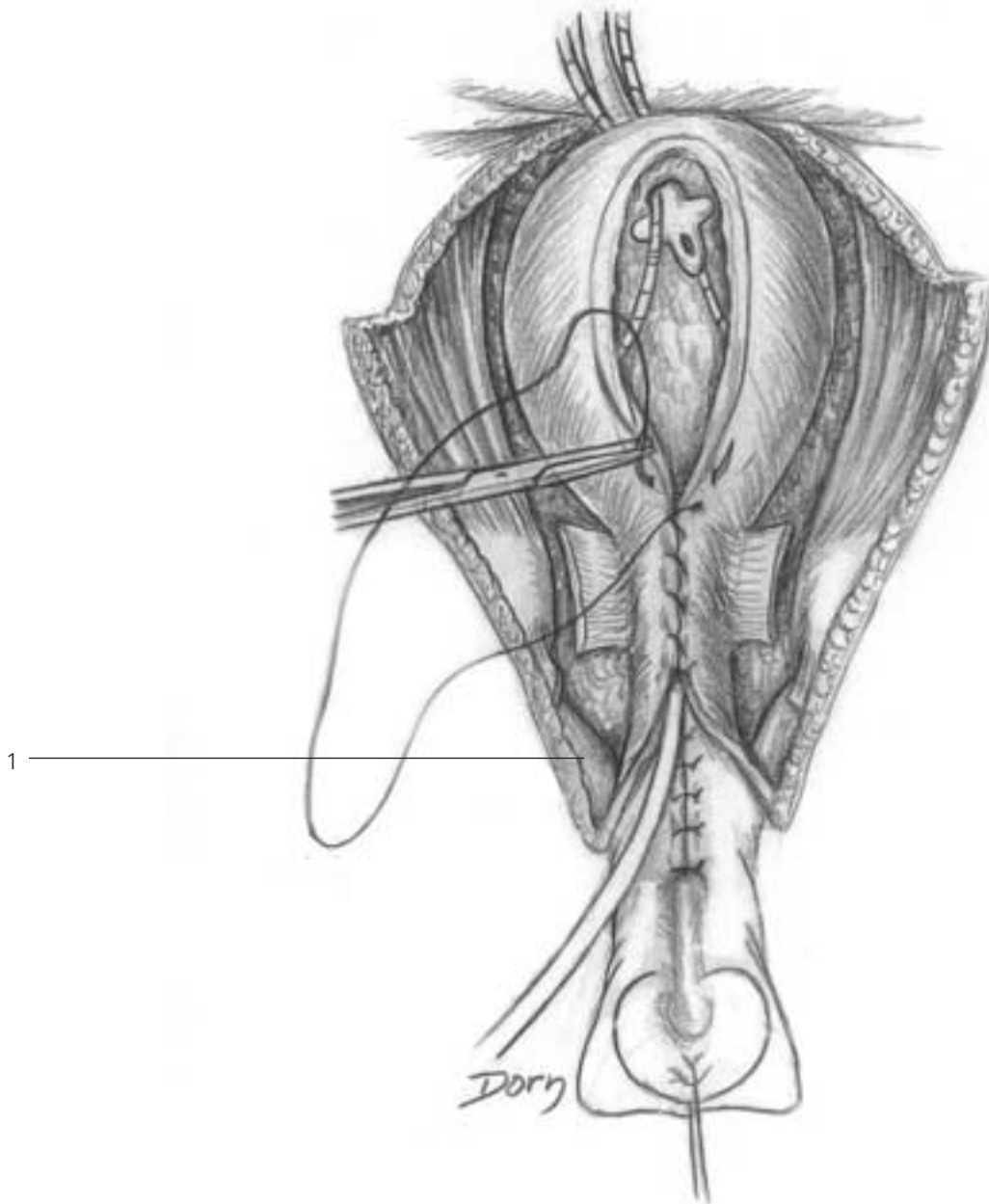
Urological surgery

C The penis is lengthened. The ischiocavernosus muscles are released.



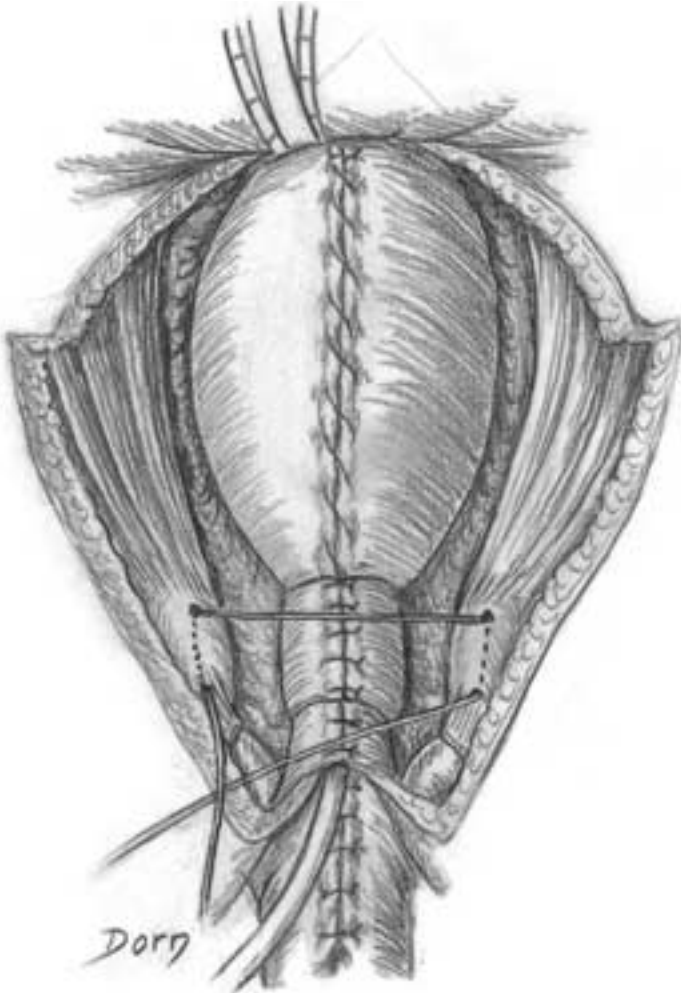
- C**
- 1 ischiocavernosus muscle
 - 2 transverse perineal ligament
 - 3 release of the posterior aspect of the bladder
 - 4 bulbospongiosus

D The urethra is lengthened by joining the two skin flaps and the bladder is sutured.

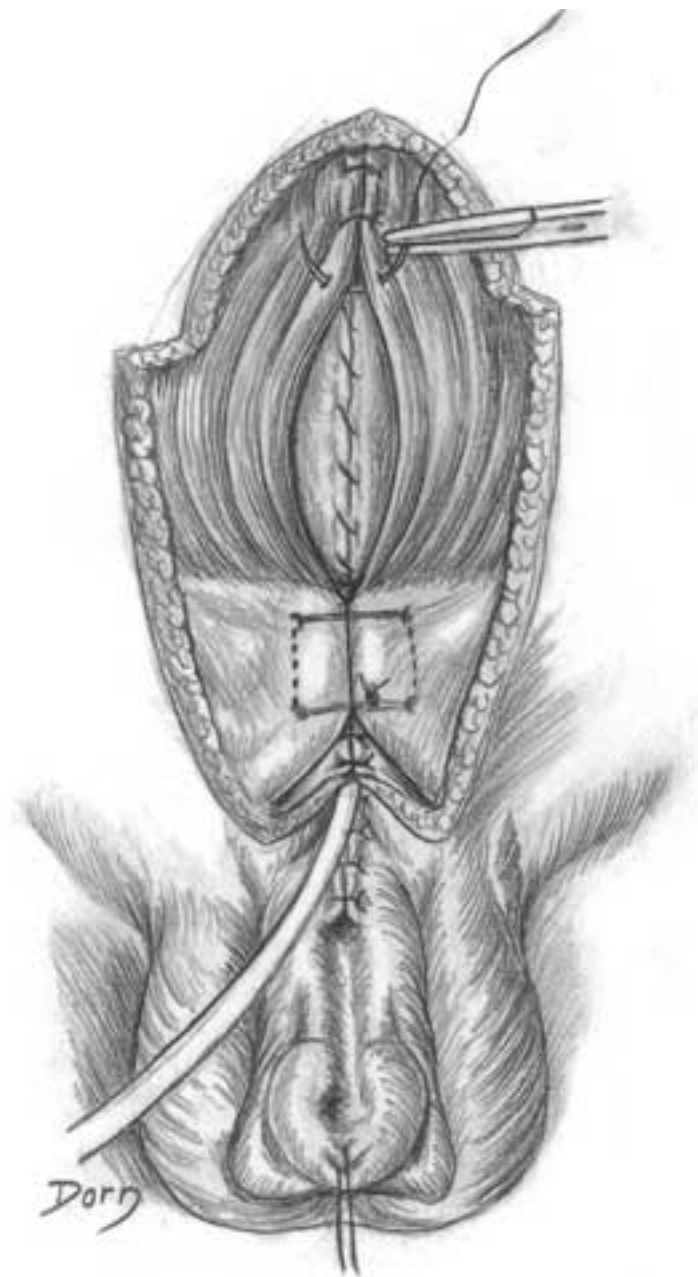


D
1 corpus cavernosus

E Closure of the bone frame.



F Closure of the muscular wall.



Urological surgery

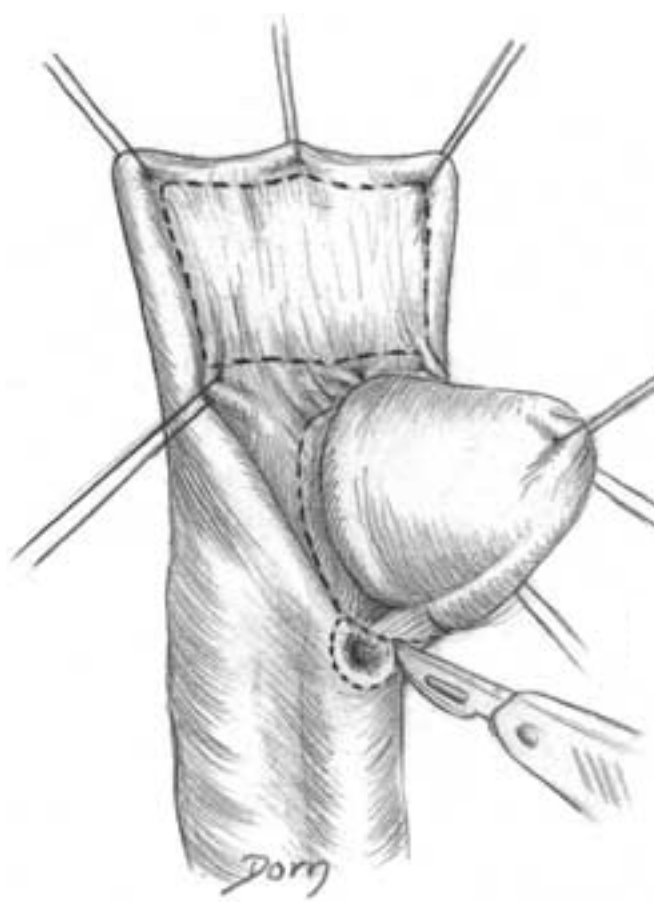
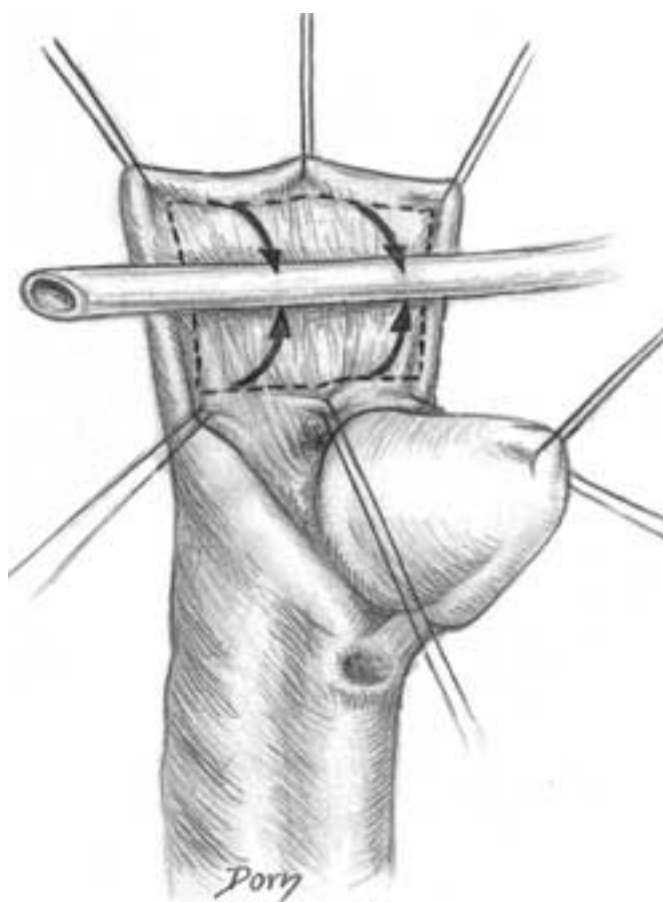
Hypospadias surgery

Hypospadias is a congenital malformation in which the external urethral meatus is not contained in the glans penis.

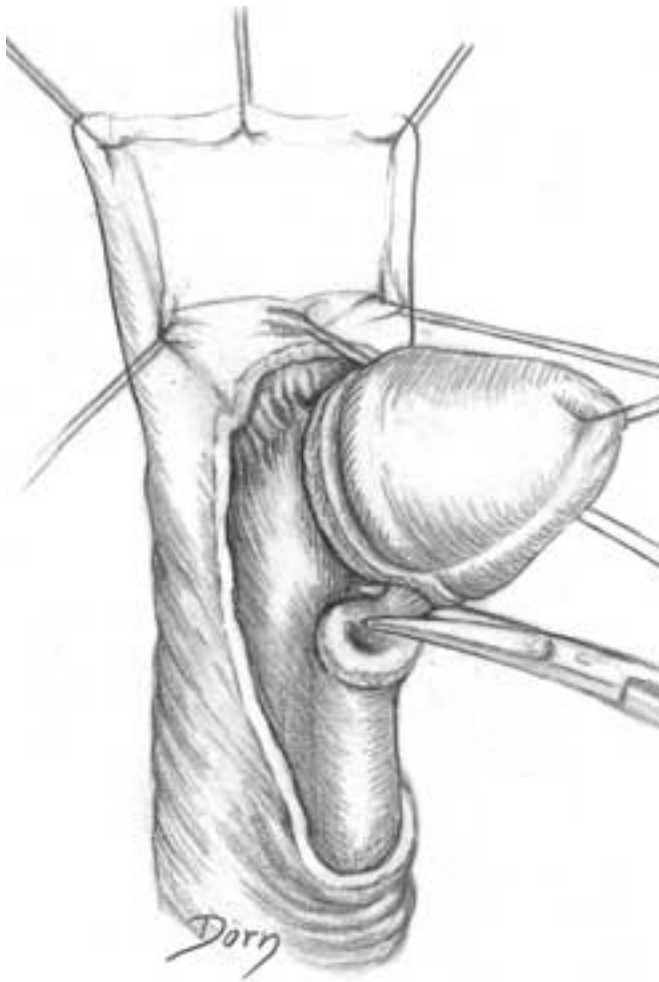
The aim of the operation is to reconstruct the distal portion of the urethra.

A The urethral canal will be reconstructed with a tubularised and pedicled preputial flap (mucosal aspect). Design of the incisions.

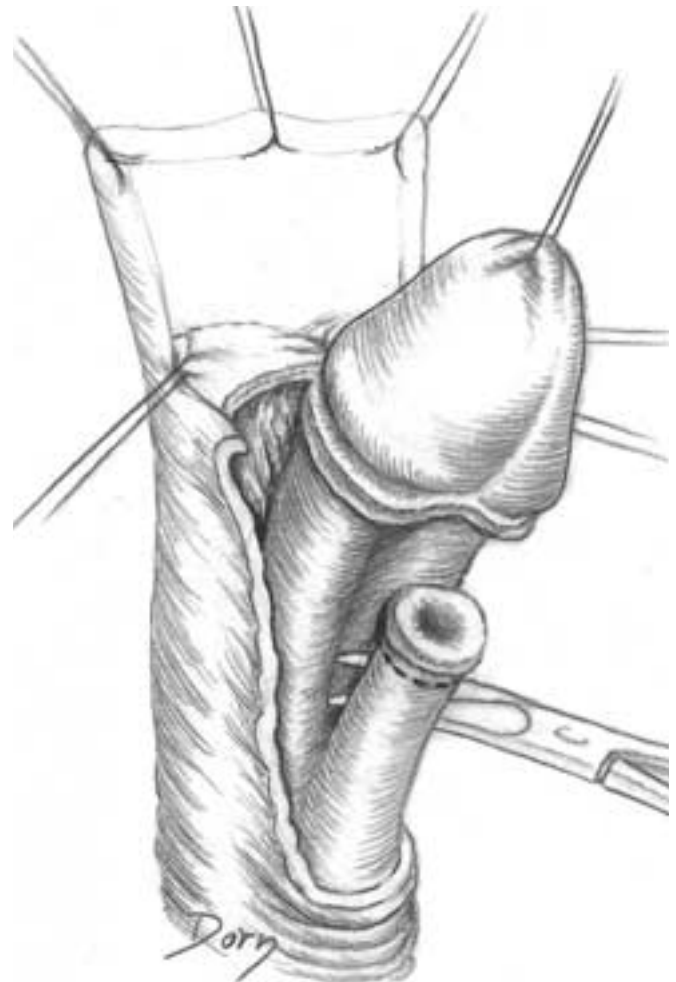
B Incision around the urethral meatus.



C Section of the retractile band responsible for the curvature of the penis.



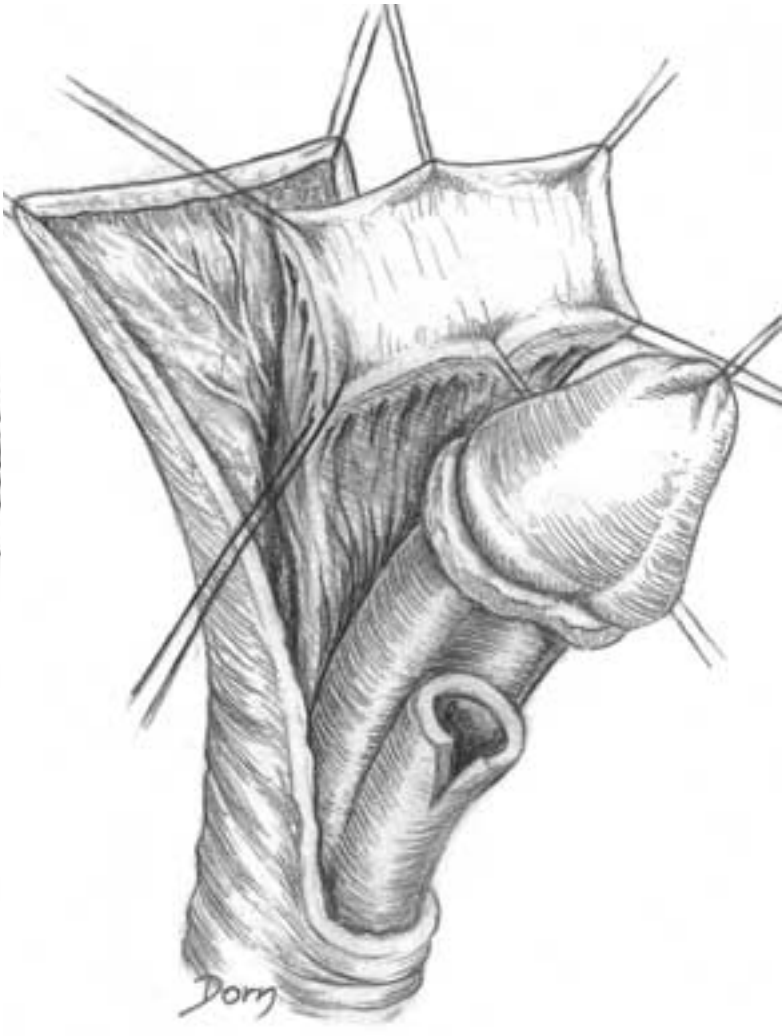
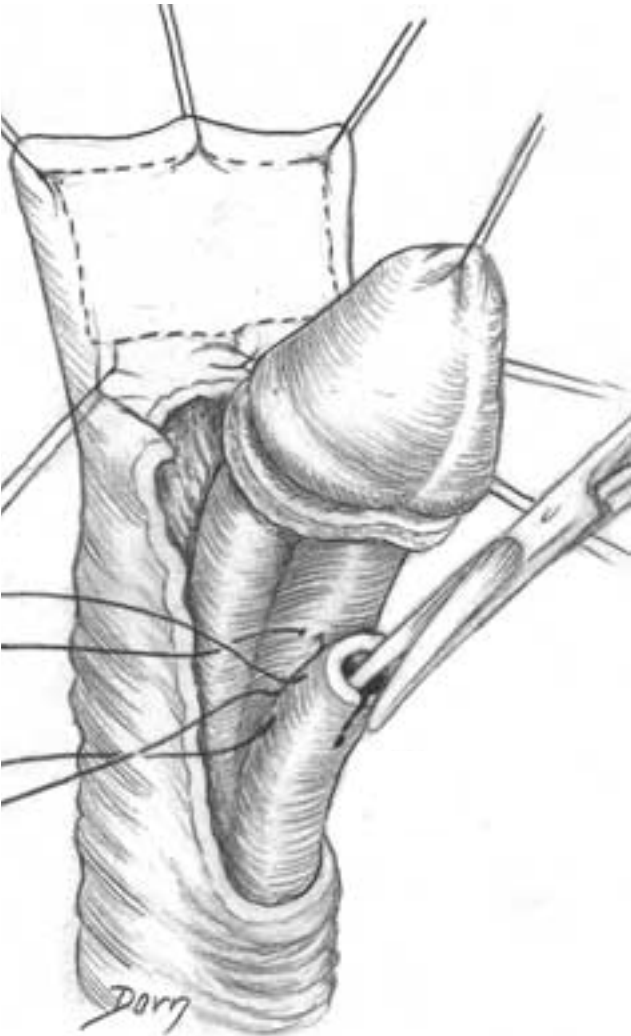
D Release of the urethra between the corpora cavernosa and the corpus spongiosum.



Urological surgery

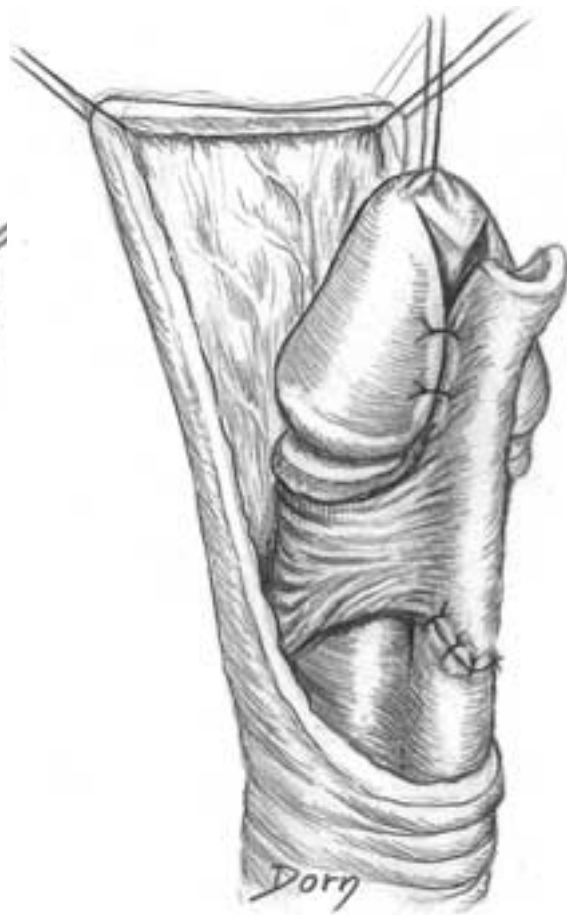
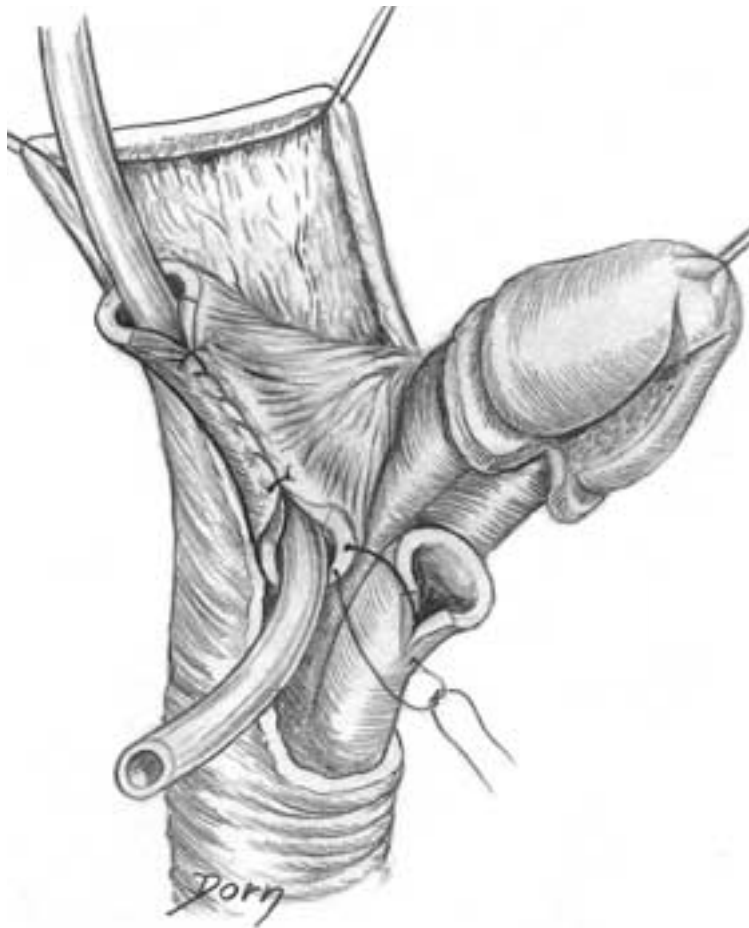
E Preparation of the urethra: excision of the meatus and the distal hypoplastic portion of the urethra; incision of the inferior aspect of the urethra and fixation of the dorsal aspect of the corpus spongiosum to the corpora cavernosa.

F The mucosal flap is isolated on its pedicle.



G Tubularisation of the flap. Note the trough in the glans to implant the neo-urethra.

H The reconstruction is covered by a skin flap.

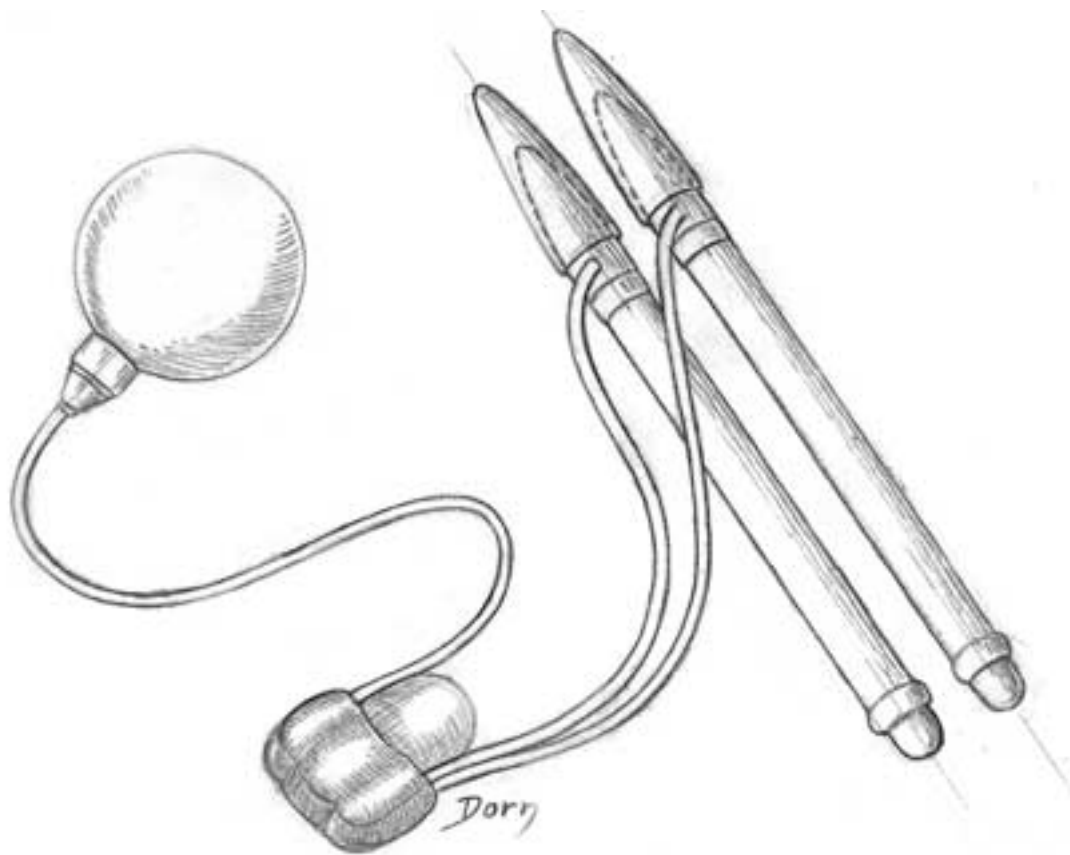


Urological surgery

Prosthesis for erectile function of penis

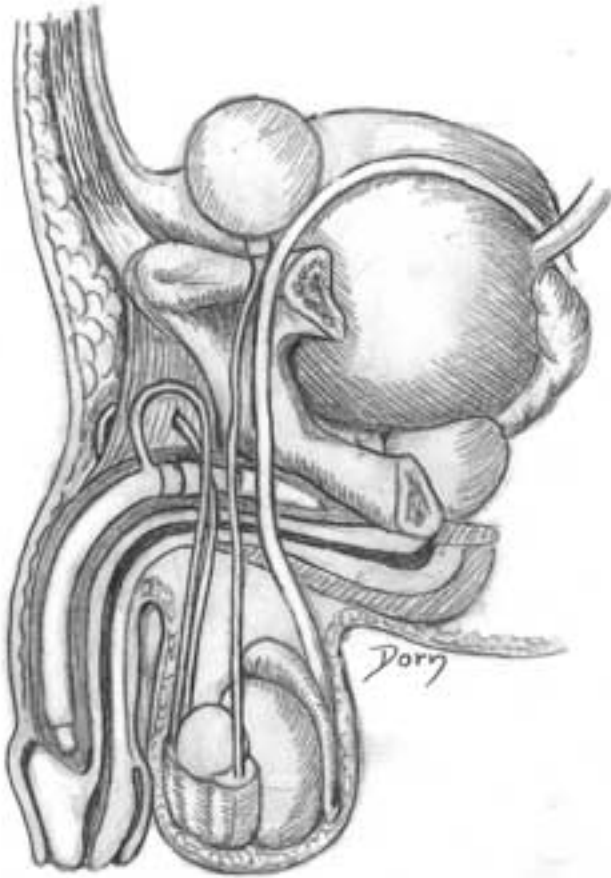
The principle is to obtain an artificial erection by inflating the corpora cavernosa of the penis. The glans penis cannot be erected by this prosthesis.

A Prosthesis of penis. It comprises a tank, a pump and two inflatable cylinders which will be placed in the corpora cavernosa.

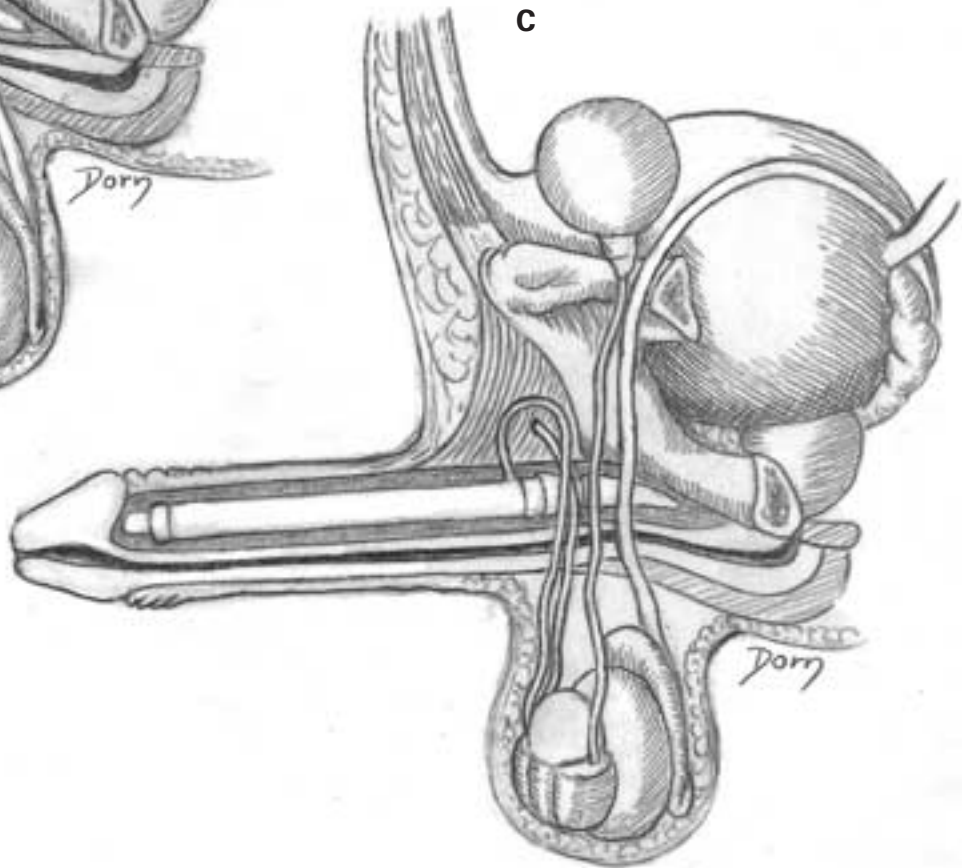


B, C The prosthesis in the flaccid state and in erection. The tank is placed in Retzius' space while the pump is in the scrotum.

B



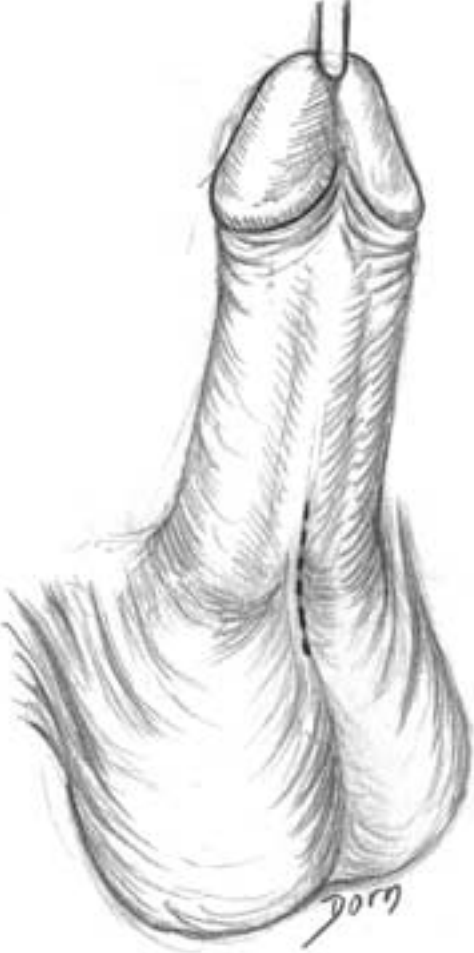C



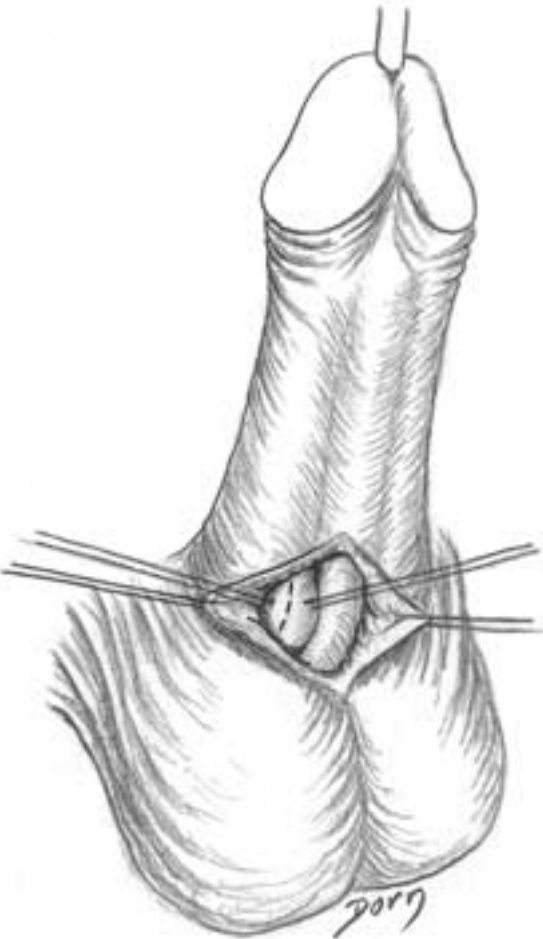
Urological surgery

D-G Surgical procedure. Incision of the corpus cavernosum and dilation.

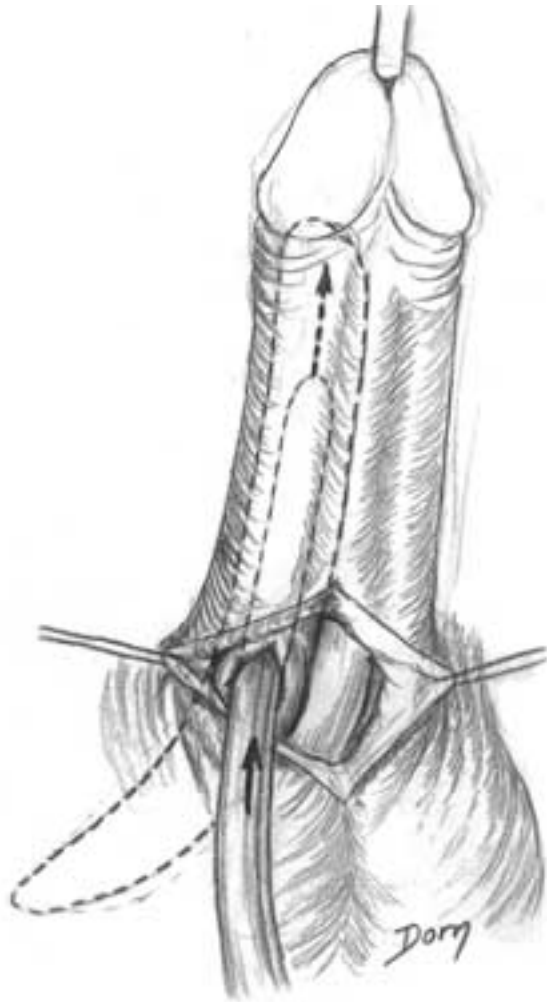
D



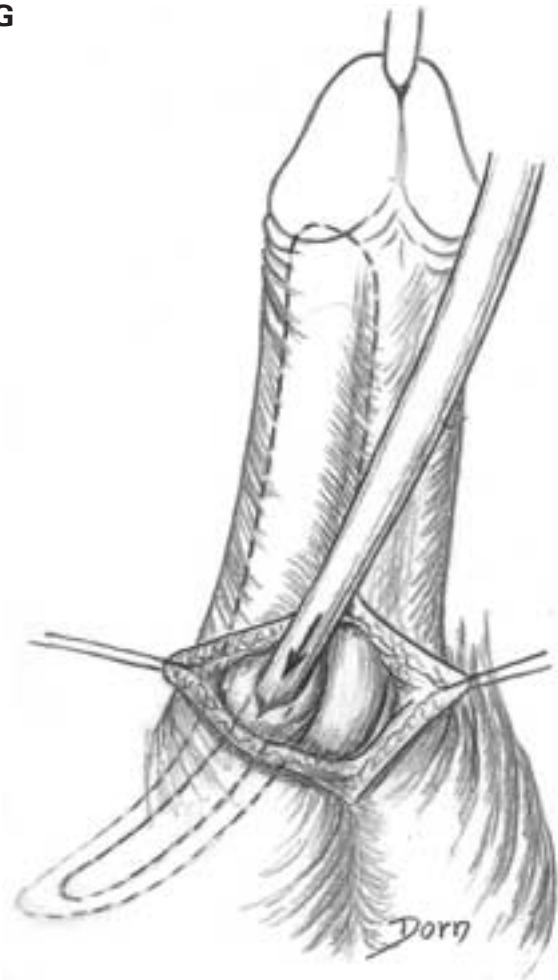
E



F



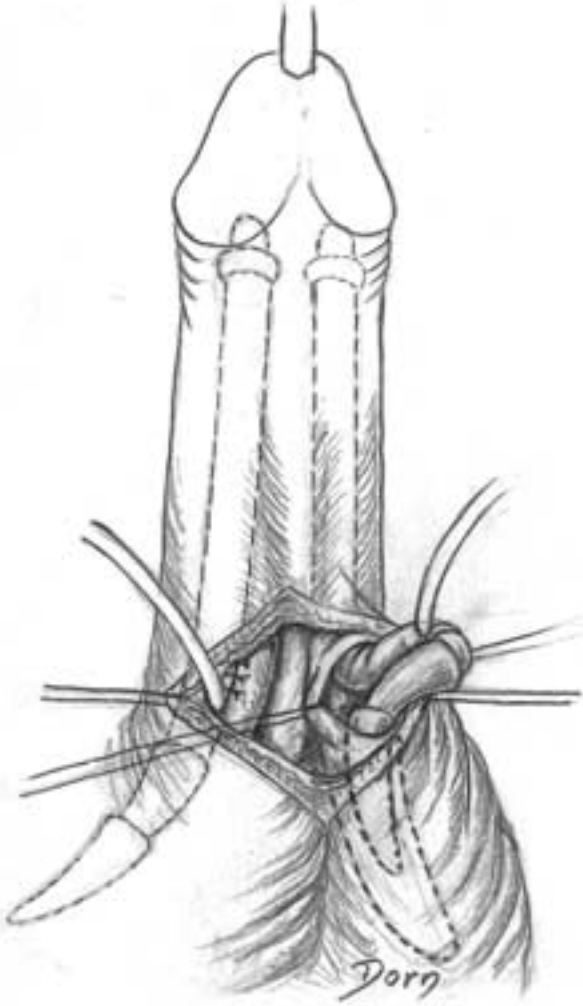
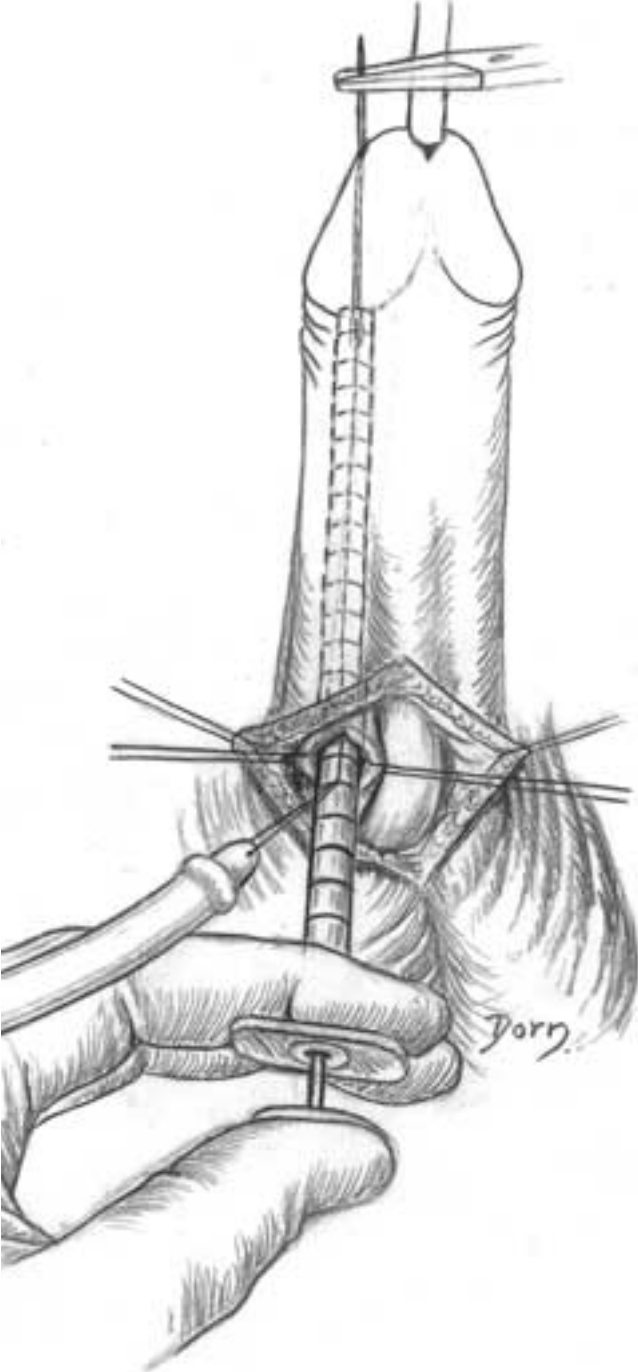
G



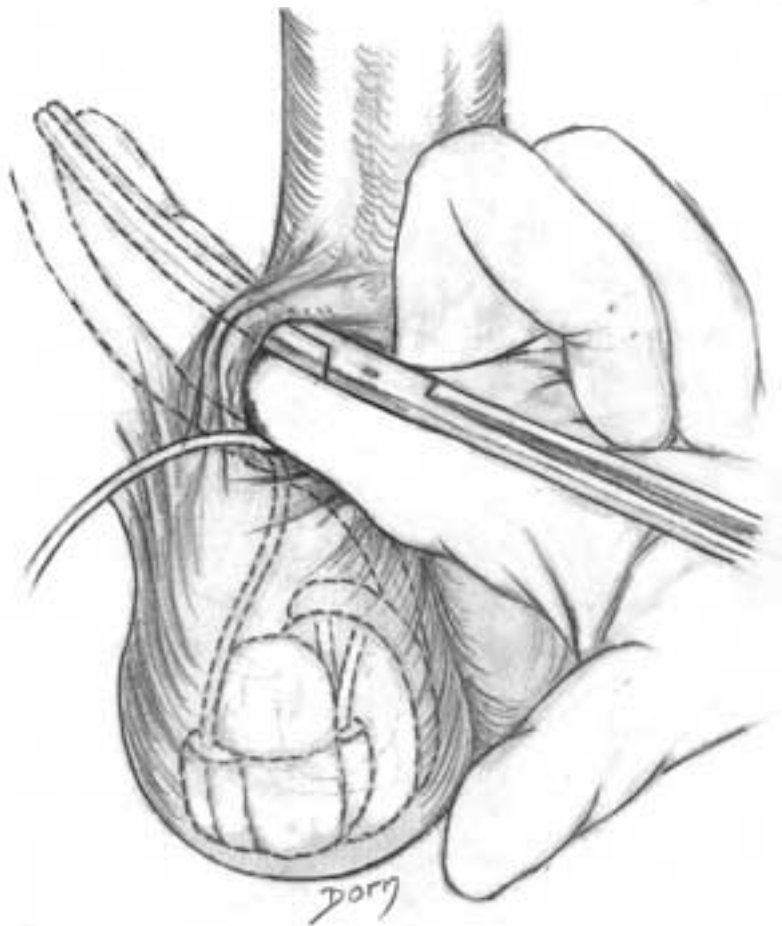
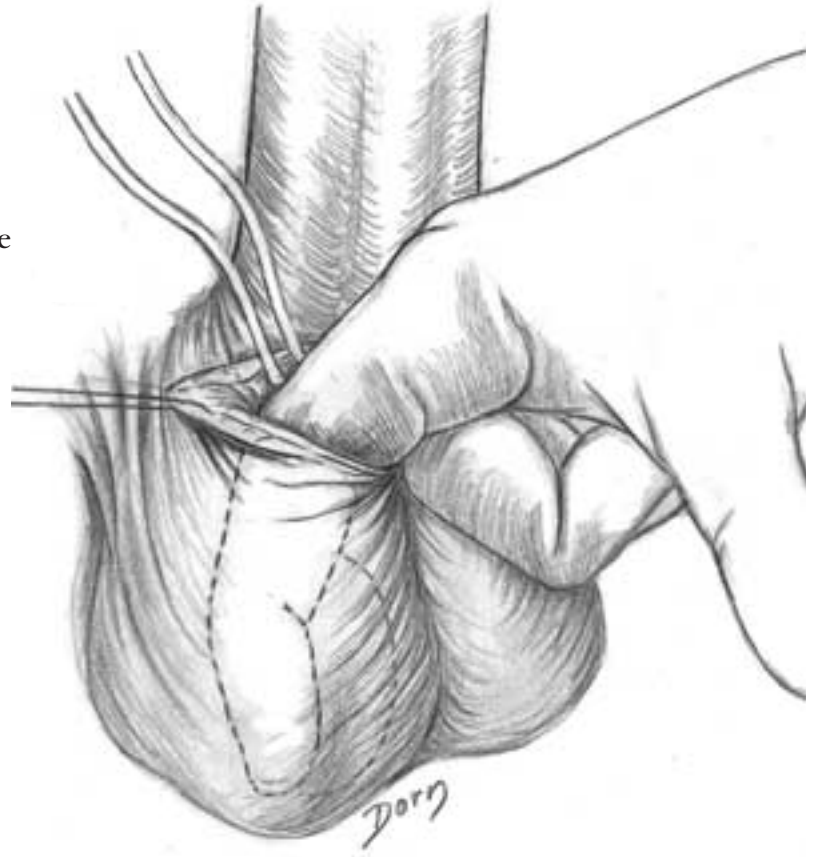
Urological surgery

H A needle with a thread is passed through the glans, which permits lifting up the cylinder to put it in right place.

I The same procedure is performed on the other corpus cavernosum.



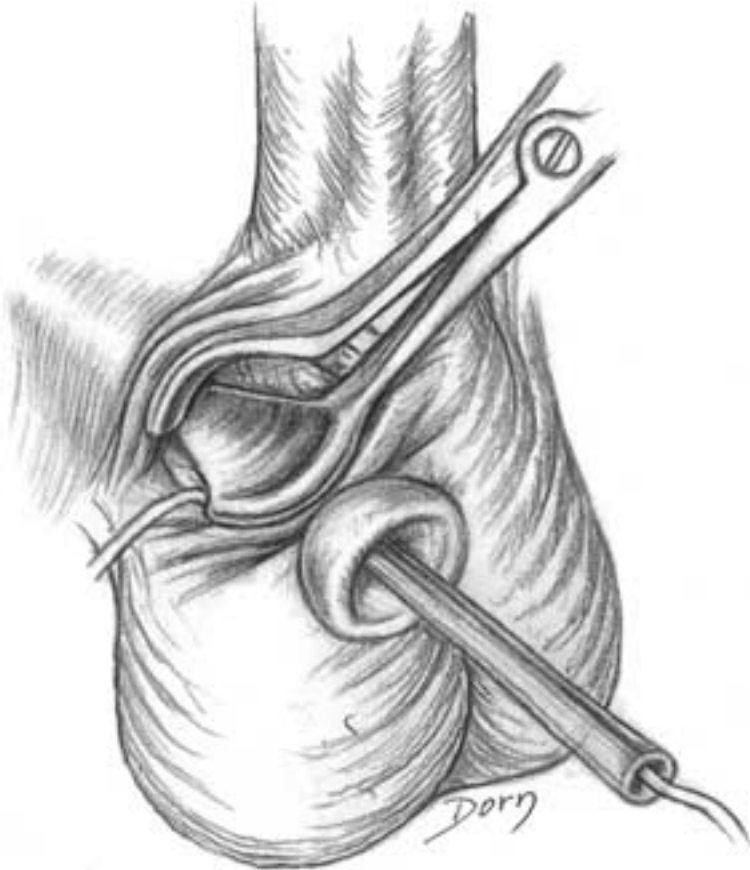
J A tunnel is made in the scrotum to place the pump.



K A tunnel is made to give access to Retzius' space (for the tank).

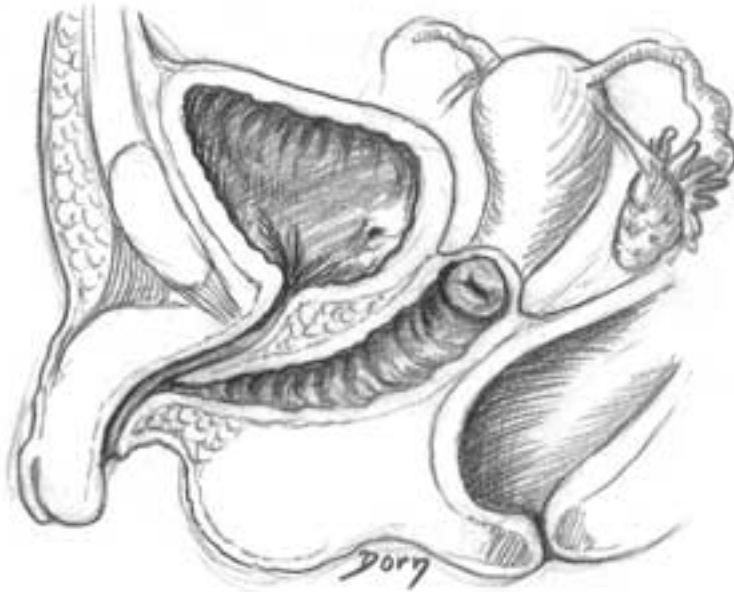
Urological surgery

L The tank is introduced with a small speculum.

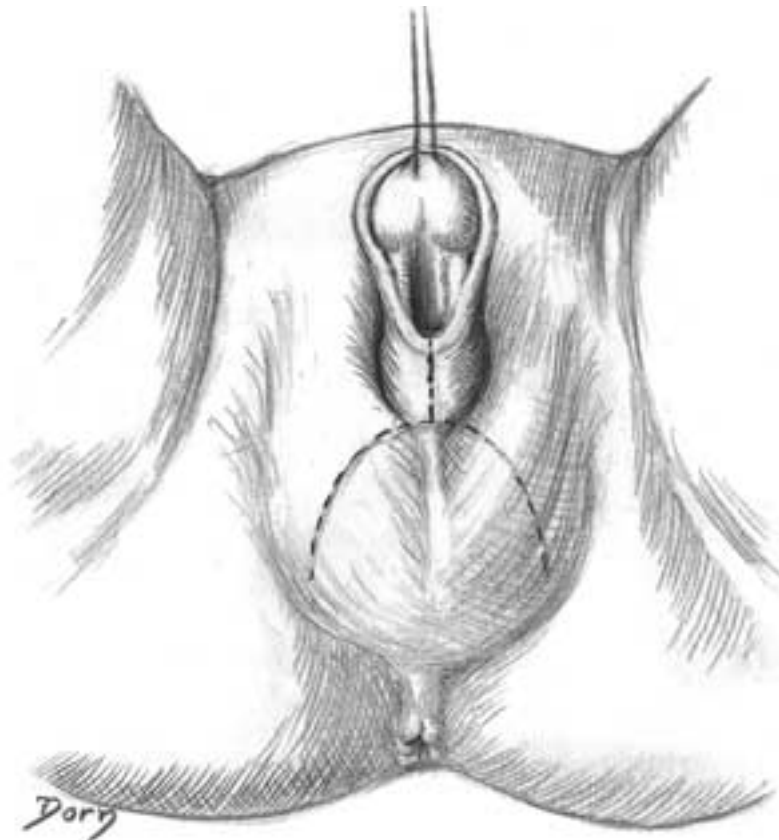


Amputation of the penis for sexual ambiguity: feminisation

A Diagrammatic representation of sexual ambiguity. Note the short urogenital sinus.

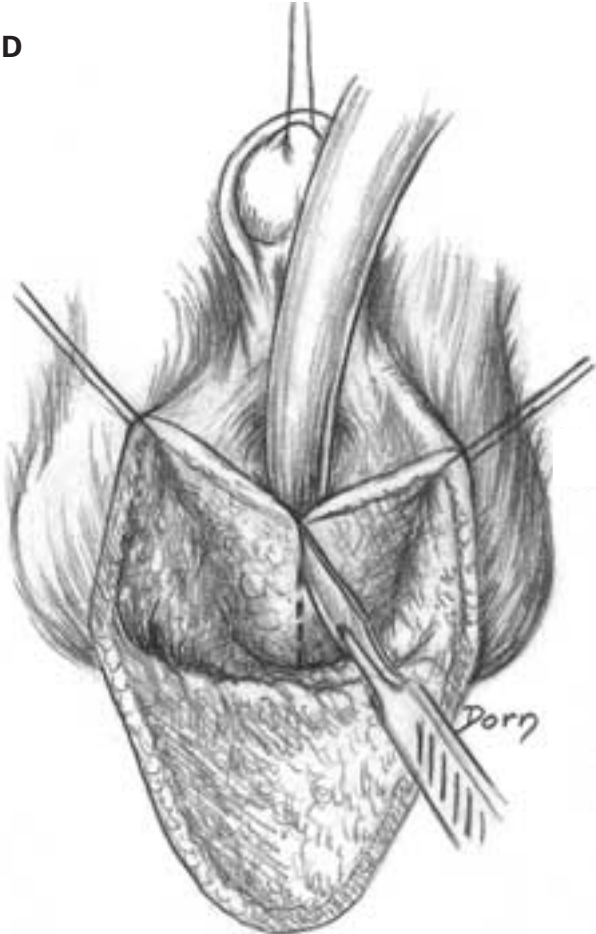
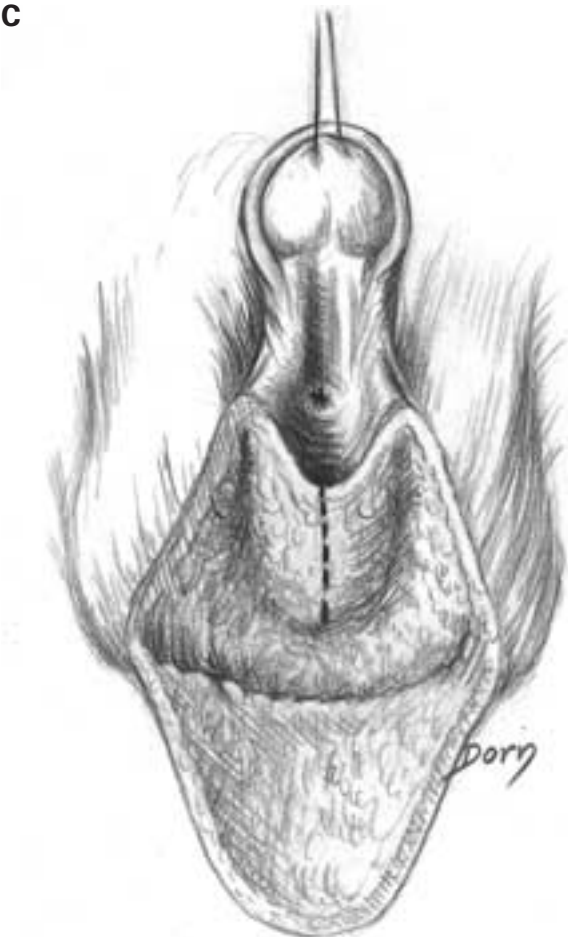

B Vagina plasty and plasty of the labia. The skin incision permits raising a large flap with a posterior hinge.



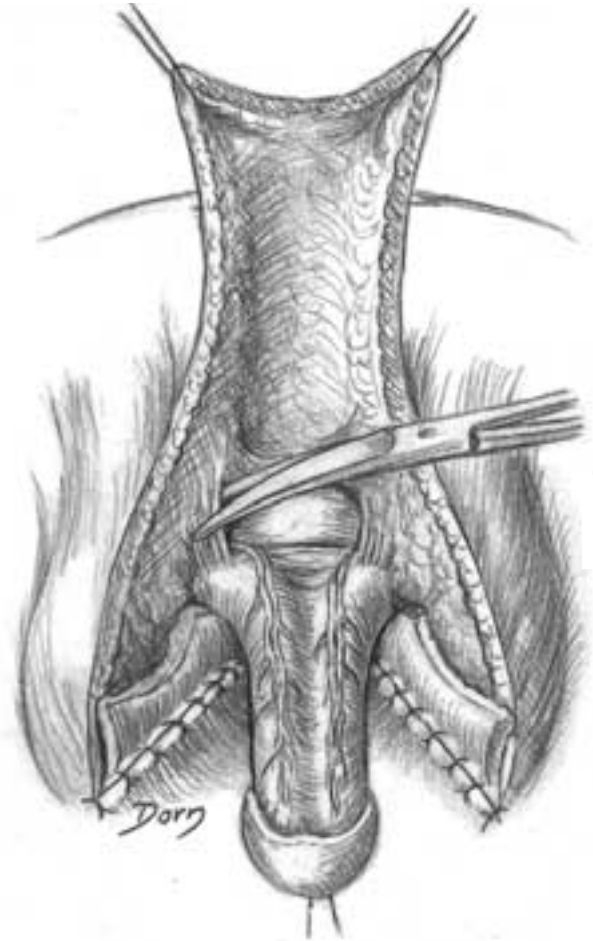
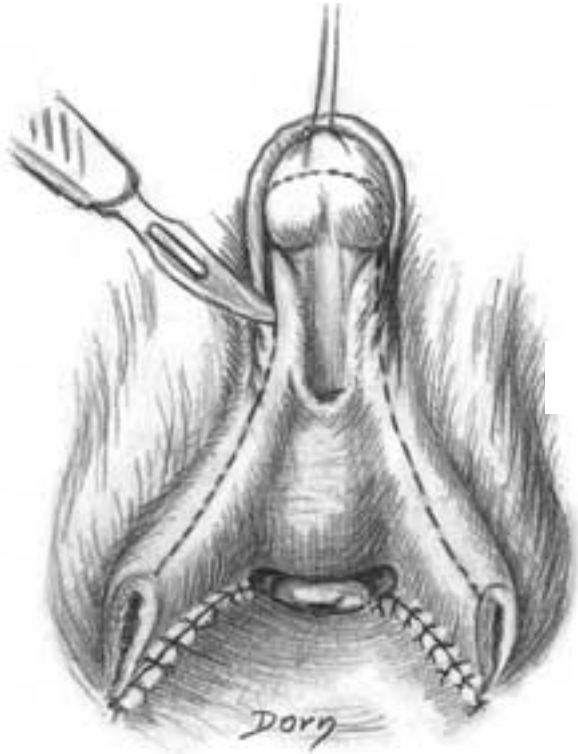Urological surgery

C, D Incision in the posterior aspect of the urogenital sinus.



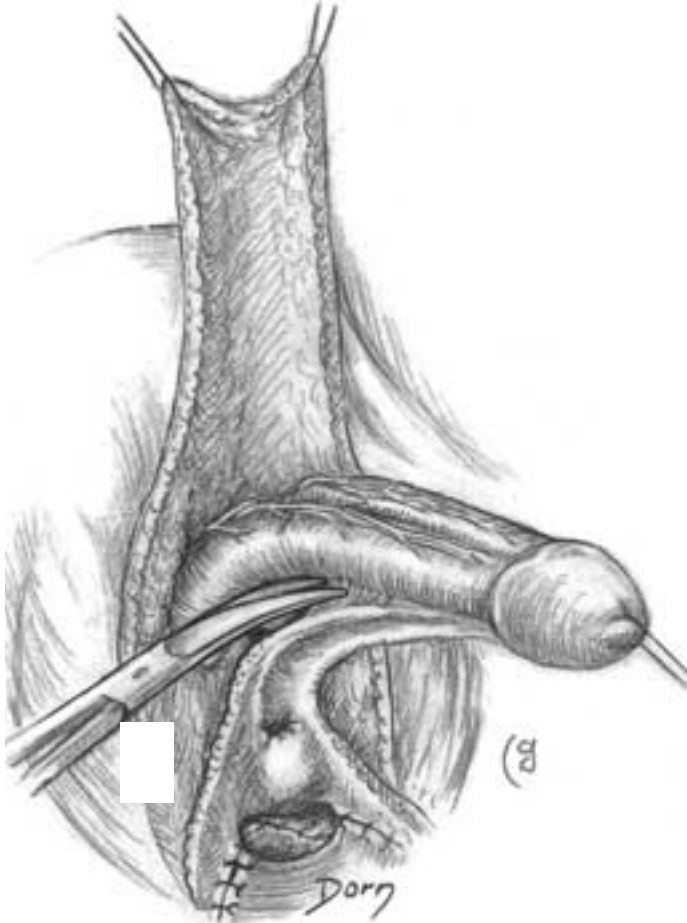
E The skin flap is inserted in the posterior aspect of the urogenital sinus (which has been incised). Incisions to prepare the plasty of the labia, the clitoris and the prepuce of the clitoris.

F Complete release of the penis; which will become the clitoris organ.

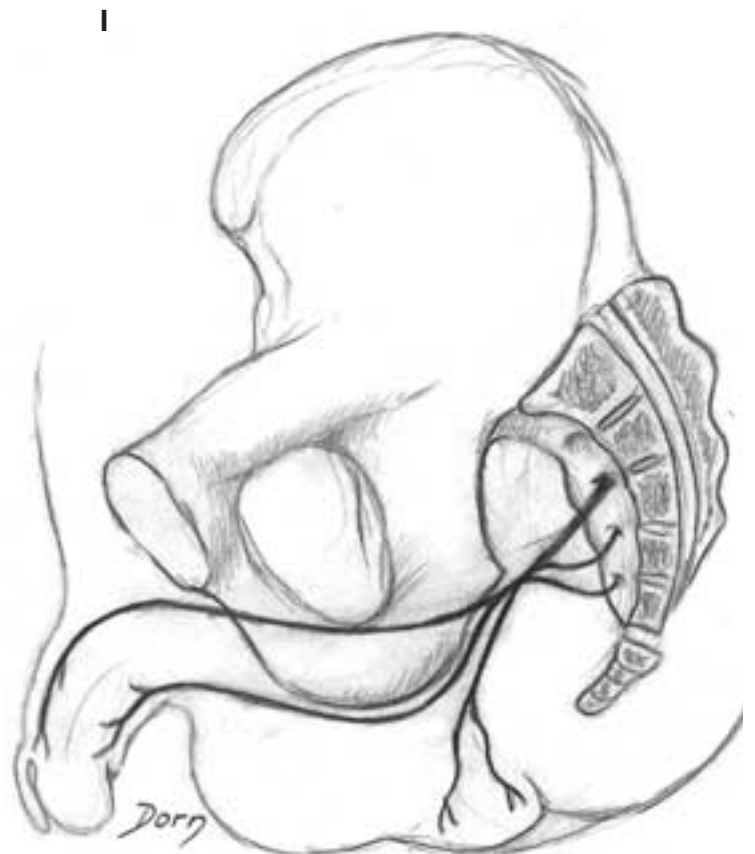
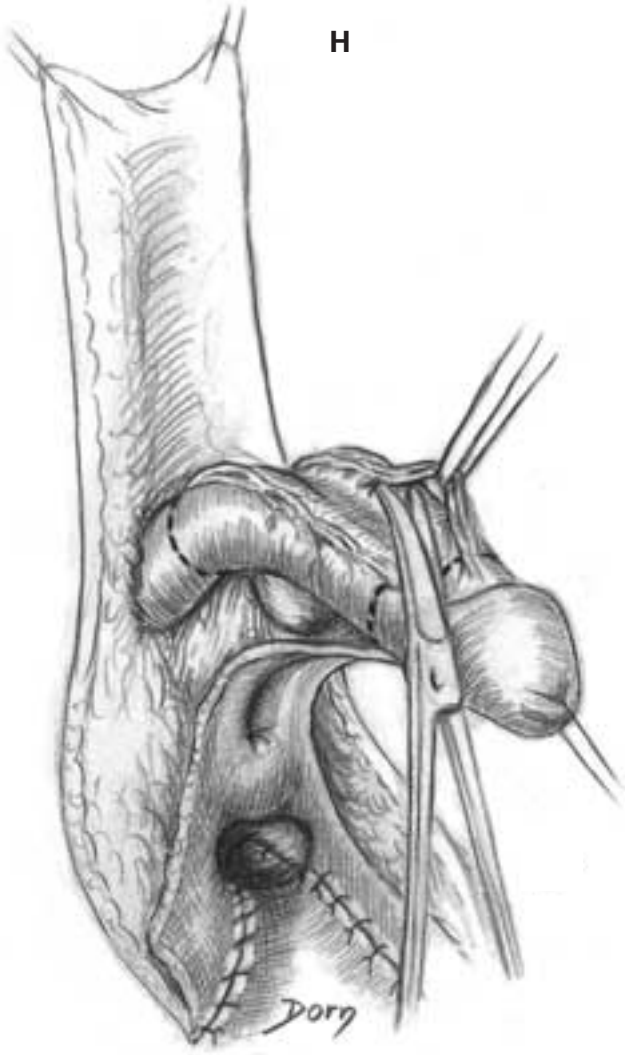


Urological surgery

G Release of the ventral aspects of the corpora cavernosa.



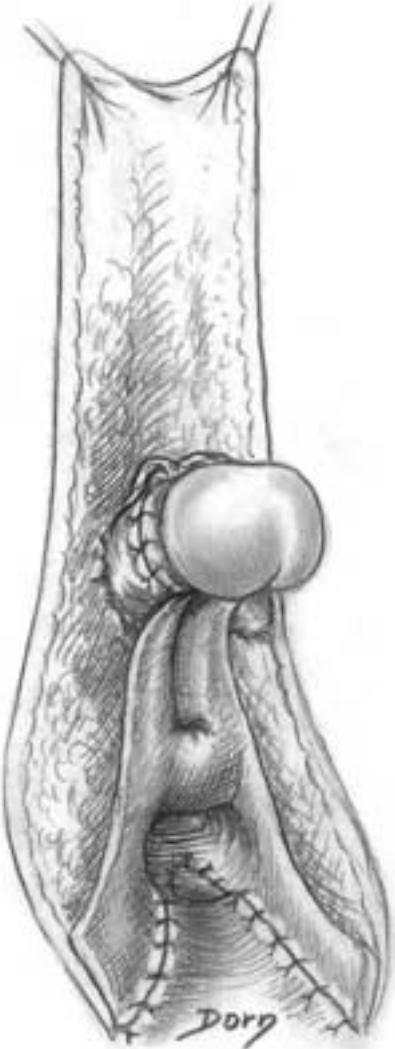
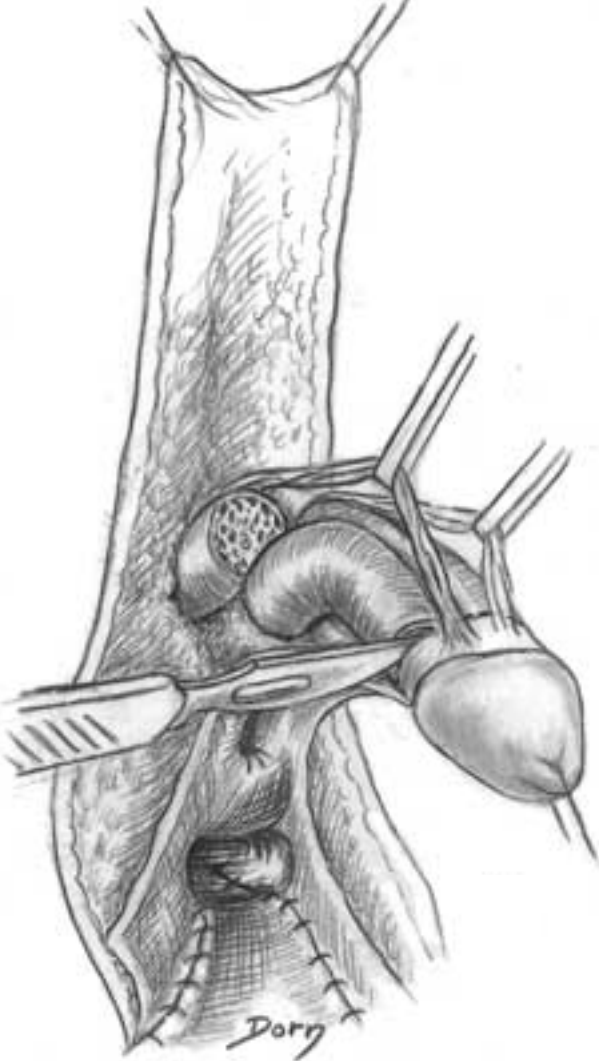
H Plasty of the clitoris. Dissection of the dorsal neurovascular pedicle for the (future) clitoris. **I** Origin of the nerves.



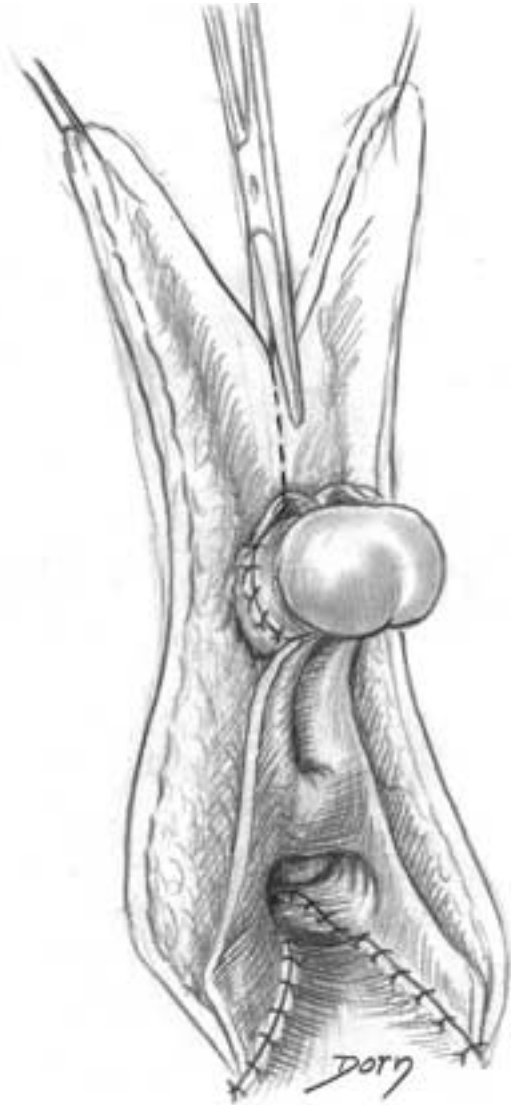
Urological surgery

J Excision of the major portions of the corpora cavernosa, taking care of the neurovascular pedicles which supply the glans.

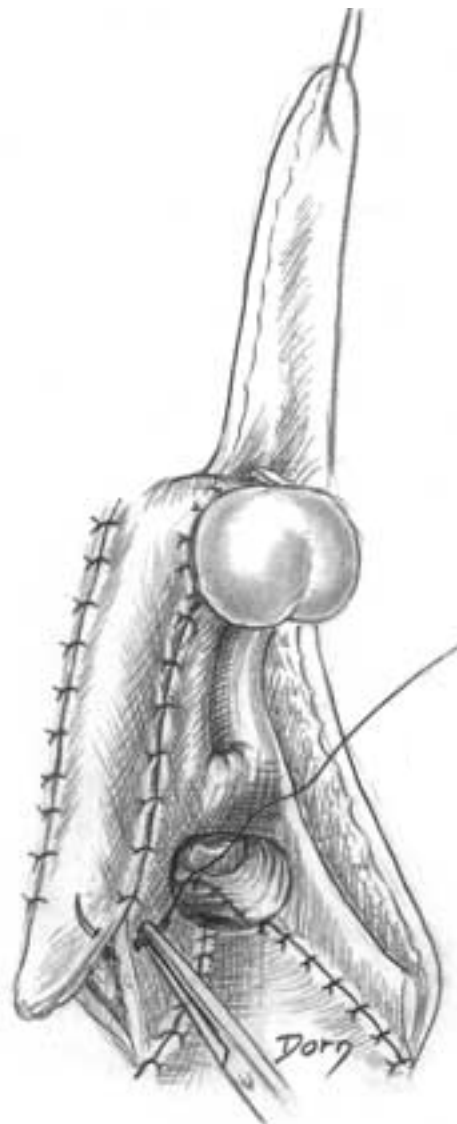
K Suture. The penis is shortened to obtain a clitoris.



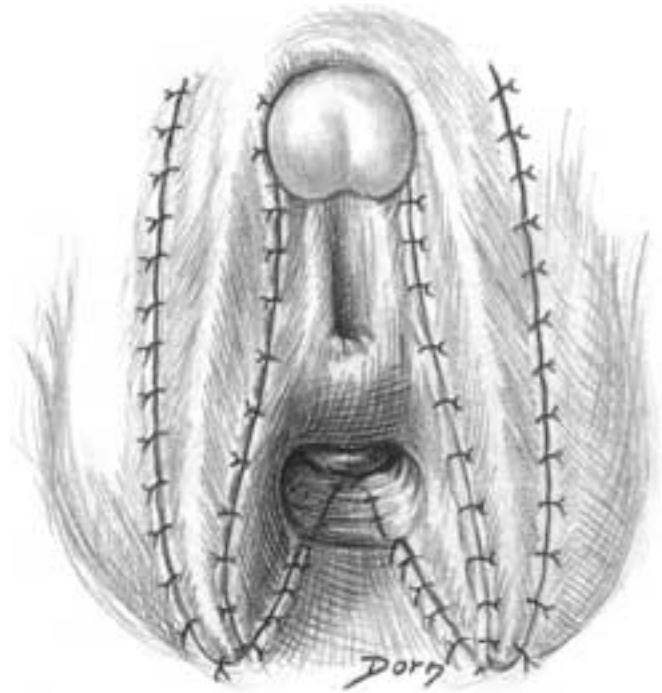
L Plasty of the labium minus.



M Reconstruction of the labium majus and labium minus.



N Final aspect.



Abdominal surgery

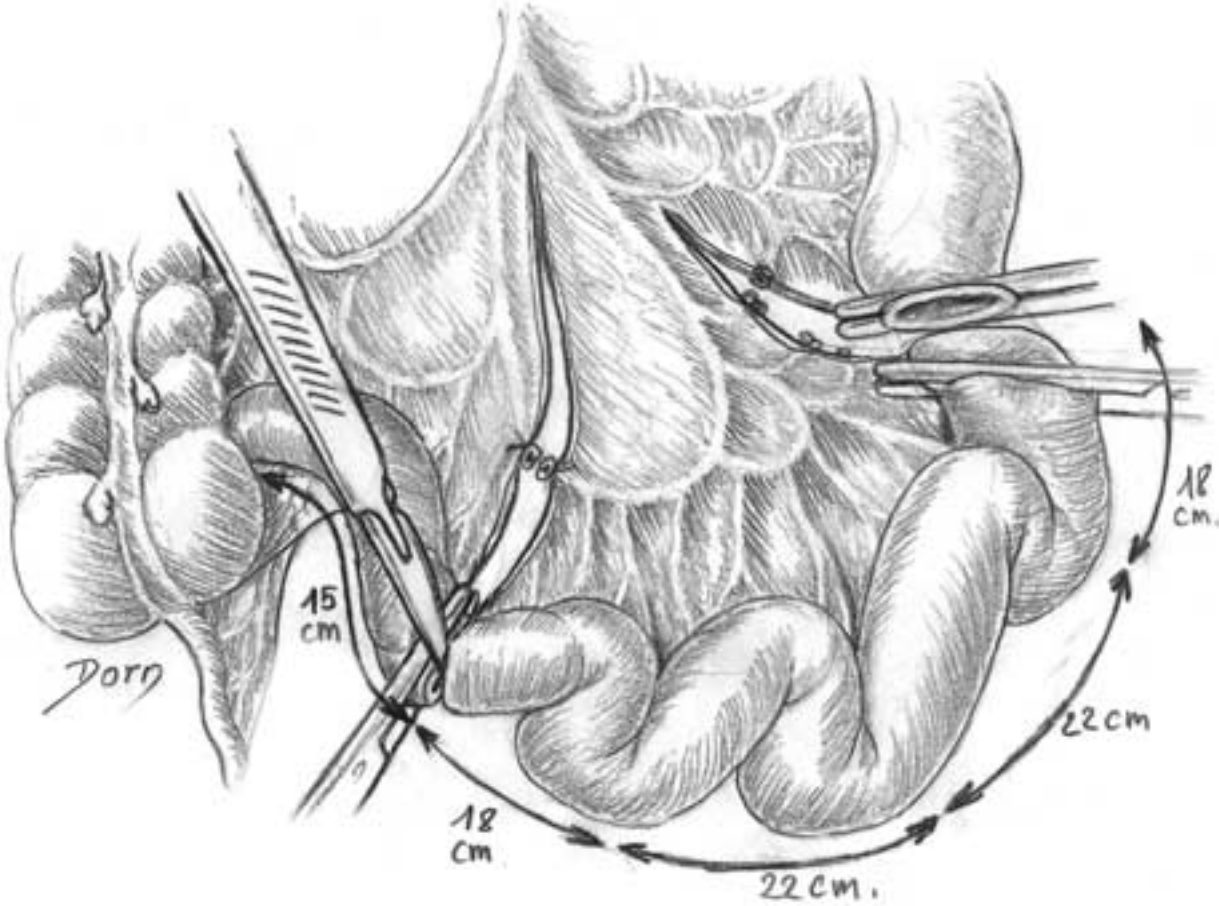
The following series of illustrations is devoted to surgery of the abdominal viscera. The organs of the abdomen can be removed in case of tumour-like cancer; they can also be used in palliative procedures to reconstruct another organ which has been removed. The ileum, which is the distal portion of the small intestine, is not absolutely indispensable for normal physiology; it is routinely employed to replace a missing bladder.

Great advances have been made in liver surgery recently, particularly in the field of transplantation. The division of the liver into segments is based upon ramification of bile ducts and hepatic vessels and does not entirely correspond with division into lobes. Segmental resections are of major interest in traumatology and surgery of liver tumours. One of the main recent advances is the possibility of transferring a lobe from the liver of a living donor to replace an entire liver in a recipient patient.

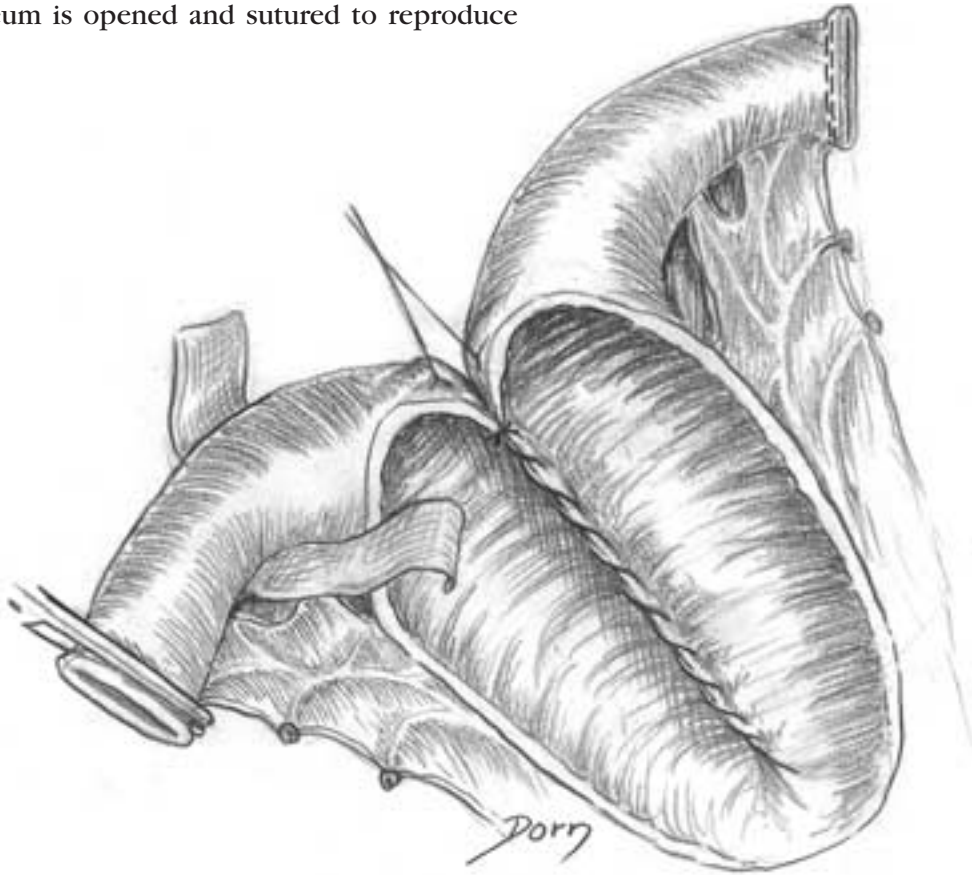
Abdominal surgery

Reconstruction of a urinary bladder

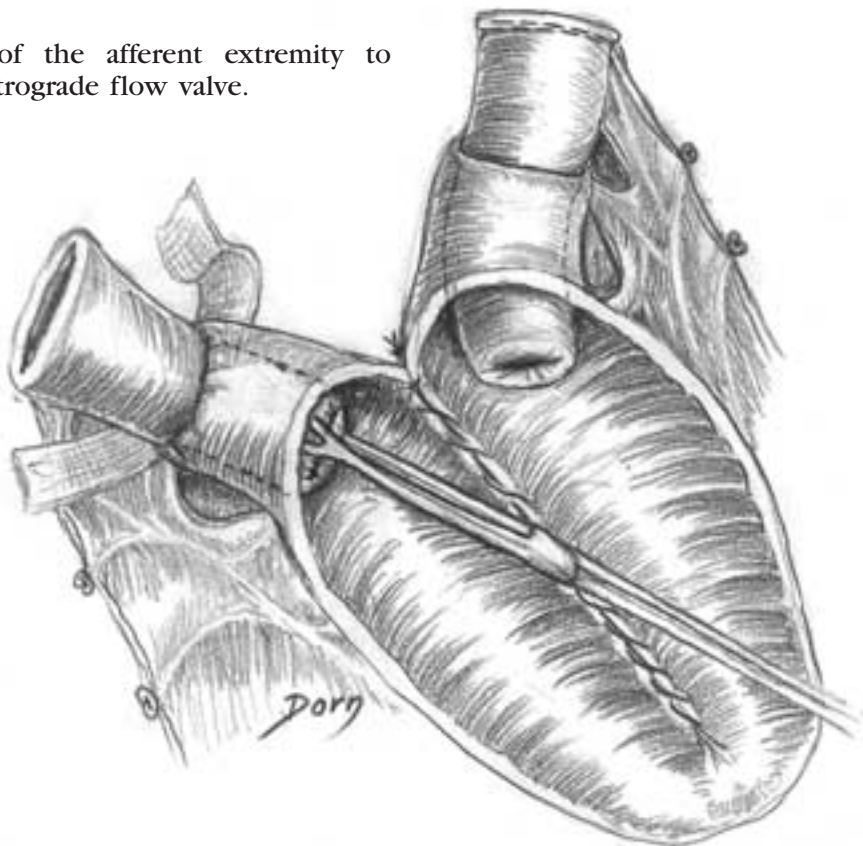
A The distal portion of the ileum is isolated with the corresponding part of mesentery.



B The ileum is opened and sutured to reproduce a bladder.

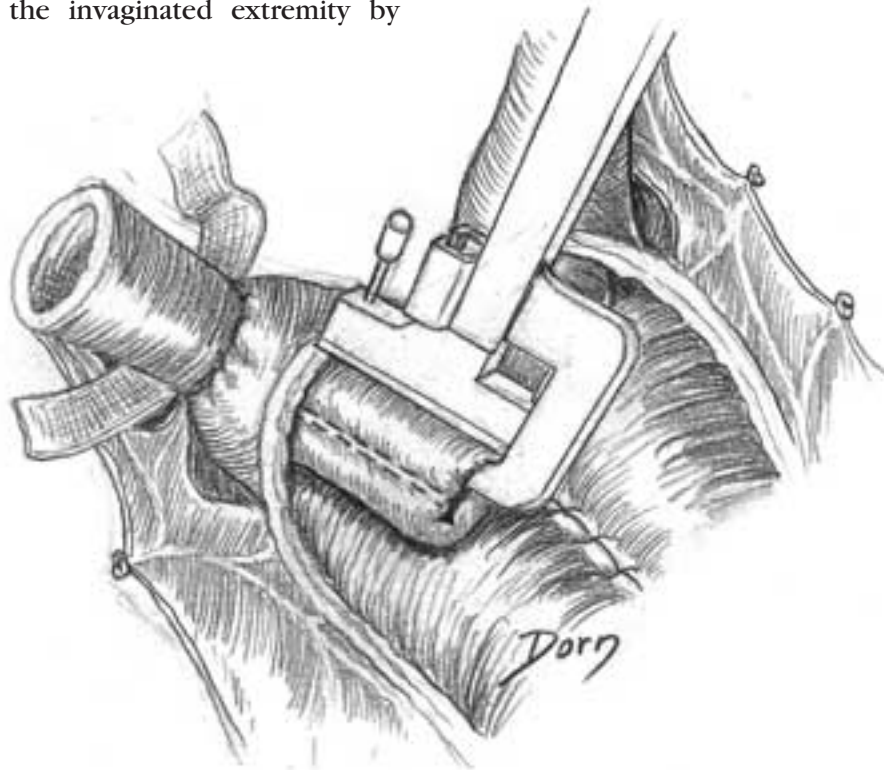


C Invagination of the afferent extremity to perform an antiretrograde flow valve.

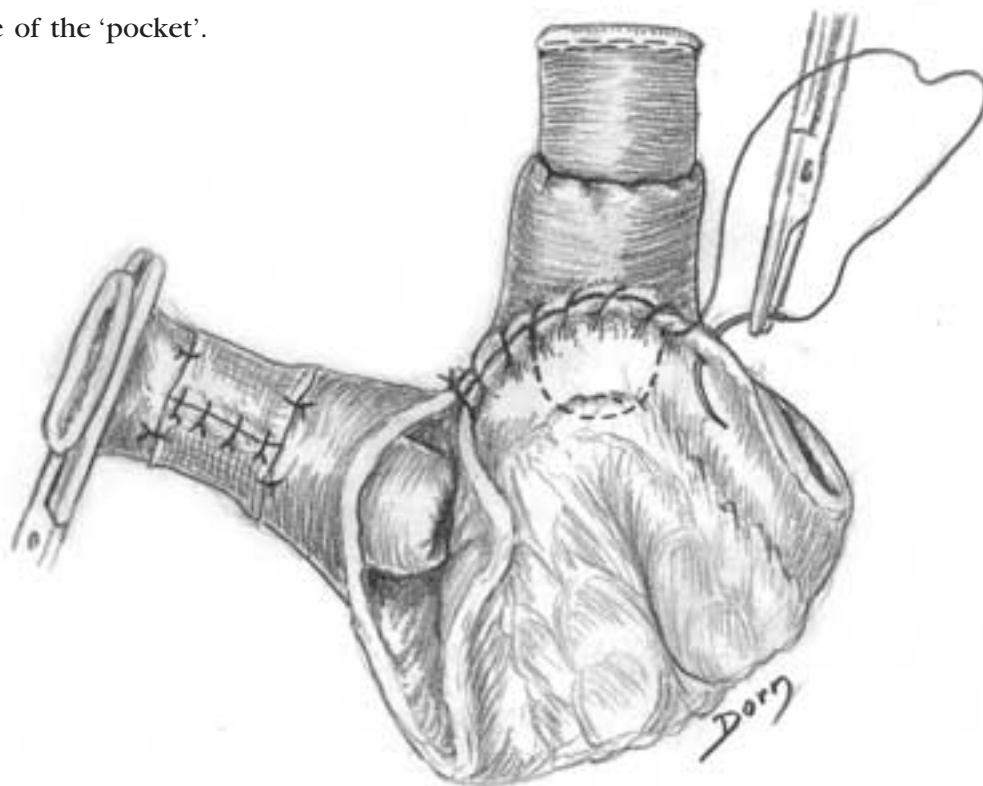


Abdominal surgery

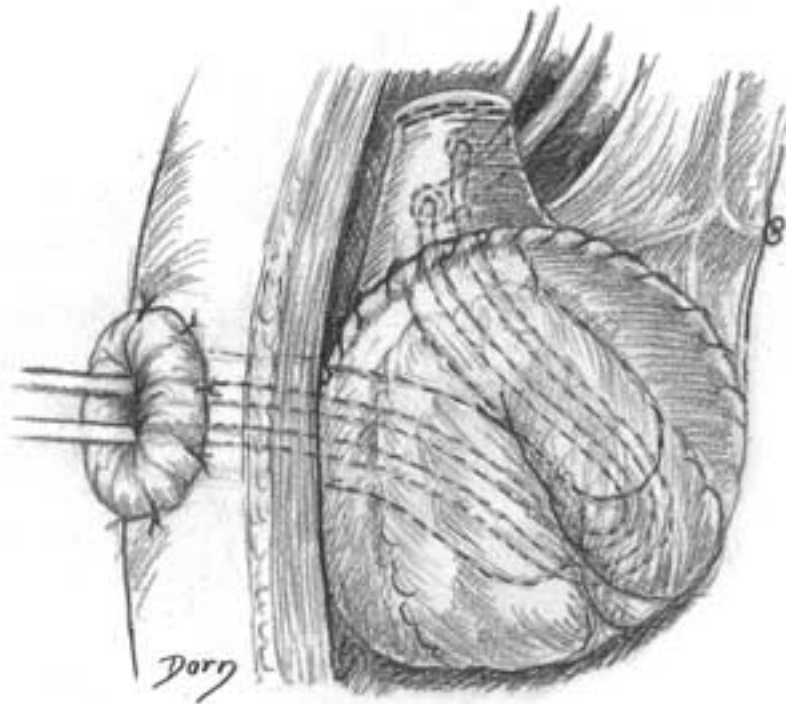
D Stabilisation of the invaginated extremity by staples.



E Suture of the 'pocket'.



F The two ureters are implanted in the afferent extremity. The efferent extremity is passed through the abdominal wall to constitute a stomy.



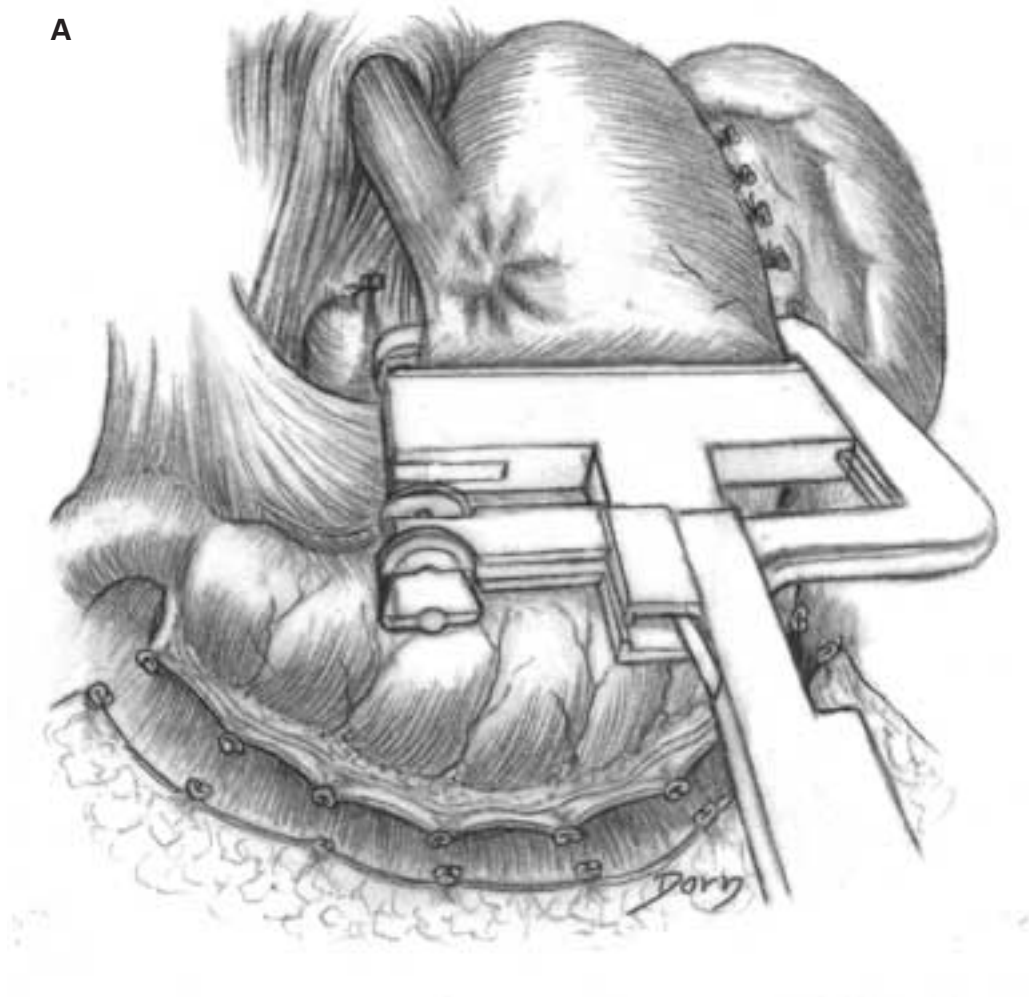
Abdominal surgery

Gastrectomy

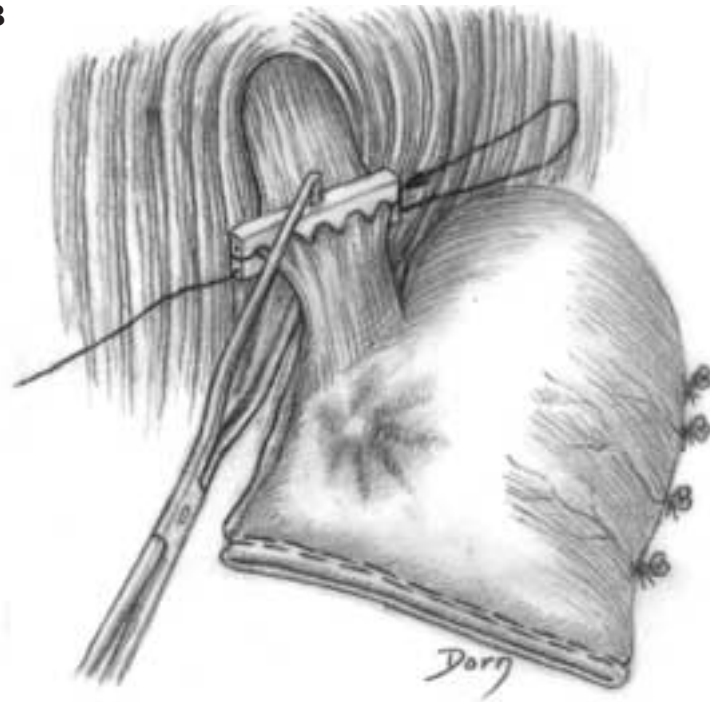
- Oesogastrectomy for cancer.

The tumour is located near the cardia.

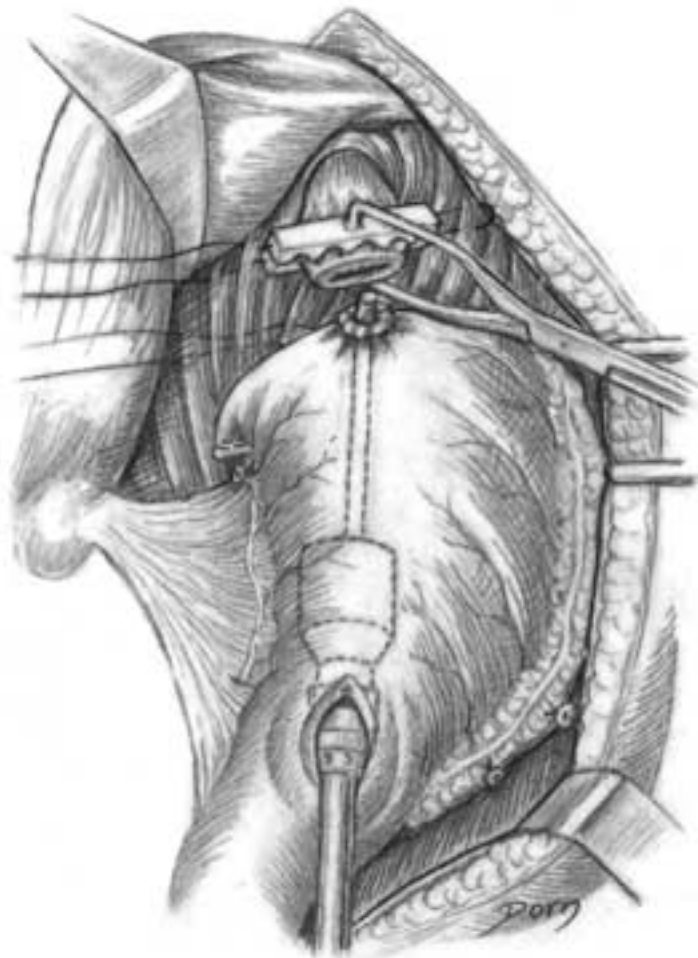
A, B Excision of the proximal two-thirds of the stomach and the distal part of the oesophagus.



B



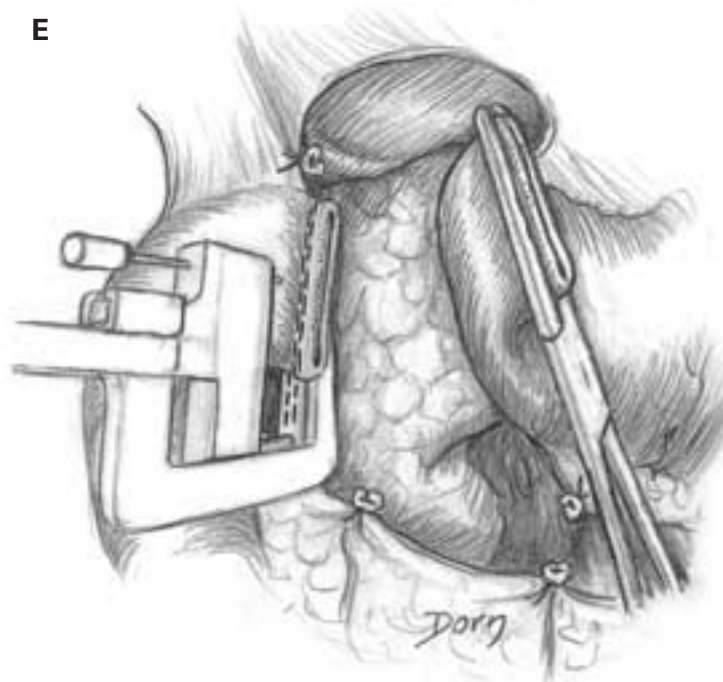
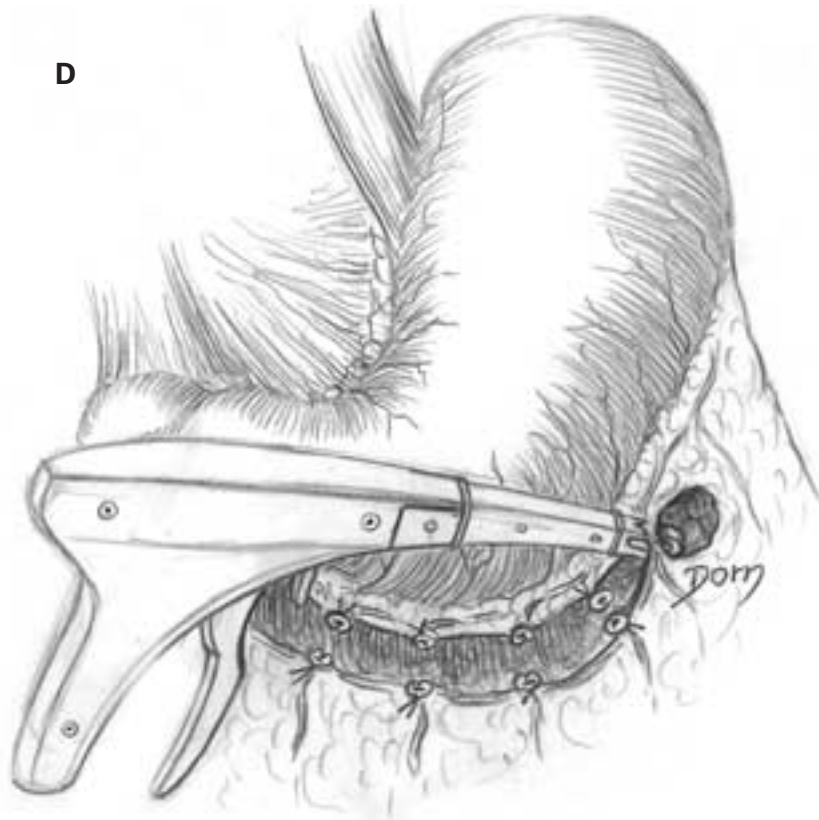
C The distal portion of the stomach is lifted up and anastomosed with the oesophagus.



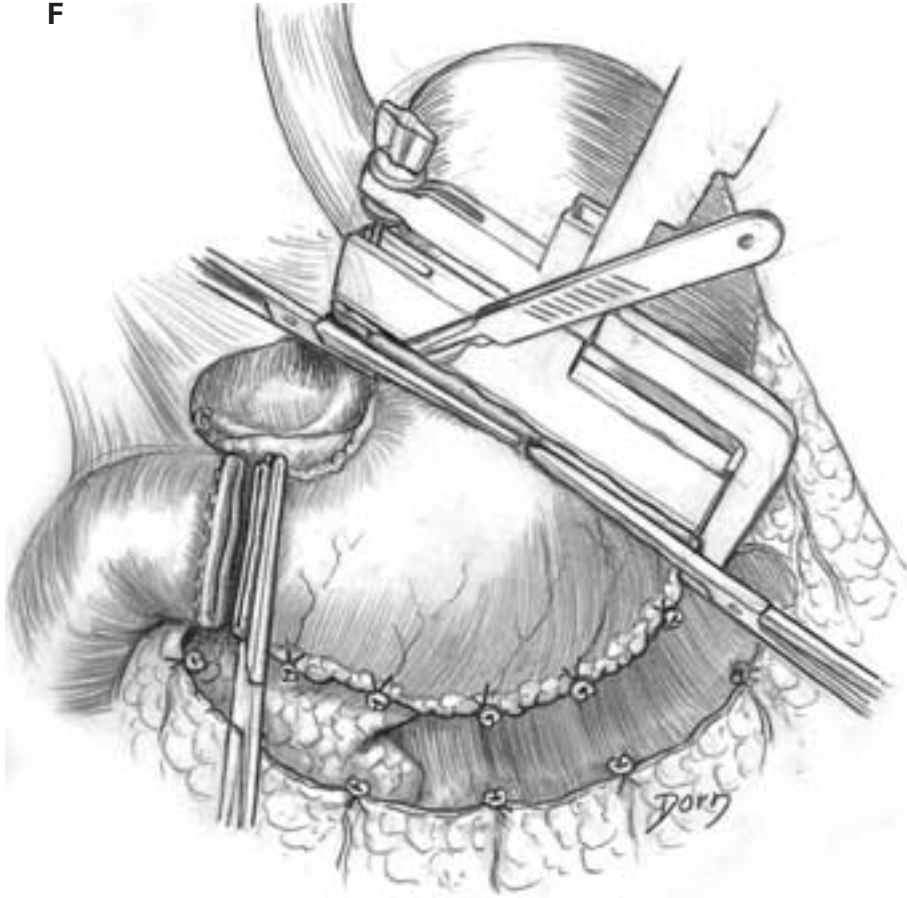
Abdominal surgery

- gastrectomy and anastomoses with the jejunum.

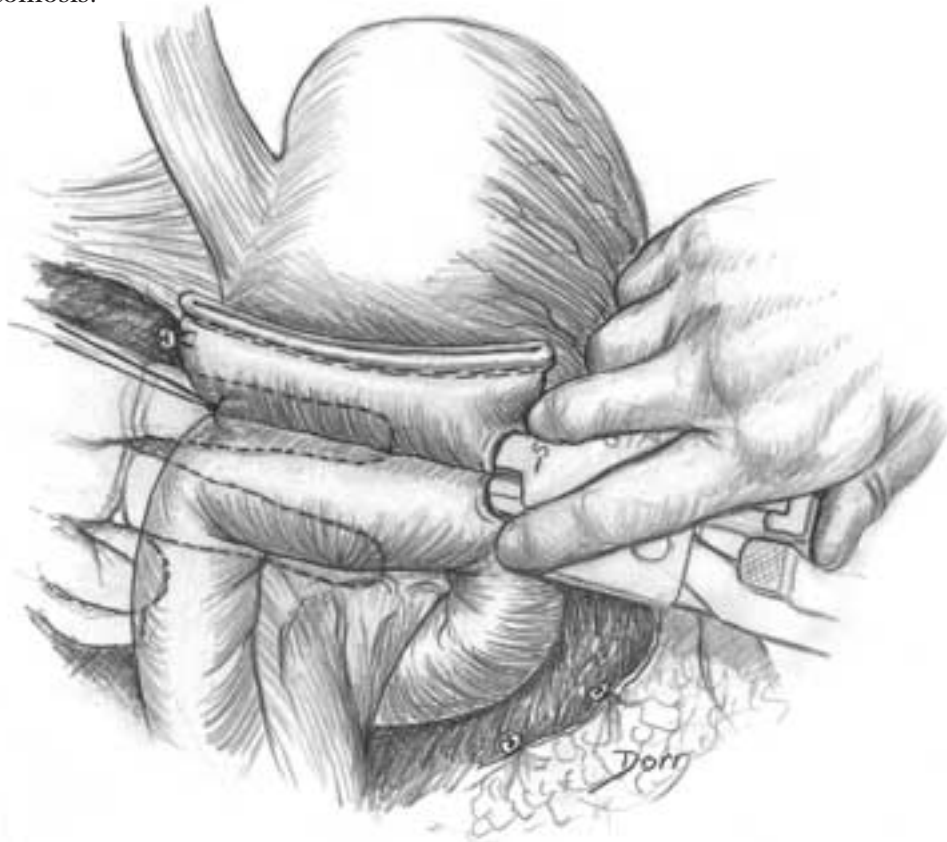D–F The distal two-thirds of the stomach is isolated and removed. The extremities of the remaining portion of the stomach and of the jejunum are closed with mechanical staples.



F

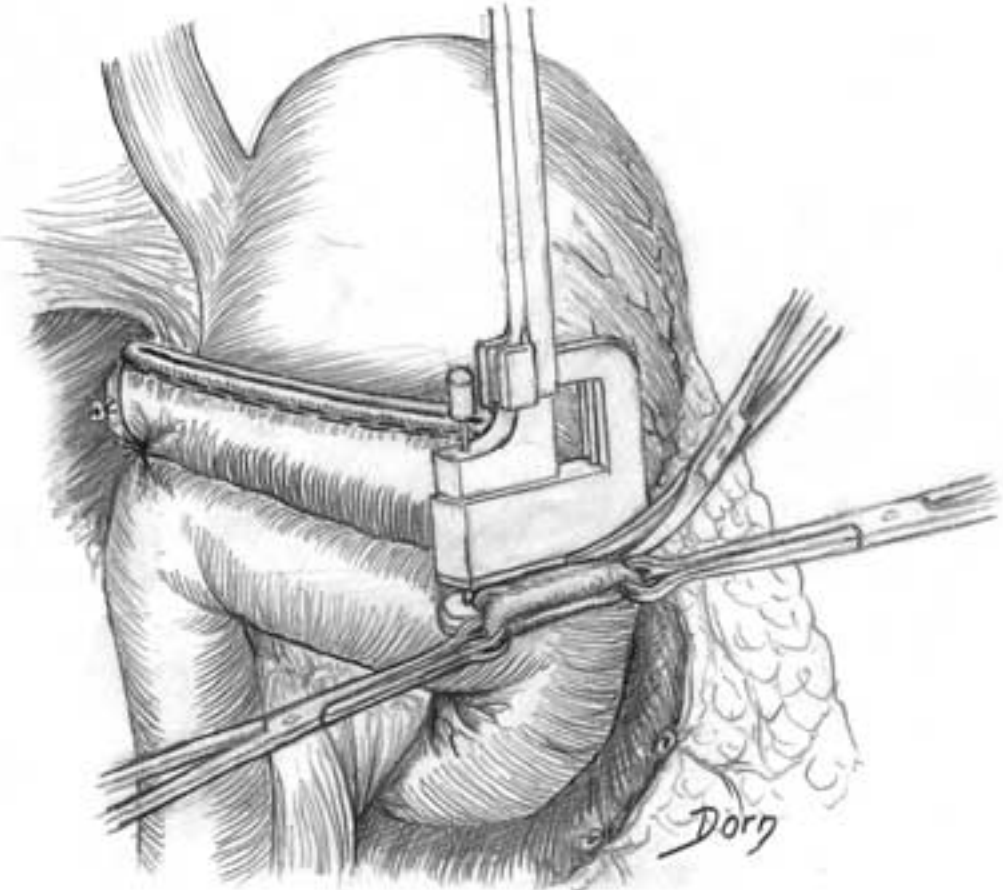


G The jejunum is prepared for the end-to-side anastomosis.

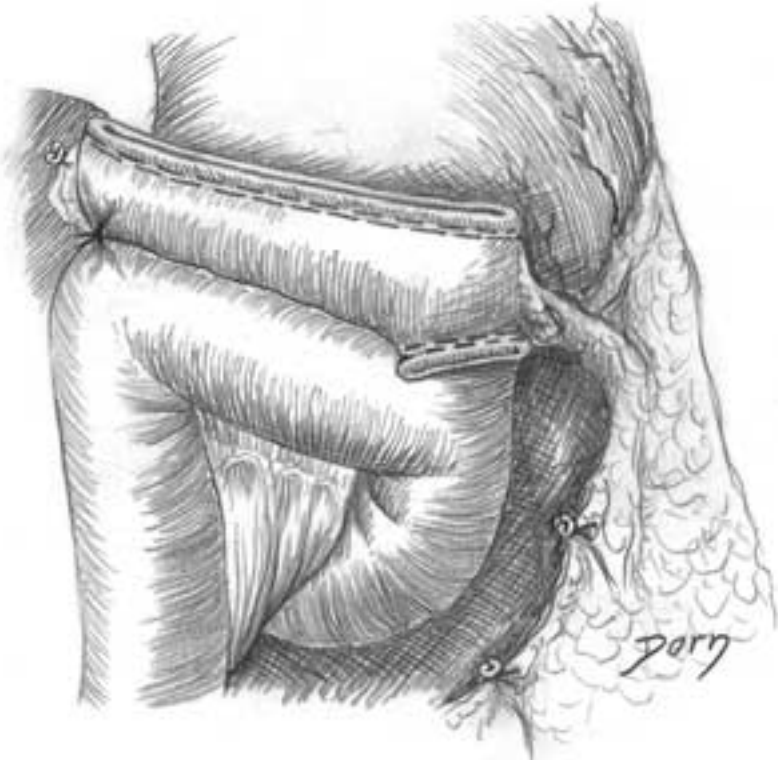

H, I Final view of the procedure.

H

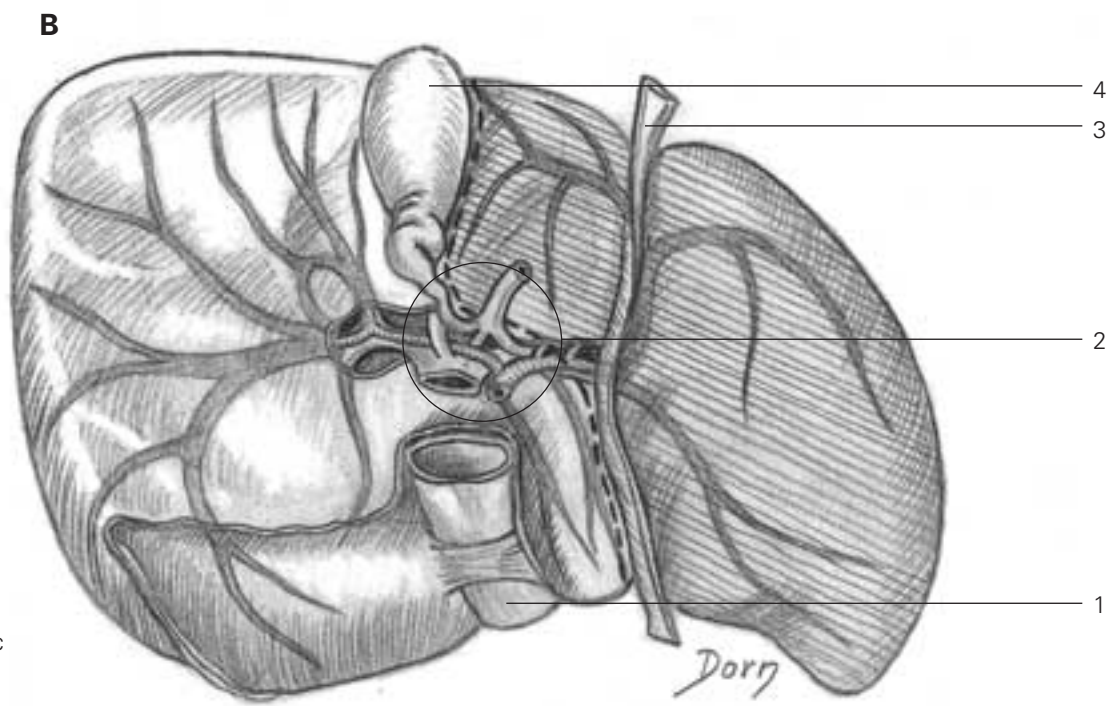
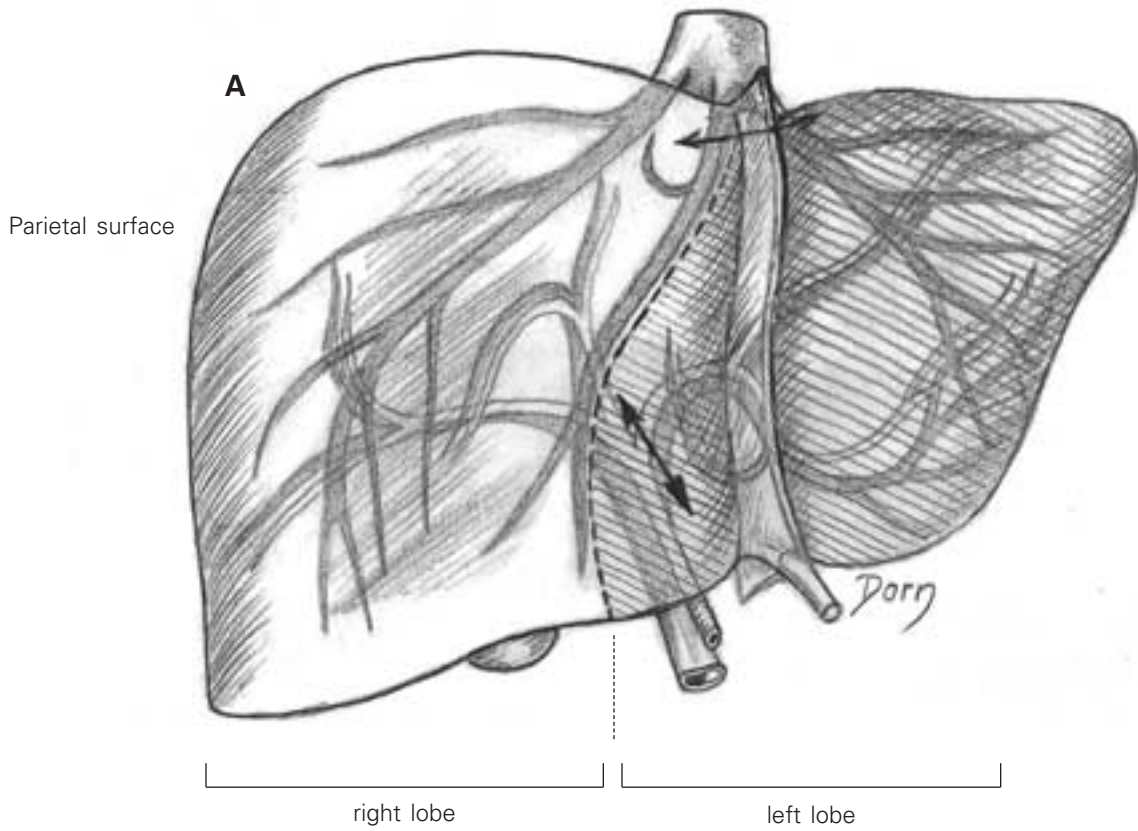


I



The liver

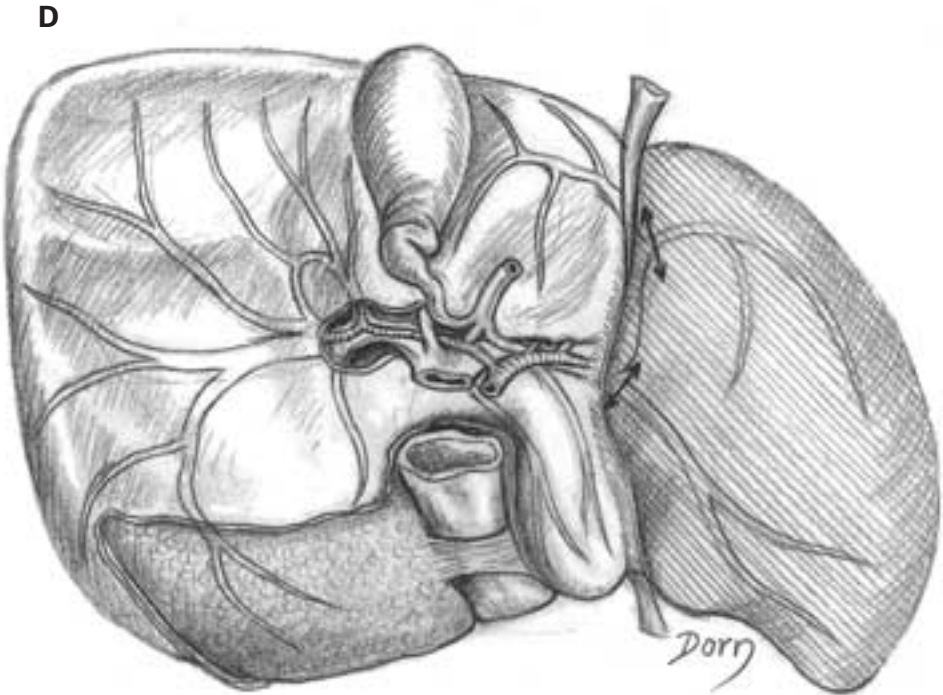
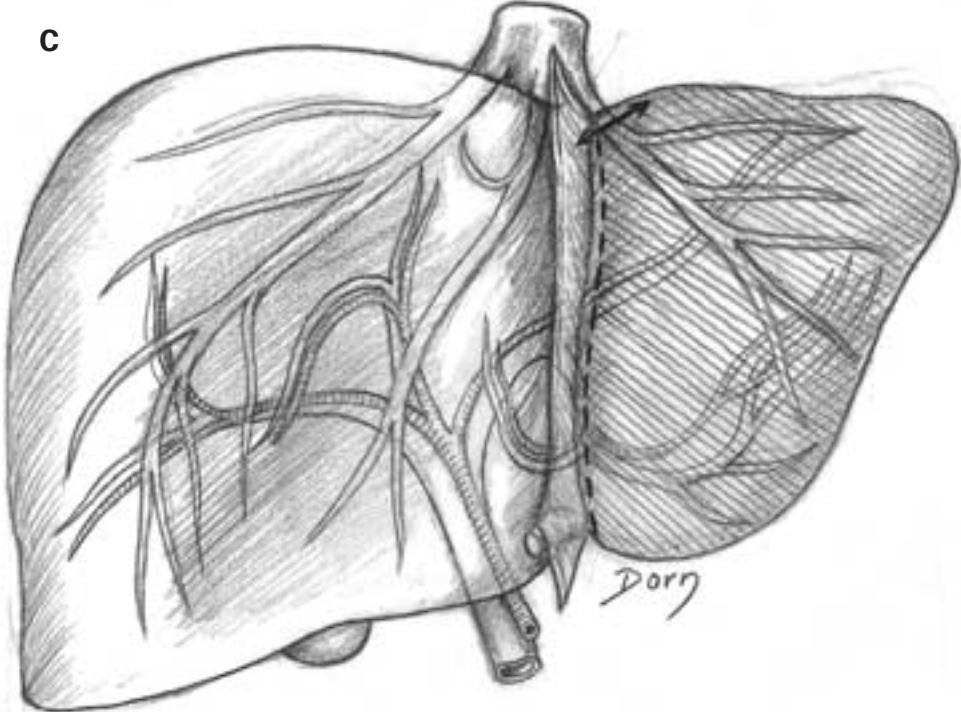
A–B The two lobes of the liver. Distribution of vessels and cuts.



- 1 inferior vena cava
- 2 common hepatic duct, portal vein and proper hepatic artery
- 3 round ligament
- 4 gall bladder

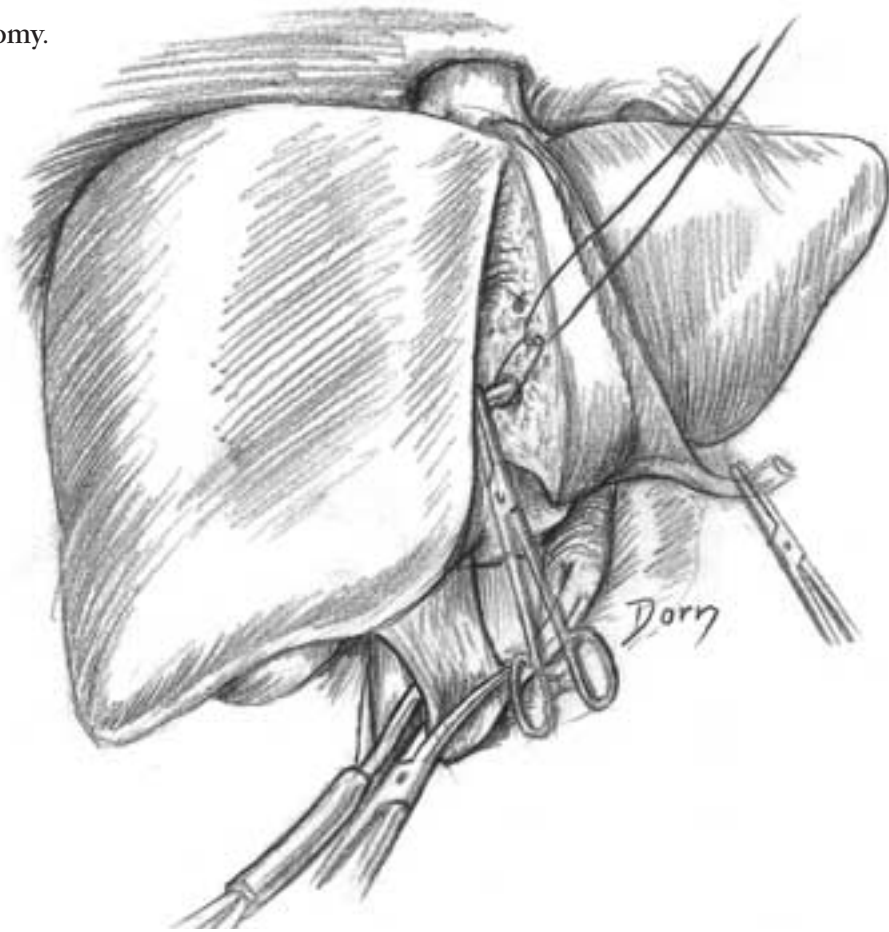
Abdominal surgery

C, D Anatomic variation of the distribution. The left lobe is less developed.

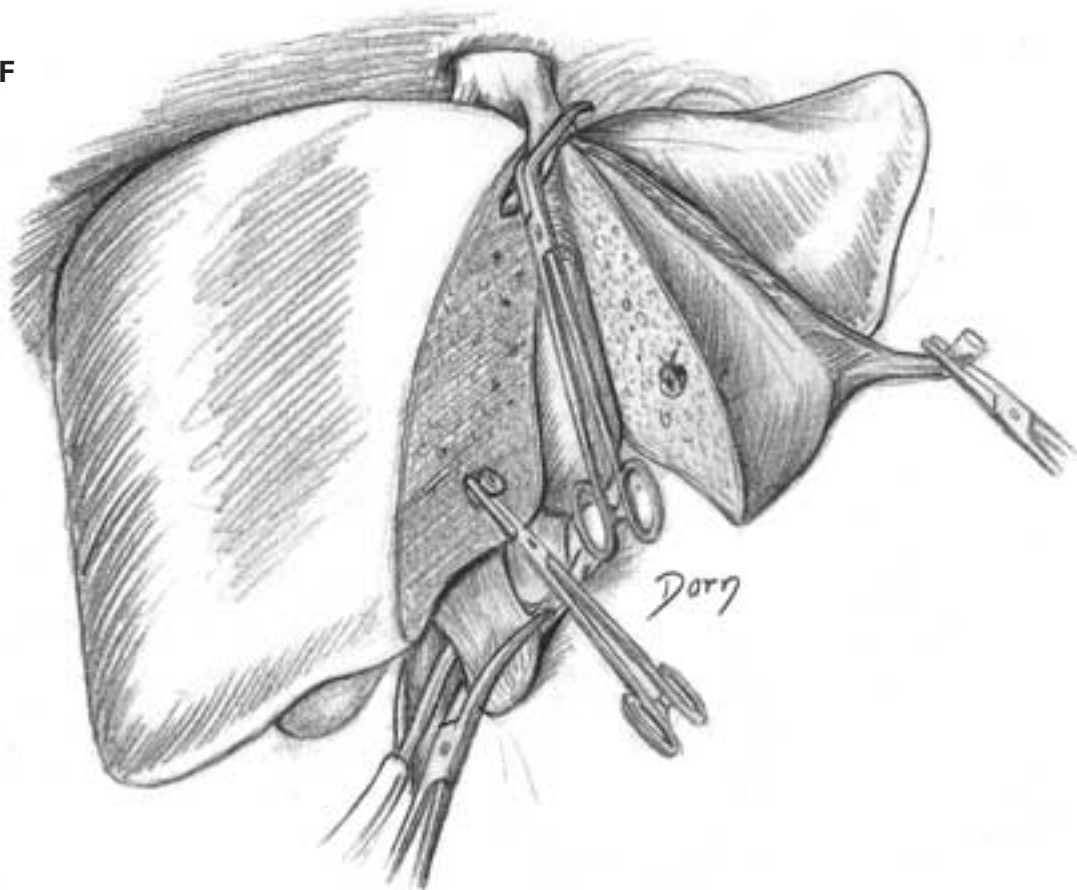


E, F Left hepatectomy.

E



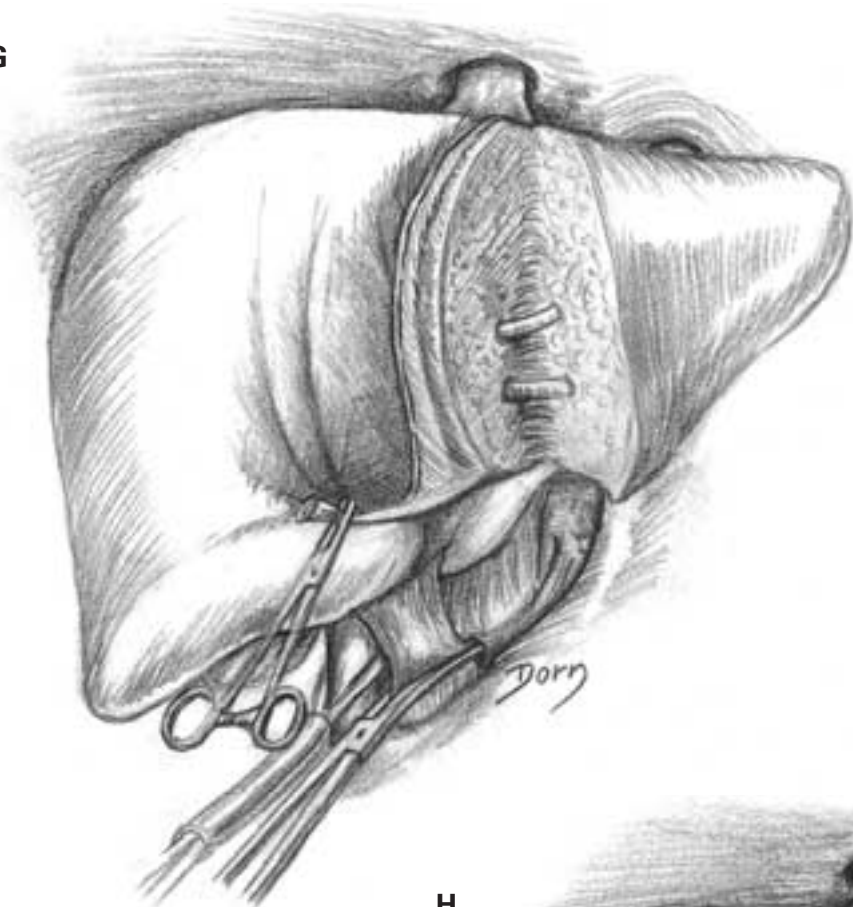
F



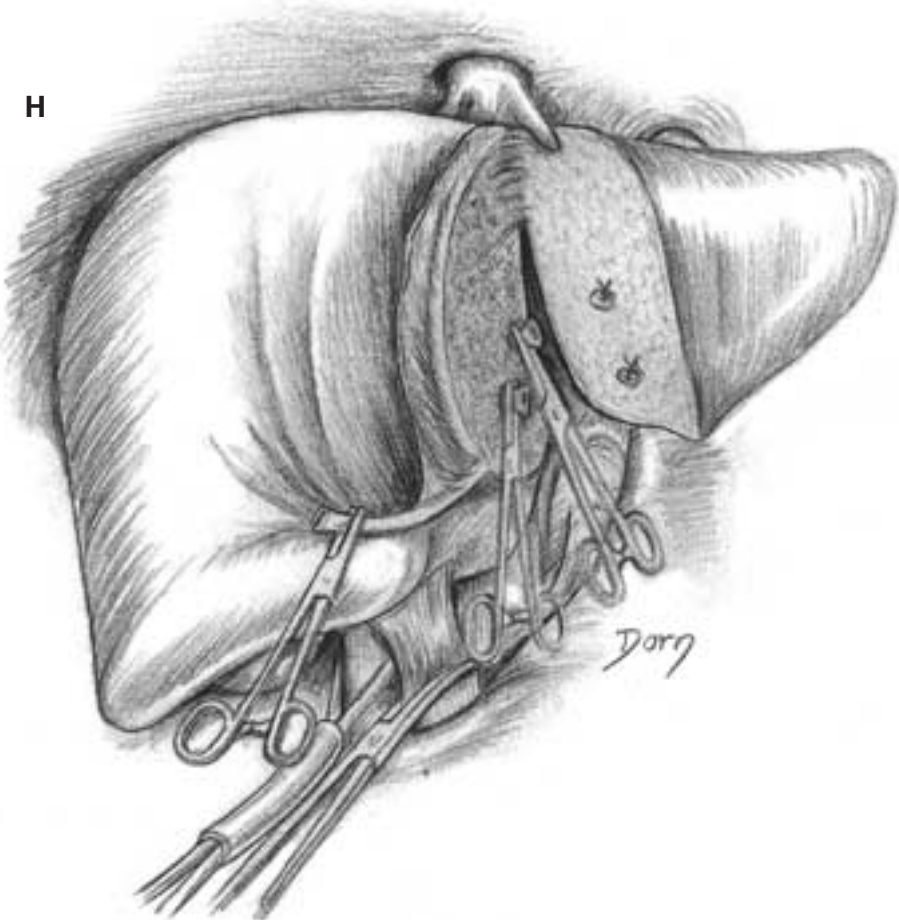
Abdominal surgery

G, H Partial left hepatectomy.

G



H



Surgery of the vertebral column

The following chapter is in a less complete or definitive fashion since the drawings were made a long time ago and many sketches were lost. However, this

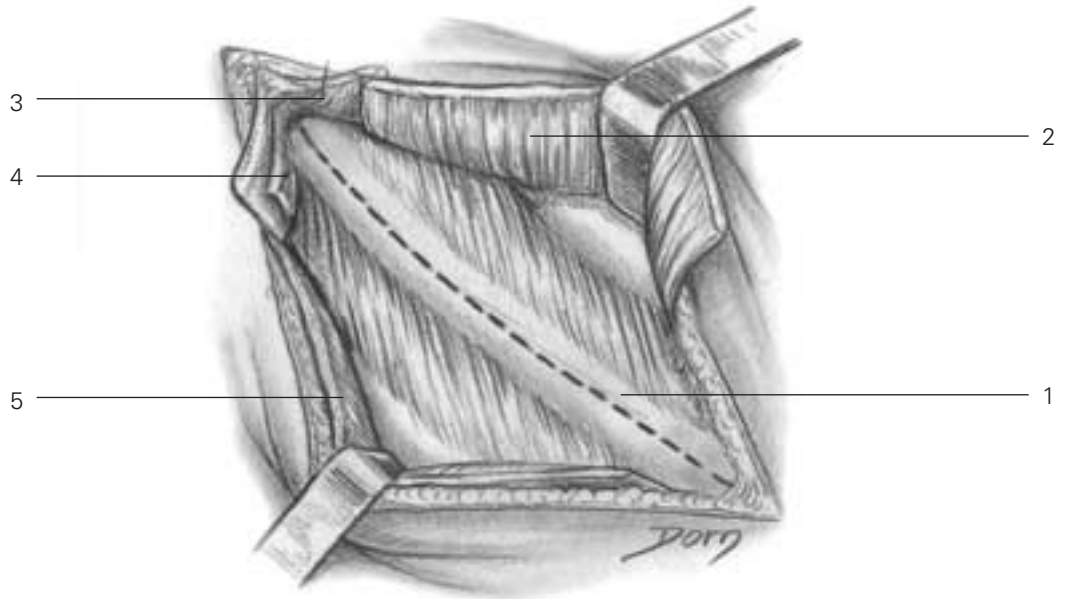
presentation allows us to appreciate the artistic skills of Léon Dorn, whatever the field of anatomy or surgery.

Surgery of the vertebral column

Transpleural approach to the dorsal rachis by thoracotomy

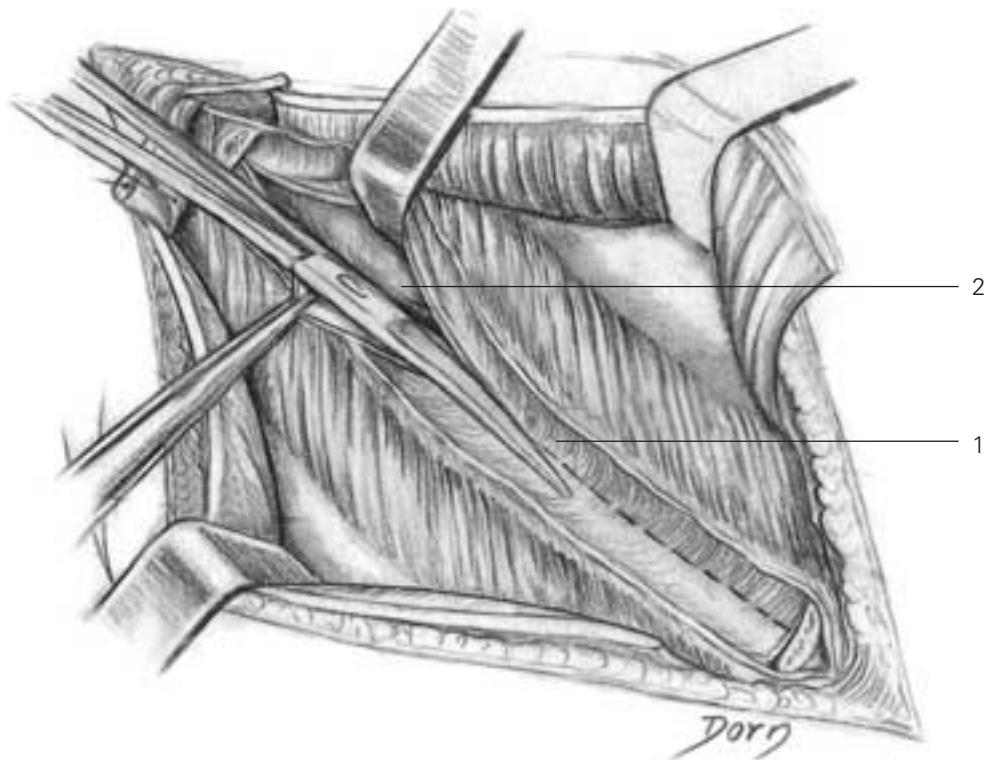
A The posterolateral incision is at the level of the sixth rib. The latissimus dorsi muscle is severed.

- A**
- 1 sixth rib
 - 2 latissimus dorsi
 - 3 trapezius
 - 4 rhomboid
 - 5 latissimus dorsi

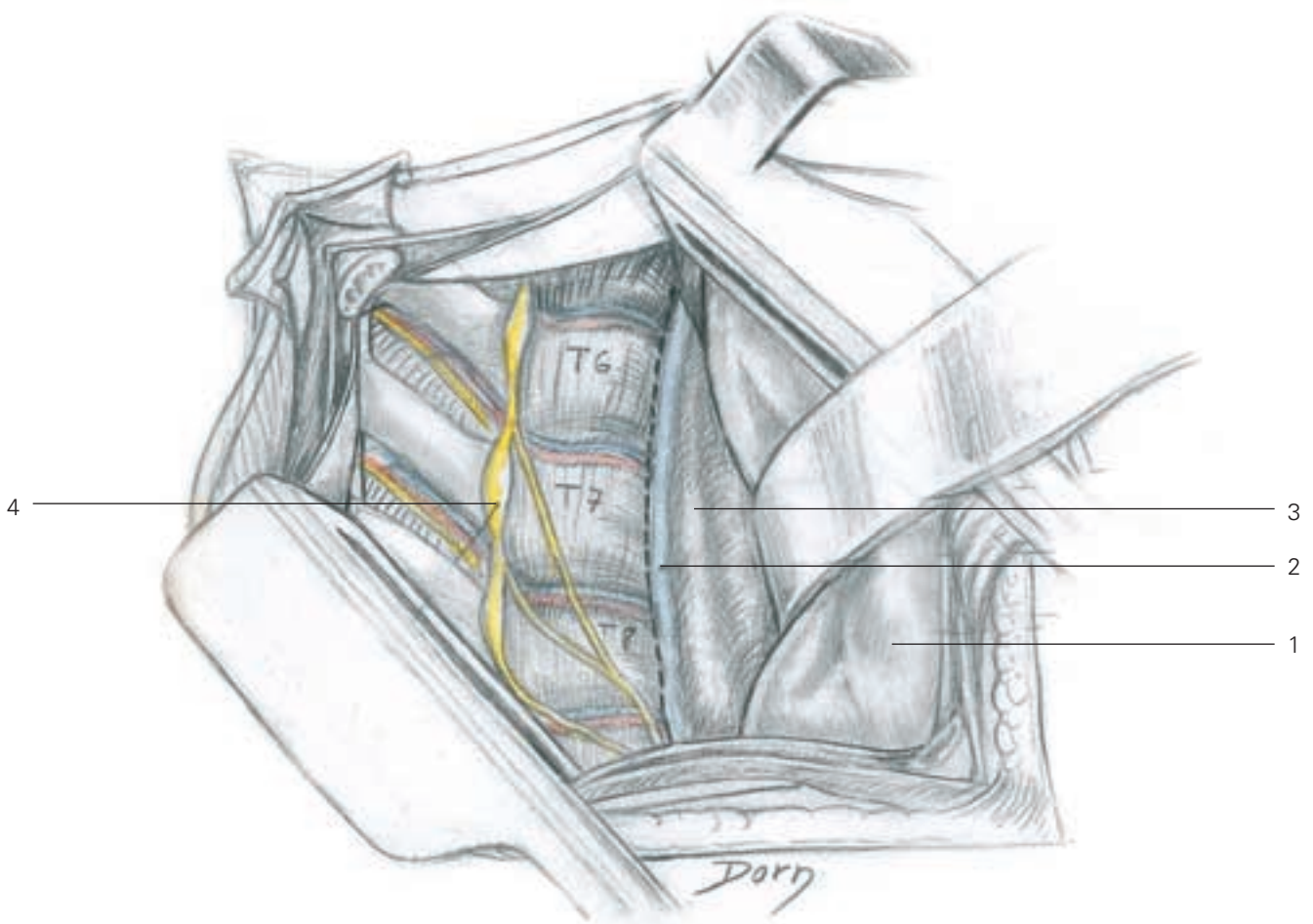


B A segment of rib has been removed. The pleura is incised.

- B**
- 1 incision of the periosteum
 - 2 parietal pleura



C Exposure of the dorsal rachis; the oesophagus, azygos vein and lung are gently retracted.



- C**
- 1 pleura and lung retracted
 - 2 azygos vein
 - 3 oesophagus
 - 4 sympathetic trunk and ganglia

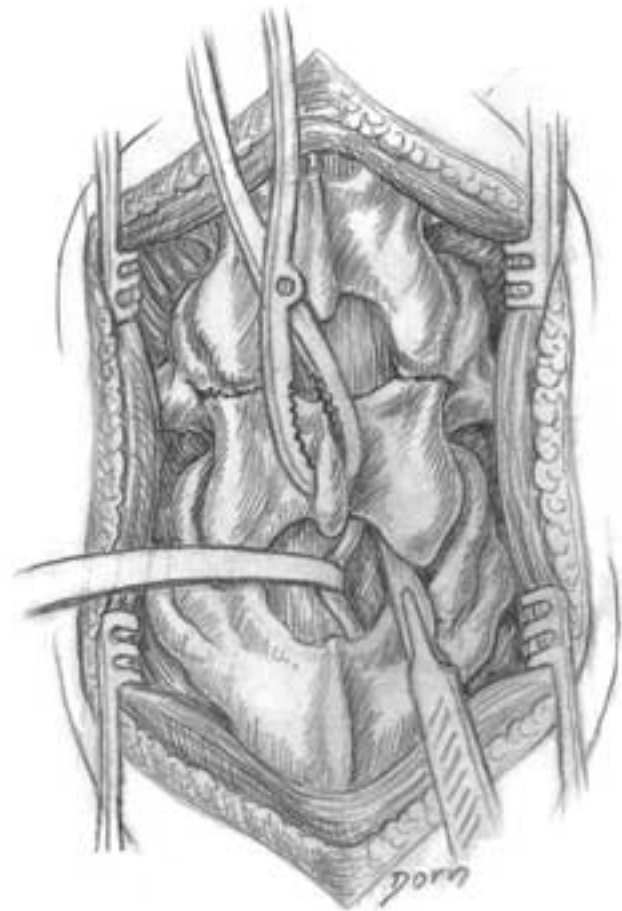
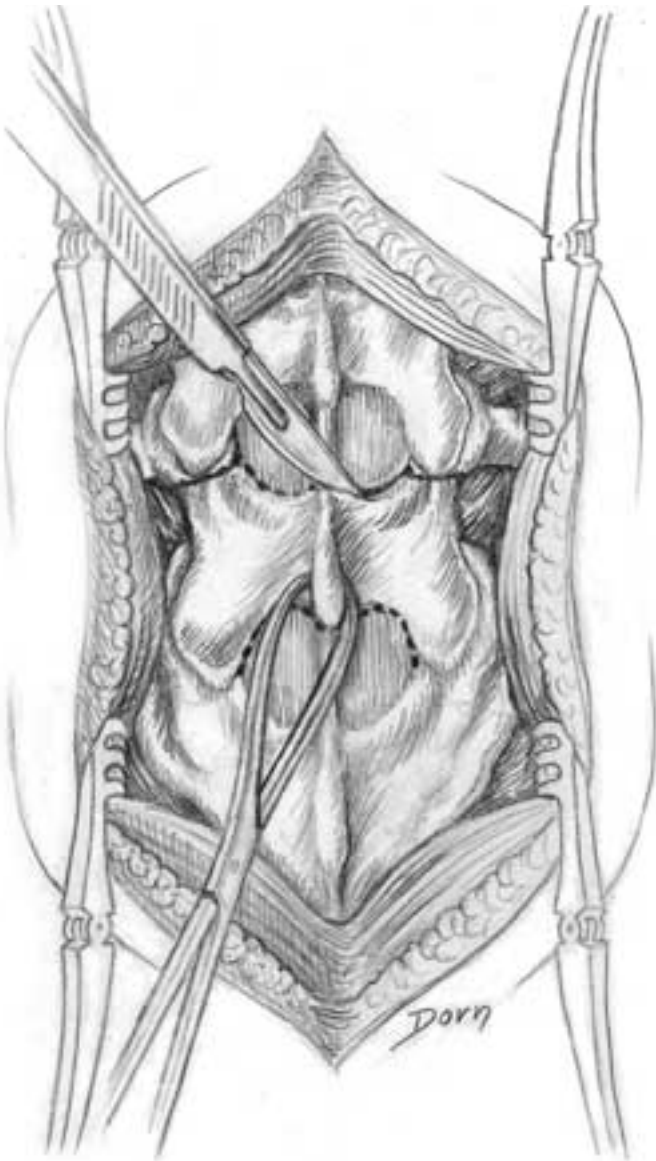
Surgery of the vertebral column

Treatment of lumbar spondylolisthesis

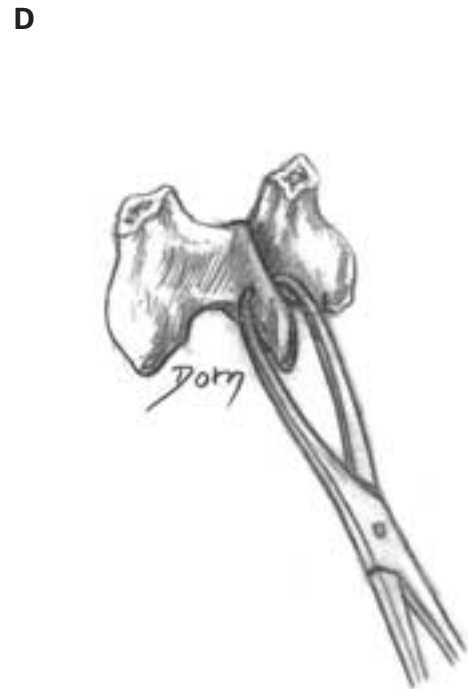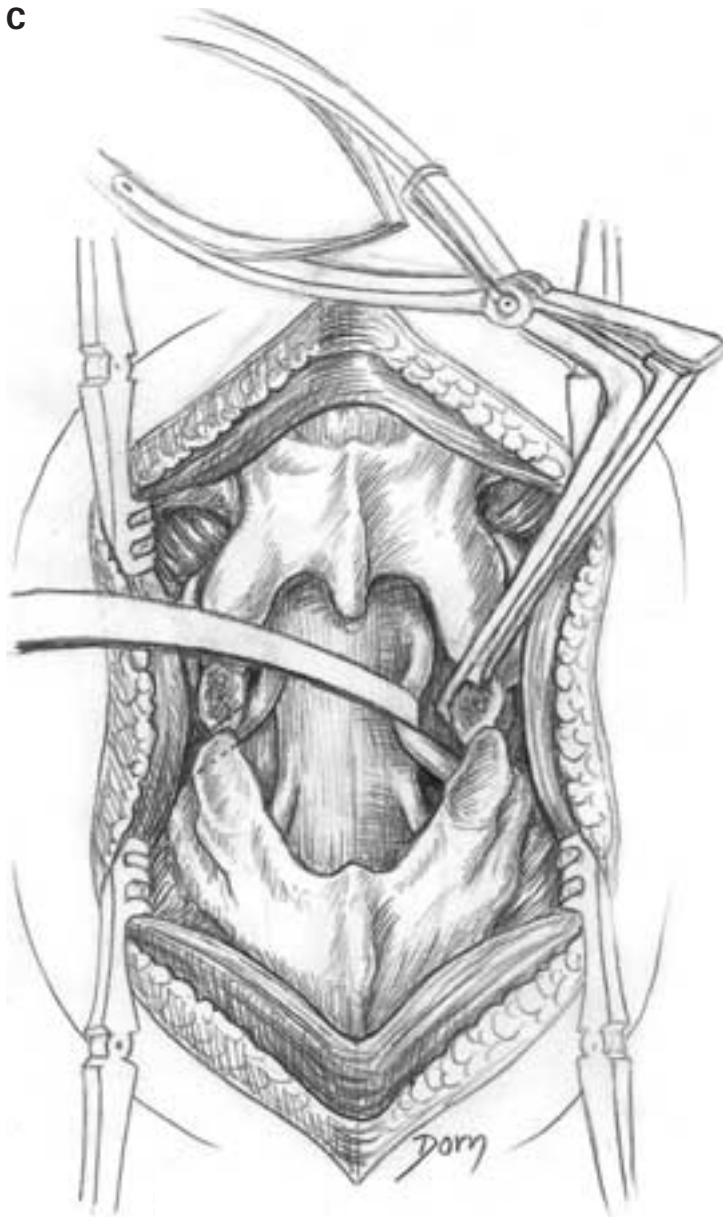
The surgical technique consists of the resection of the posterior segment of a vertebra and corporeal fusion with the underlying vertebra.

A After exposure of the affected vertebra the ligamentum flavum is excised.

B The inferior joints are opened and the capsule is excised. The superior articular facets are osteotomised.

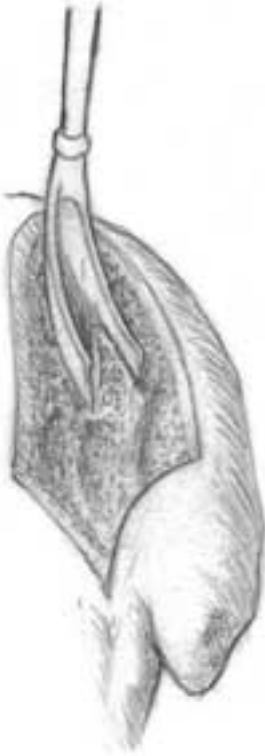

C, D The whole of the posterior portion of the vertebra is removed. The spinal cord is freed.

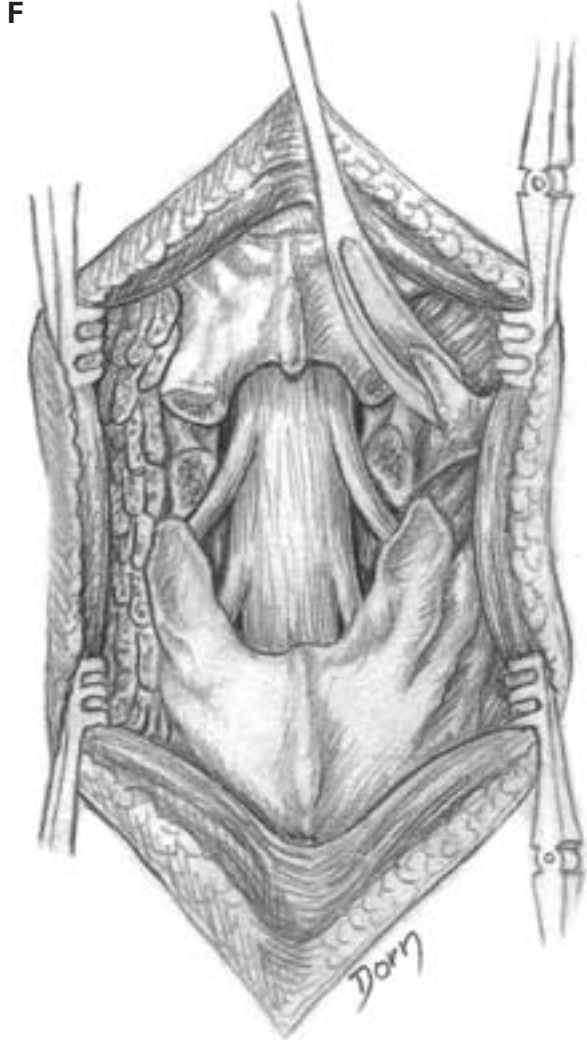


Surgery of the vertebral column

E Harvesting cancellous bone from the posterior iliac crest.

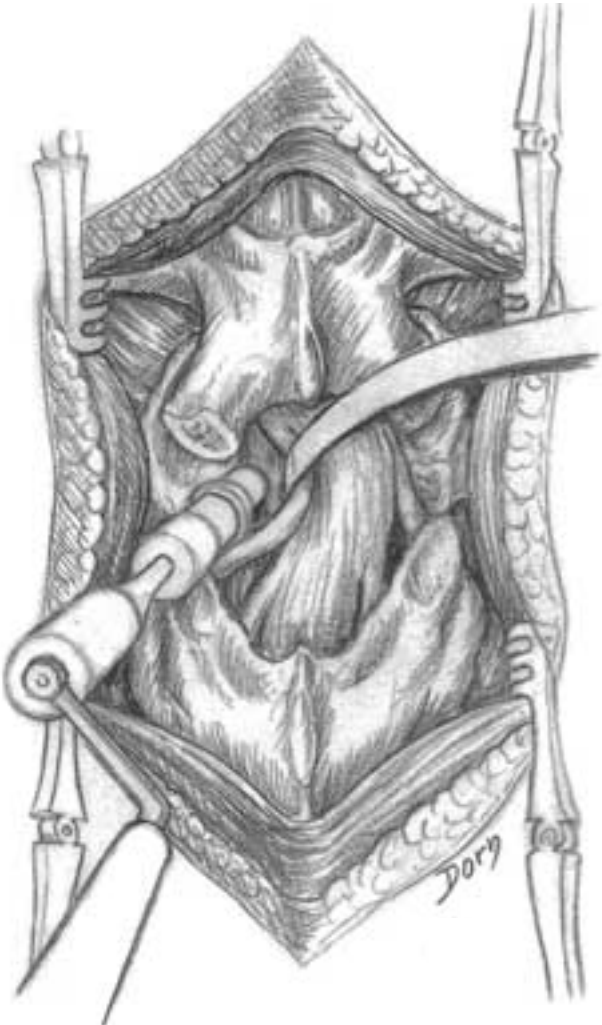

F A posterolateral fusion is prepared by putting small chips of cancellous bone on the transverse processes.

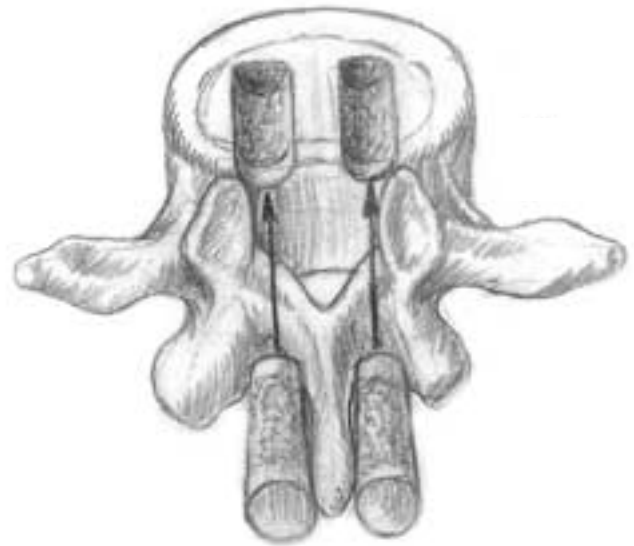


G, H An intersomatic fusion by the same posterior approach can be combined with the posterolateral fusion or it can be performed as an alternative by the anterior approach.

G



H

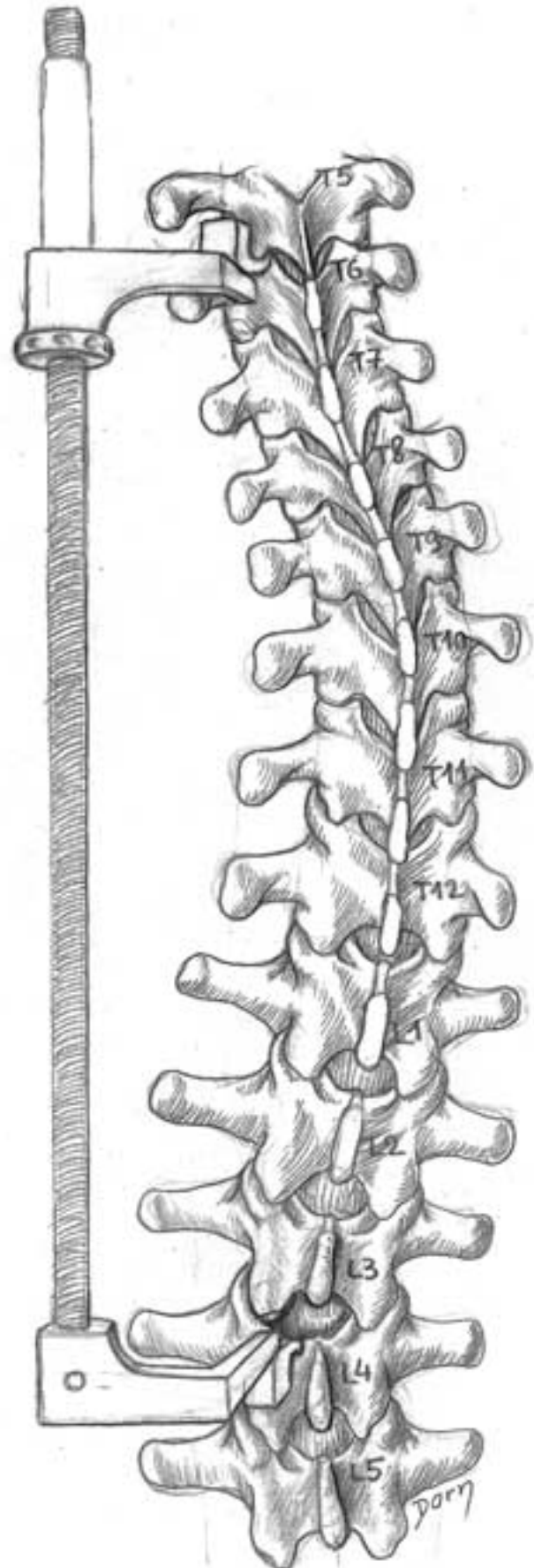


Surgery of the vertebral column

Surgical treatment of scoliosis

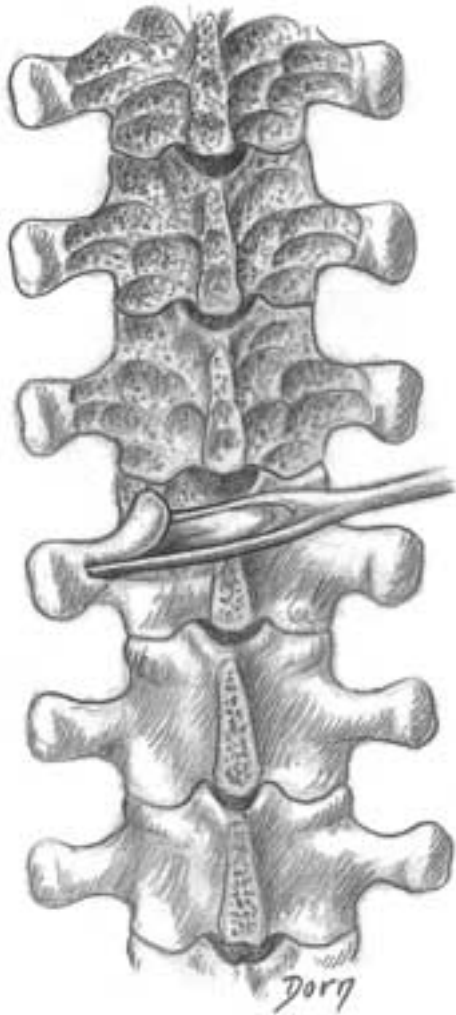Different devices have been described for correction of scoliosis. This series of illustrations presents Harrington's rod, which is now considered obsolete.

A The principle of Harrington's procedure. The rod is used in distraction to correct the curvature; the extremities of the rod are fixed by hooks which are applied on the laminae of the vertebrae.

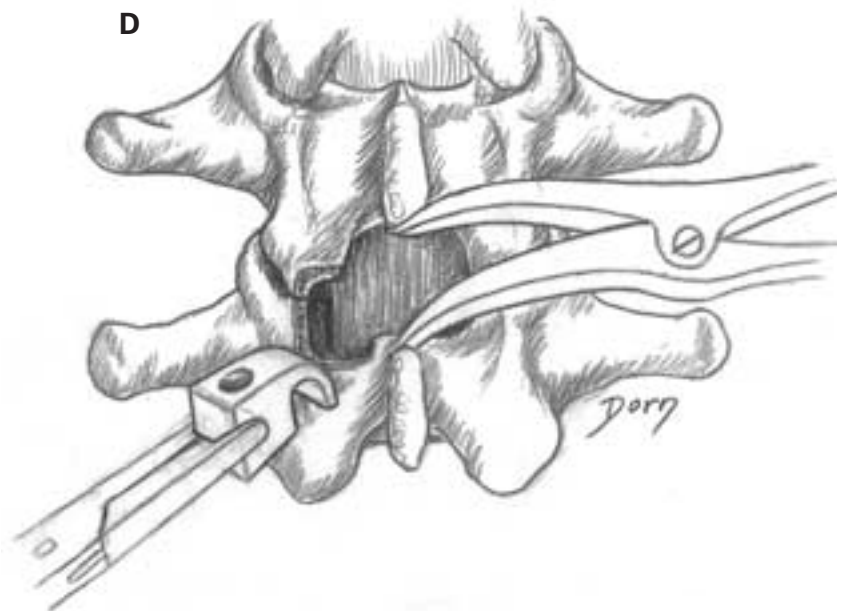
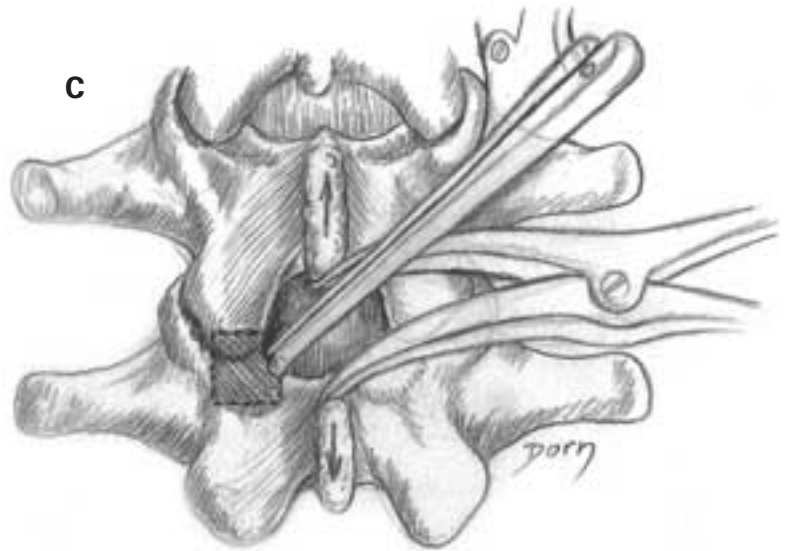


Surgery of the vertebral column

B Small bone chips of the posterior segments of the vertebrae are removed to prepare the posterior fusion.

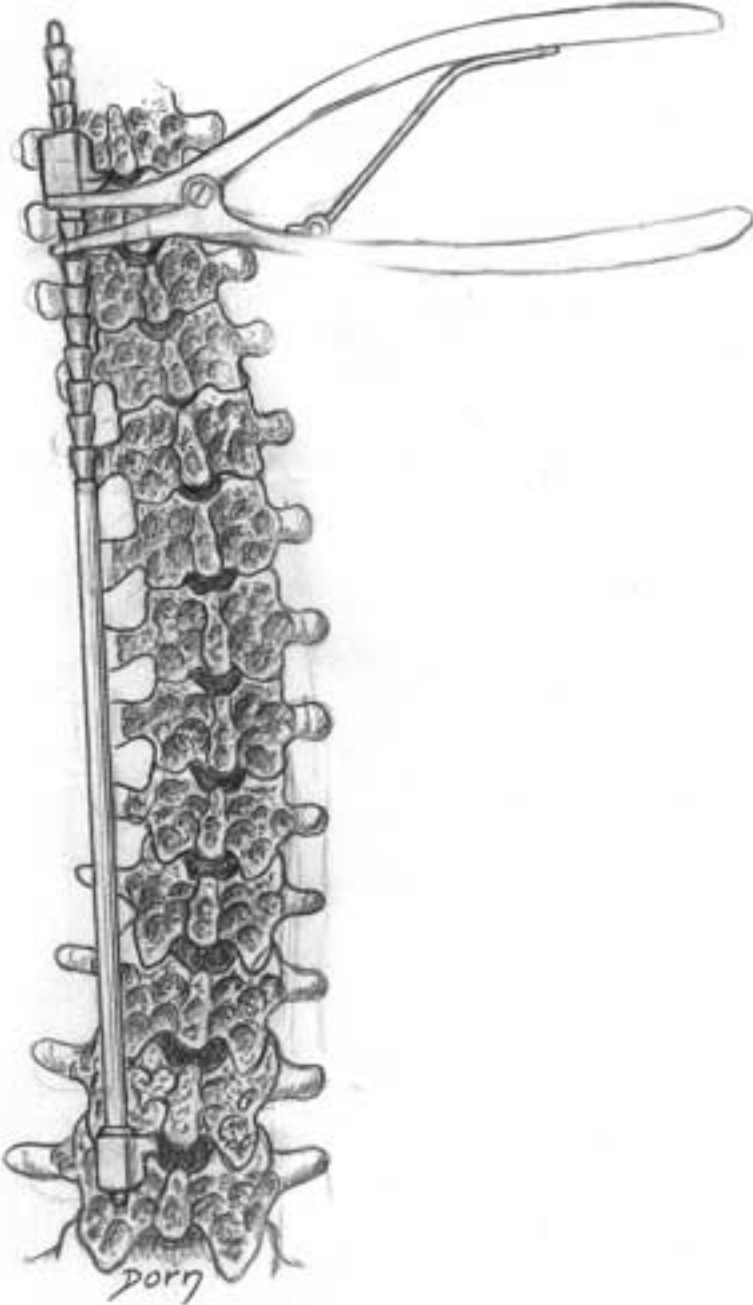


C, D The inferior hook is put in place; partial bone resection is needed.



Surgery of the vertebral column

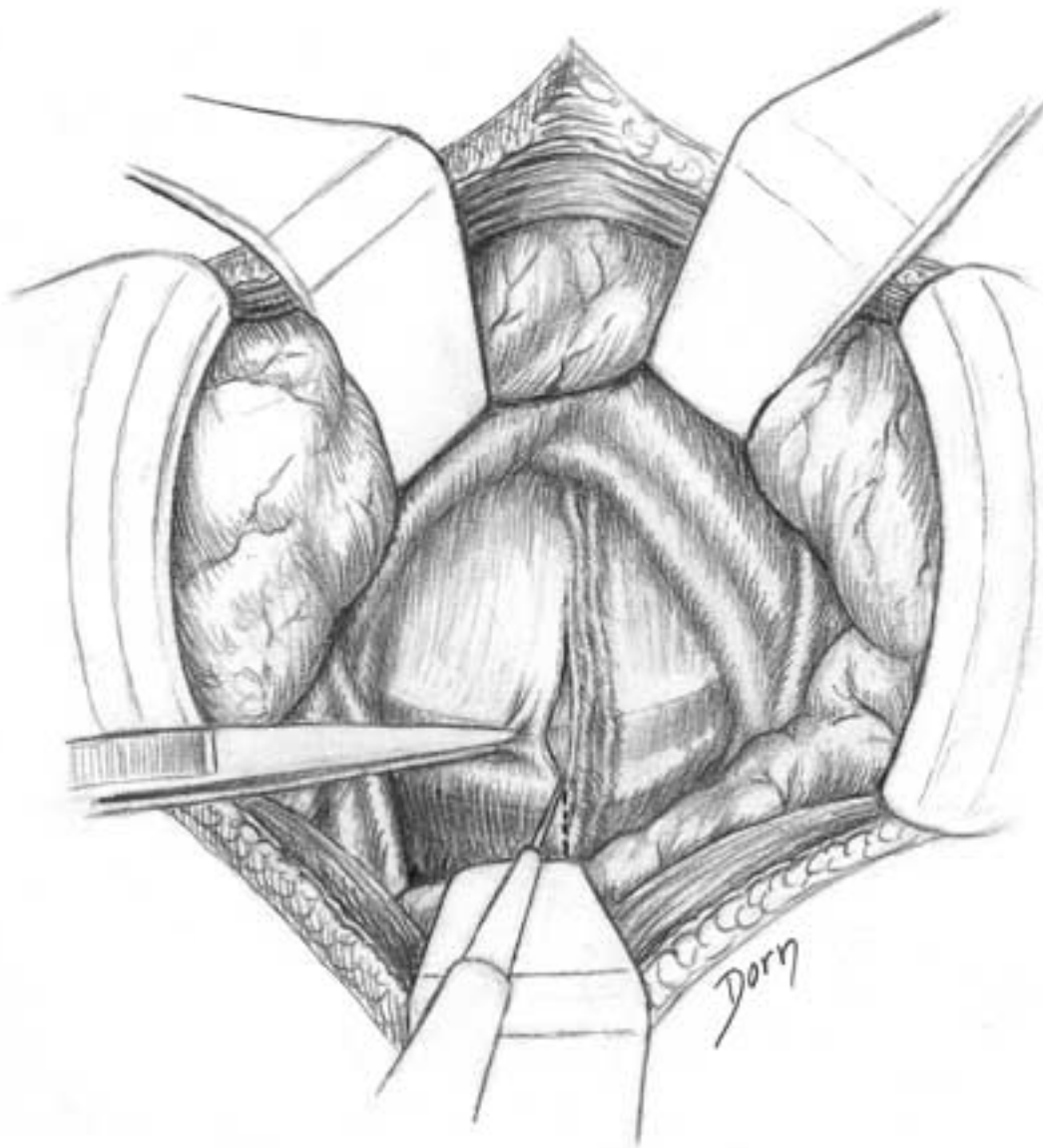E Setting Harrington's rod and distraction to correct the curvature.



Treatment of lumbar disc hernia: anterior approach

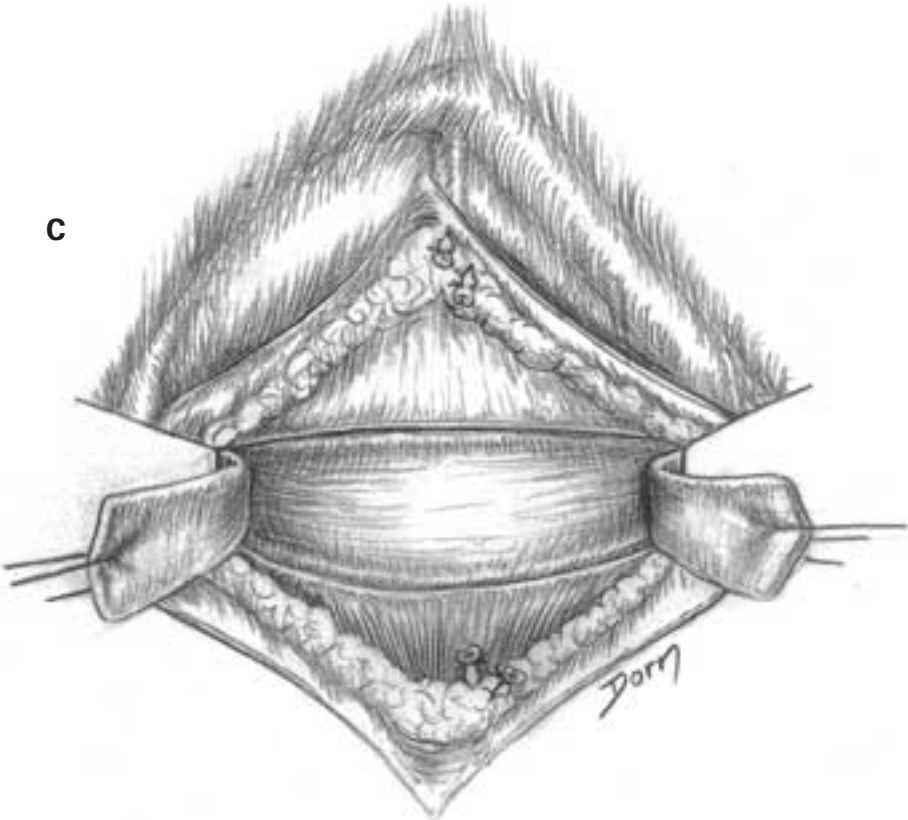
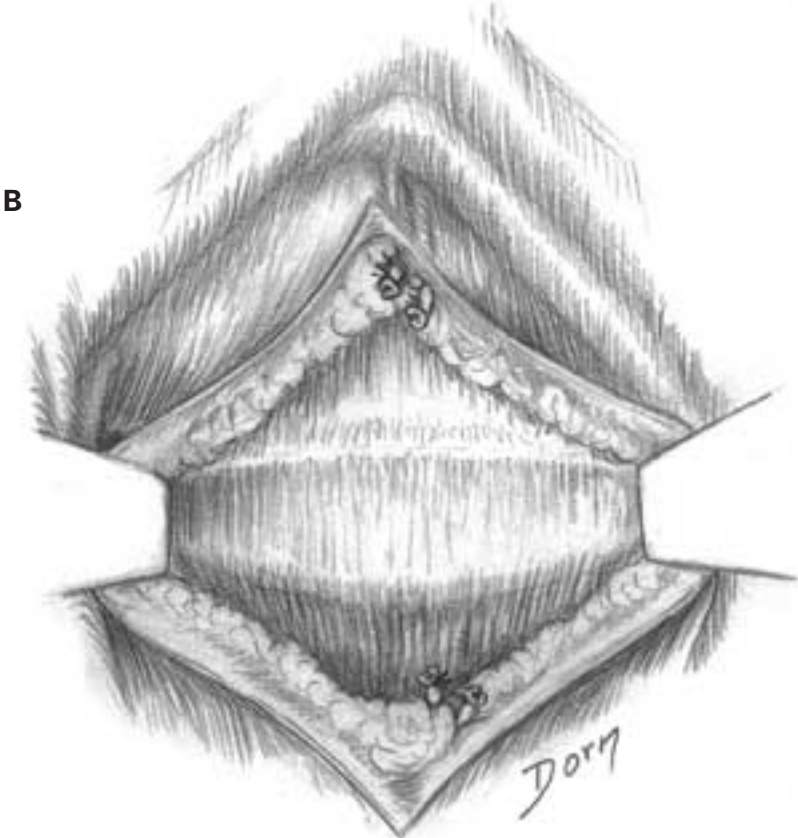
The anterior approach to remove a disc hernia at the lumbosacral level is usually not used. It is only indicated when an intersomatic fusion is performed in the same operation; the risk is a lesion of the superior hypogastric plexus.

A A transperitoneal approach is made. The organs are retracted. The sacral promontory is exposed and the posterior peritoneum is incised.

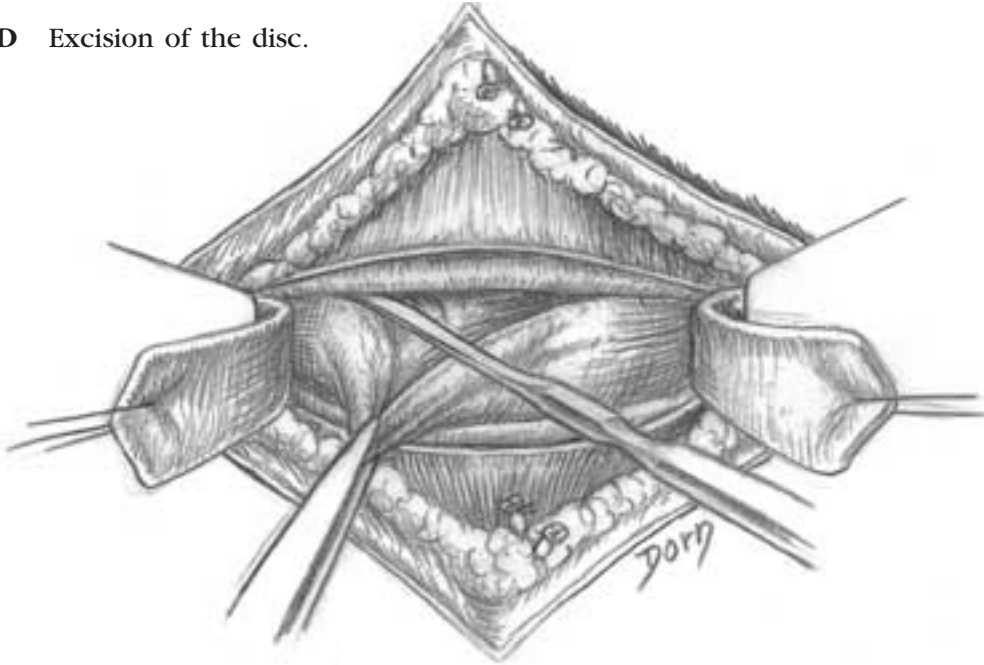


Surgery of the vertebral column

B, C The disc is exposed and the anterior longitudinal ligament is opened.

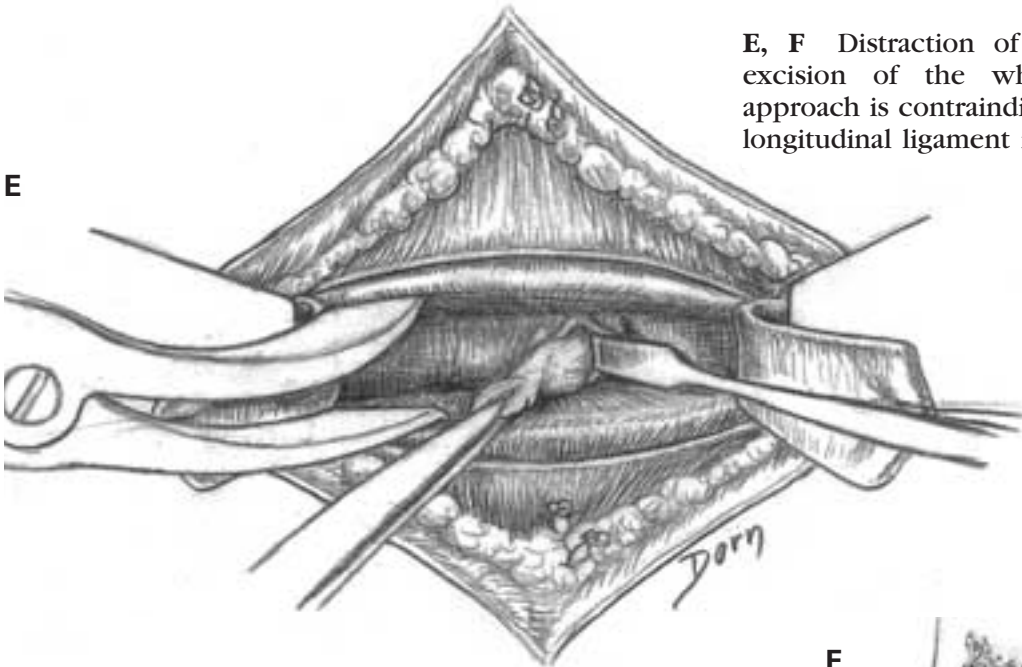


D Excision of the disc.

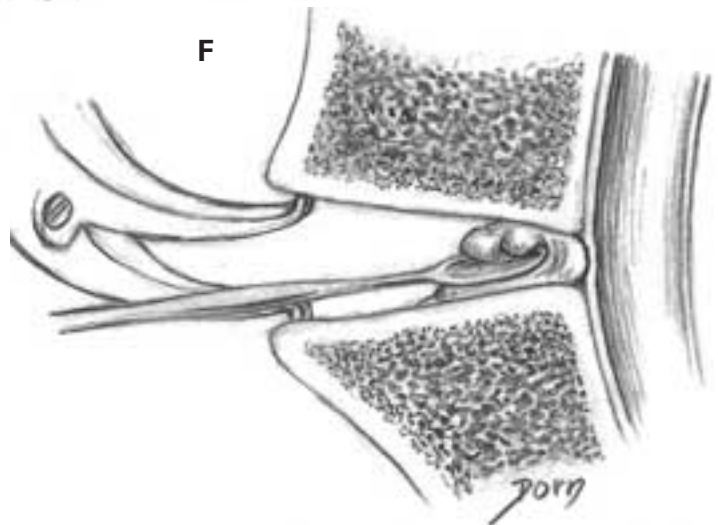


E, F Distraction of vertebral bodies allows excision of the whole disc. The anterior approach is contraindicated when the posterior longitudinal ligament is ruptured.

E



F



Upper limb surgery

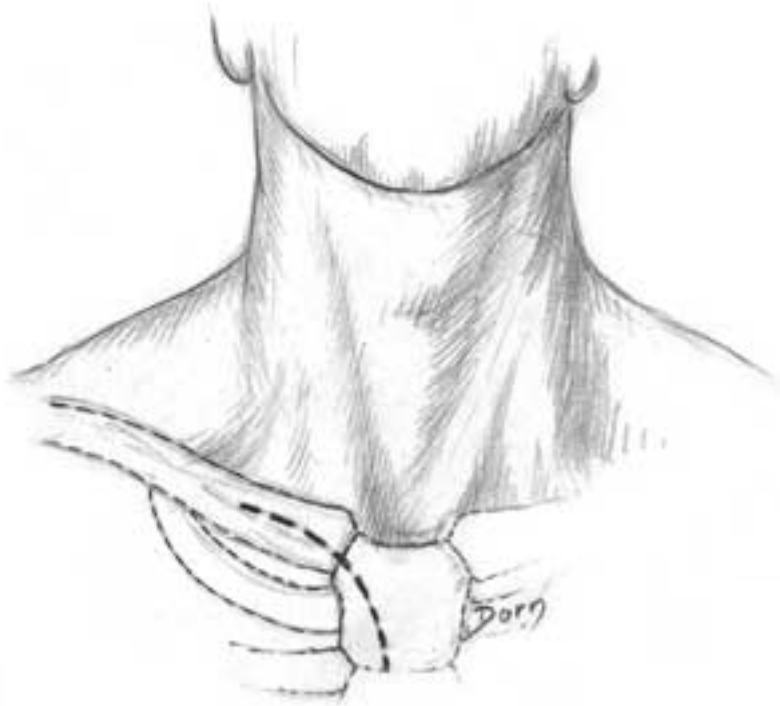
Surgery of the upper limb has increasingly gained interest over the past 20 years. This is due to the major development of the surgery of the hand, which is equally performed by orthopaedic and plastic surgeons. Moreover many recent advances have been made in the field of surgery of the shoul-

der and elbow, chiefly in relation to the possibilities offered by arthroscopy and prosthetic replacements. Thus, we have given some examples of surgery of the upper limb in a separate section instead of including them in the chapter on surgery of the hand and wrist.

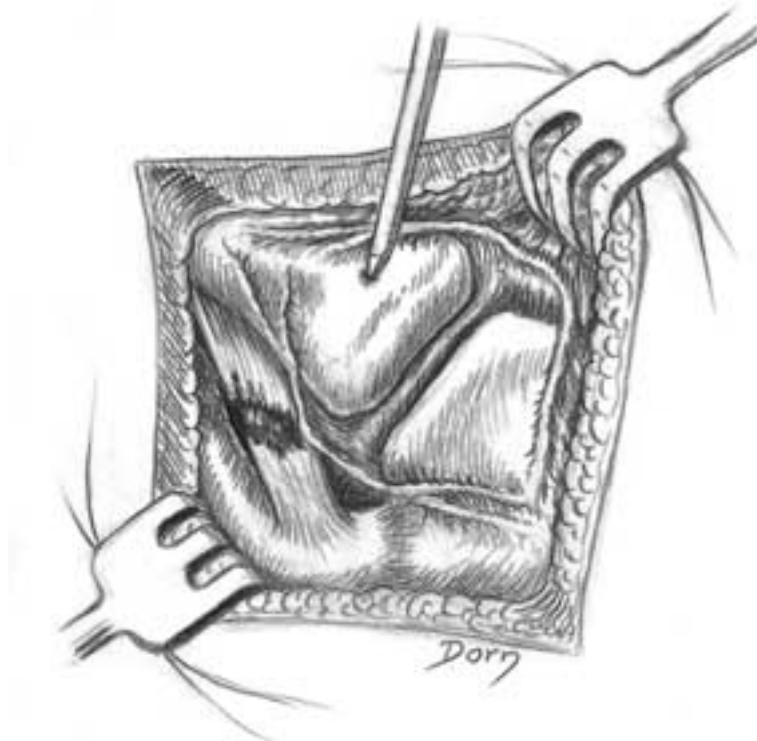Upper limb surgery

Sternoclavicular dislocation

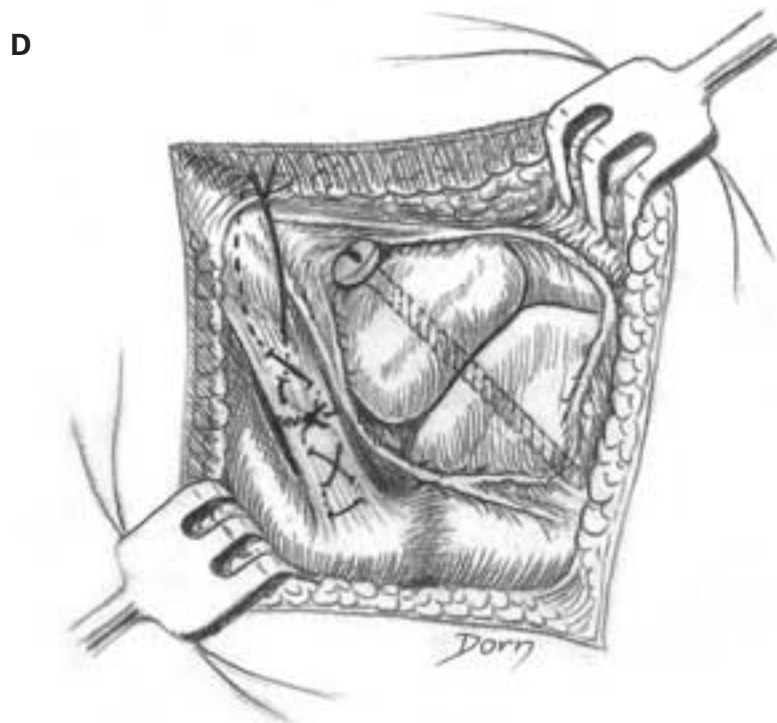
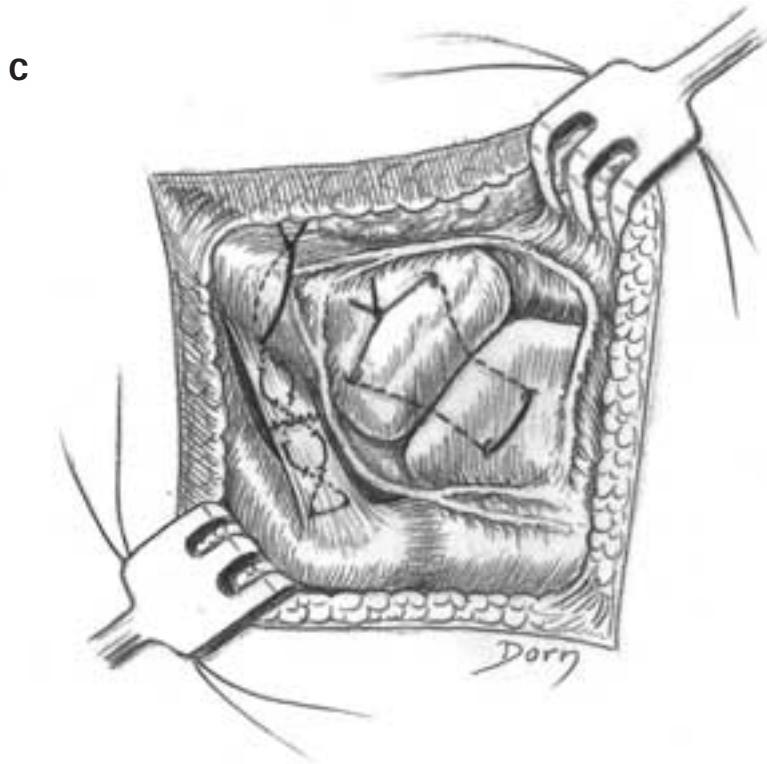
A Skin incision.



B The exposure of the sternoclavicular joint. Note the rupture of the costoclavicular ligament.



C, D Repair of the costoclavicular ligament and stabilisation by a frame or a screw.



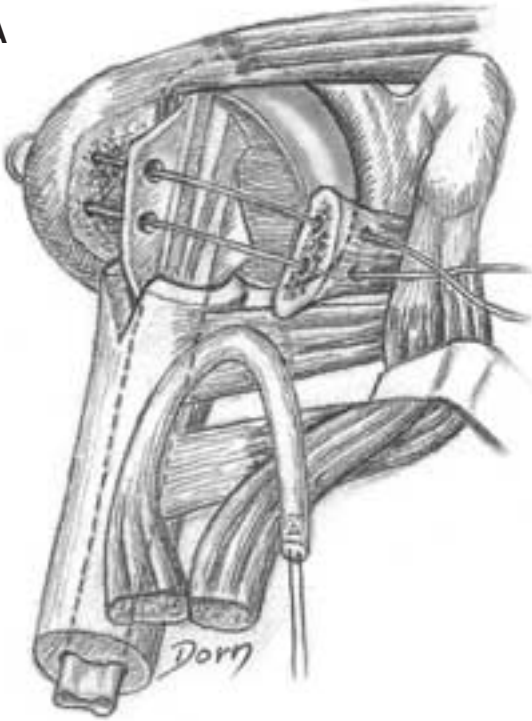
Upper limb surgery

Stabilisation of a shoulder prosthetic implant

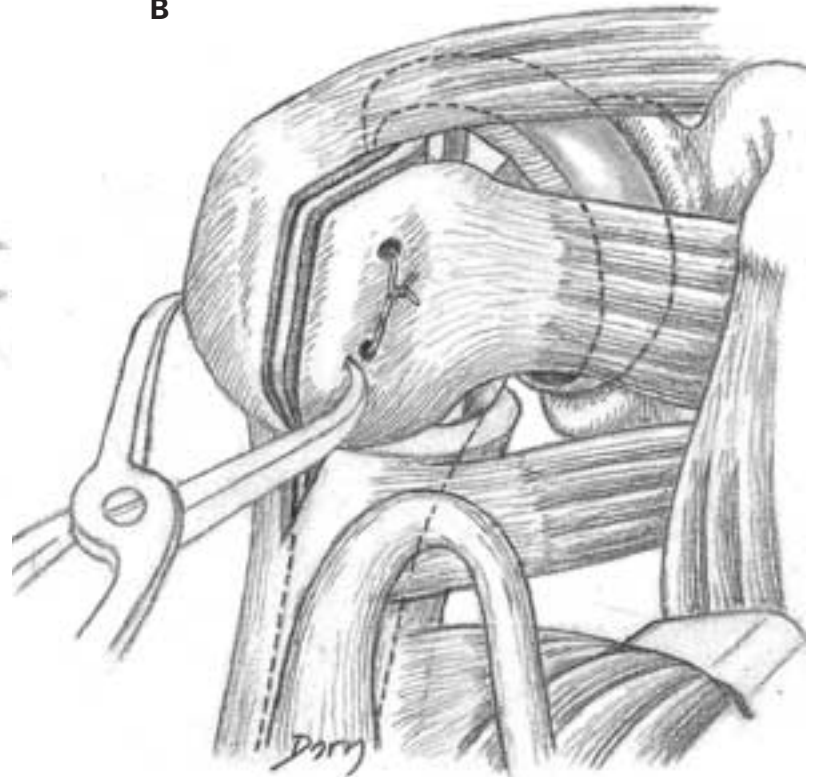
This type of implant is employed in comminutive fractures of the proximal extremity of the humerus.

A, B The prosthesis is put in place. The greater and the lesser tubercles are reduced on the prosthesis and firmly fixed.

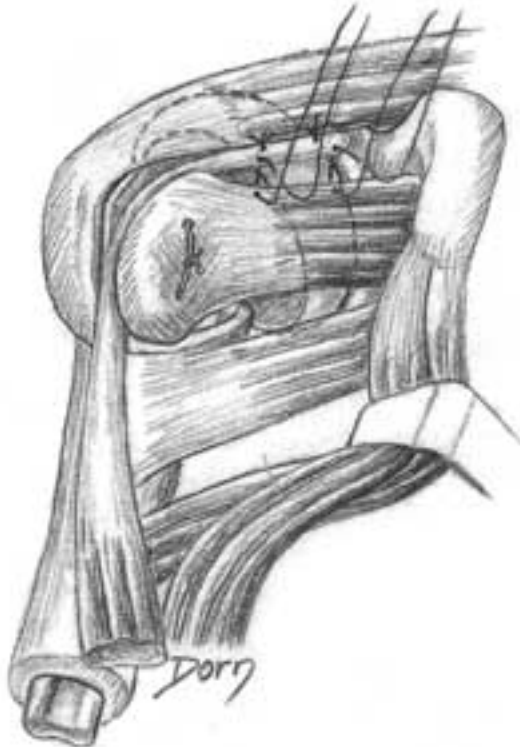
A



B



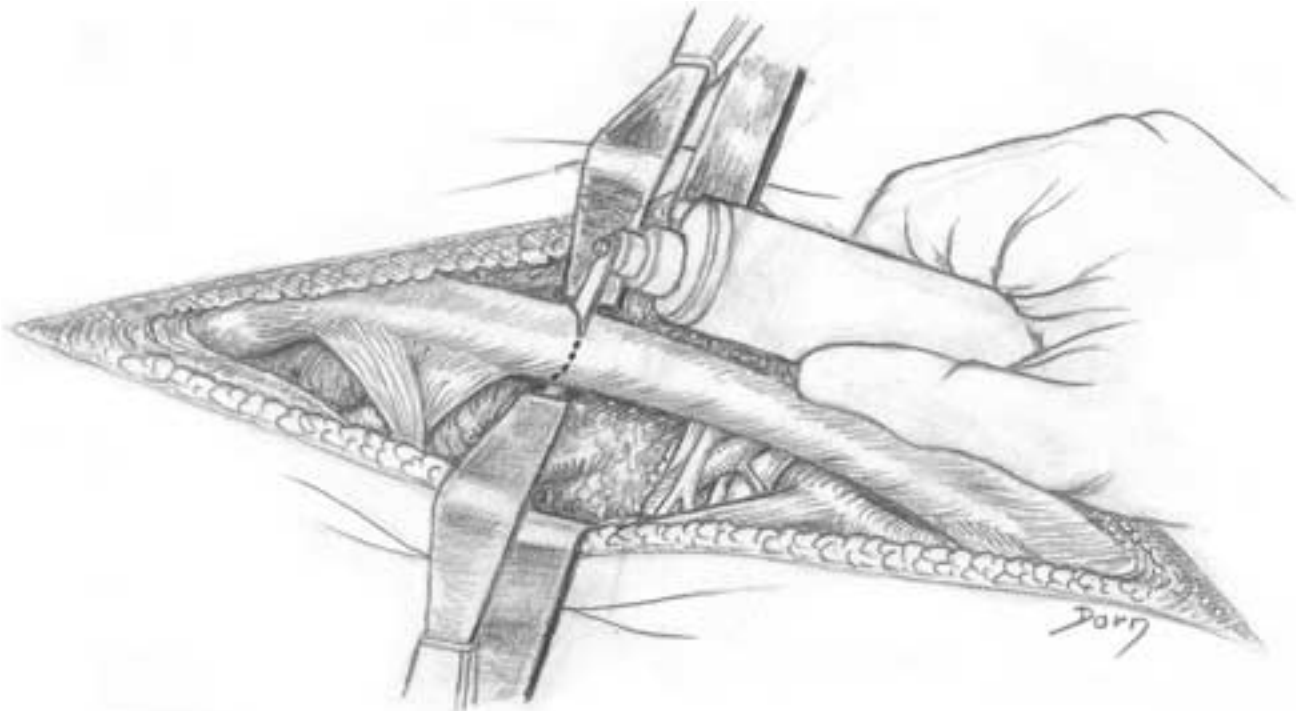
C The stability of the prosthesis is reinforced by the suture of the biceps tendon on the rotator cuff interval.



Cleidectomy

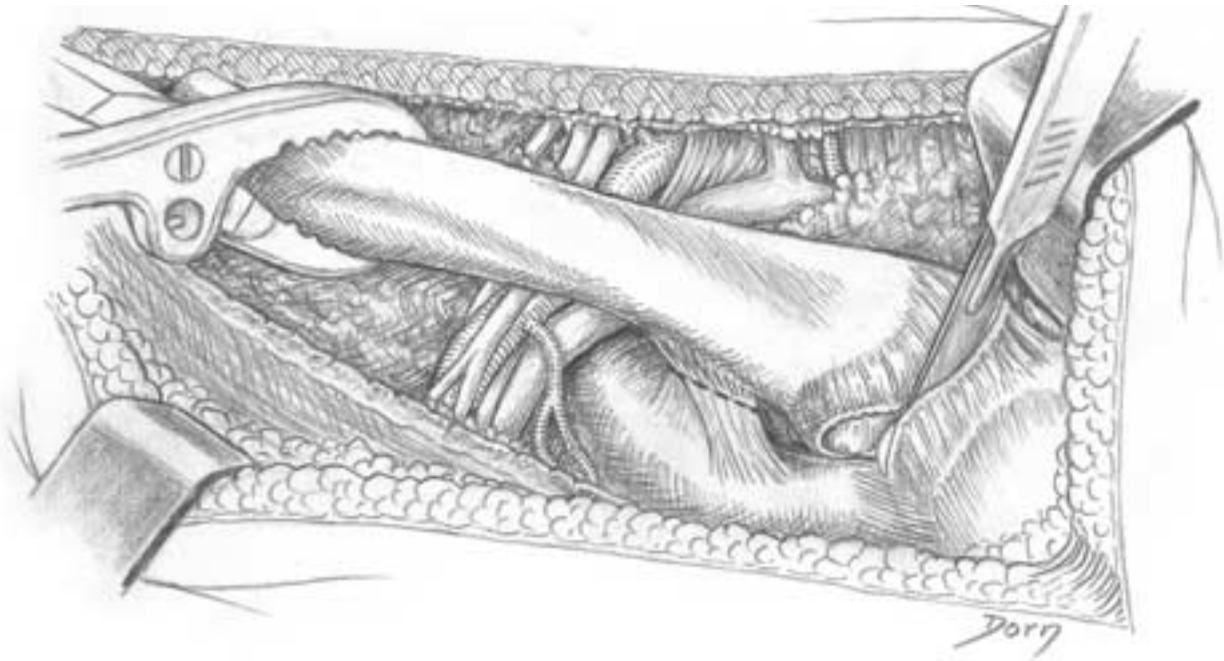
Excision of the clavicle is an uncommon procedure. It can be indicated in case of tumour.

A It is easier to remove the clavicle in two parts and the procedure begins by severing the clavicle. First all the muscle insertions are released.

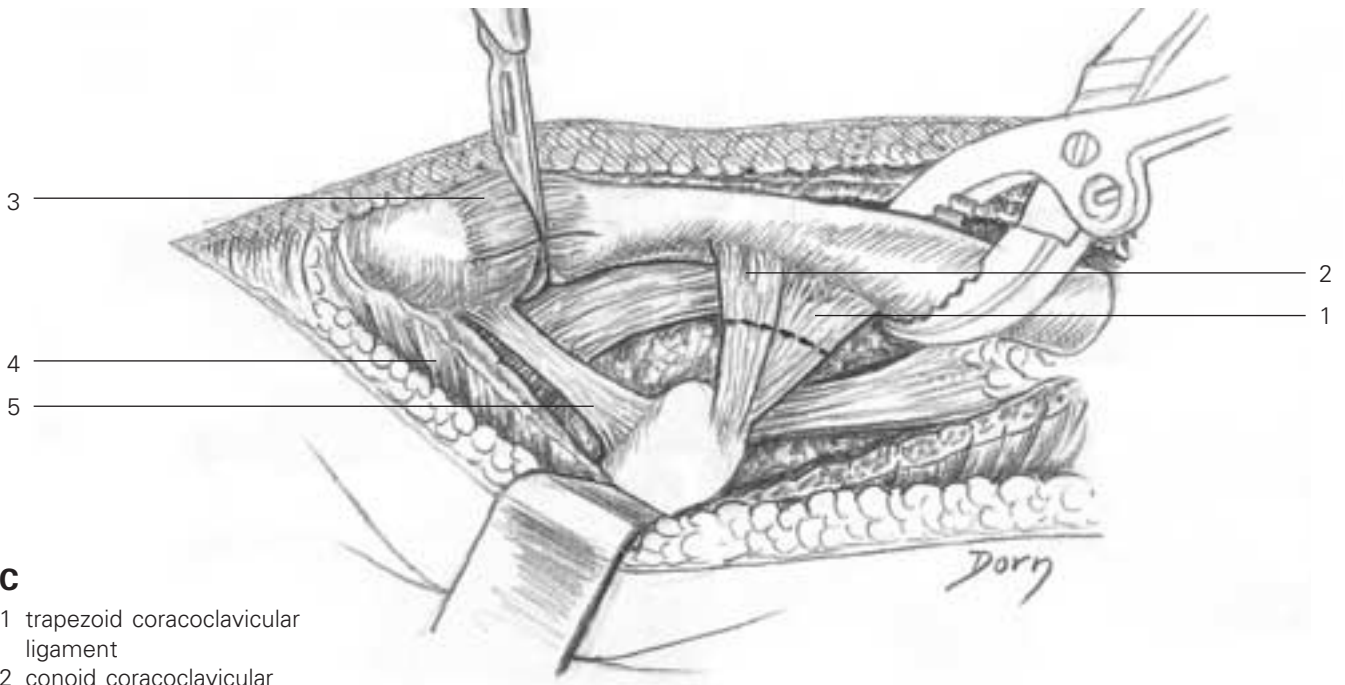


Upper limb surgery

B Then the medial portion is removed by cutting the costoclavicular ligament and opening the sternoclavicular joint.



C The lateral part is removed by cutting the coracoclavicular ligament and opening the acromioclavicular joint.

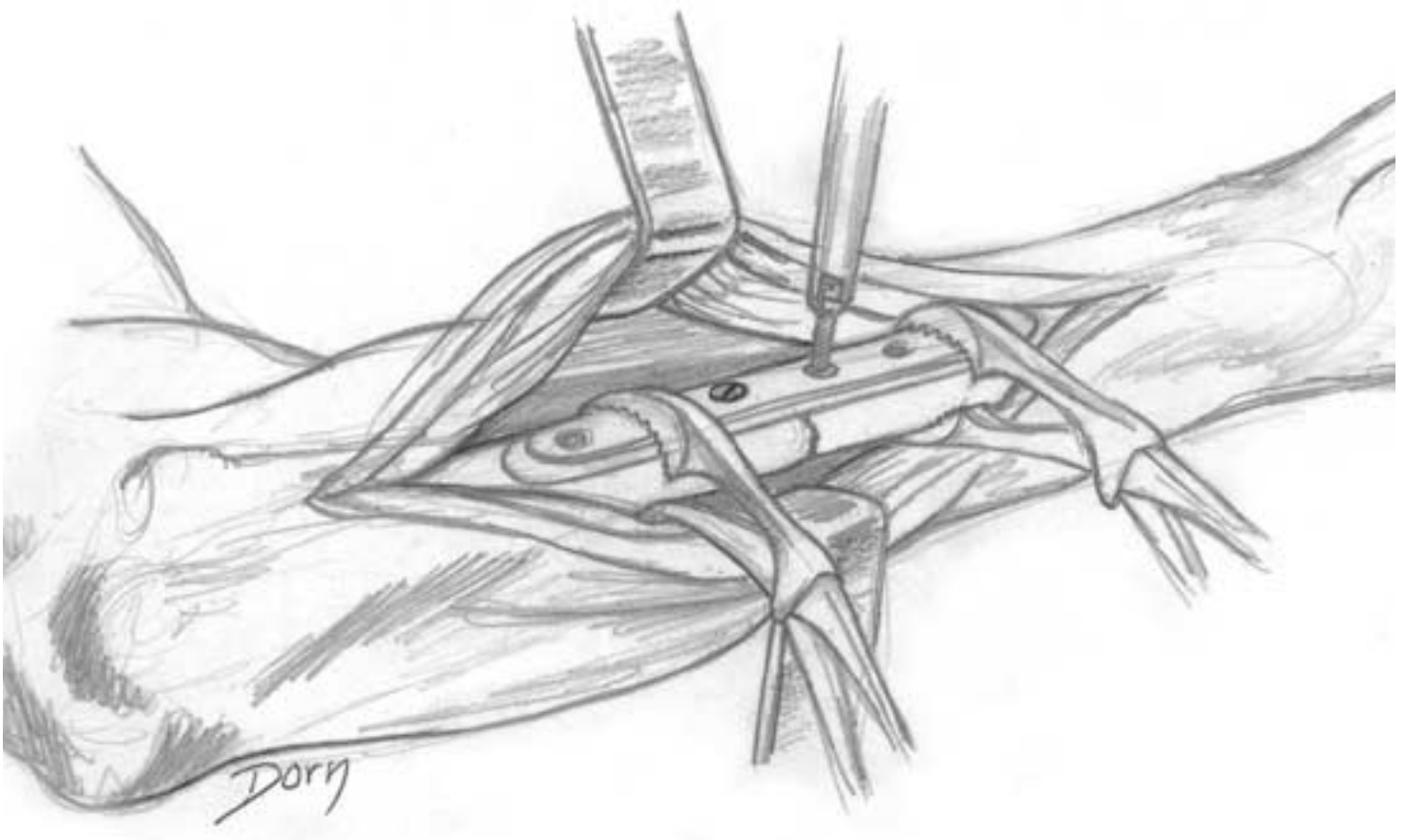


- C**
- 1 trapezoid coracoclavicular ligament
 - 2 conoid coracoclavicular ligament
 - 3 acromioclavicular capsule
 - 4 deltoid muscle
 - 5 coracoacromial ligament

Osteosynthesis of a fracture of the forearm

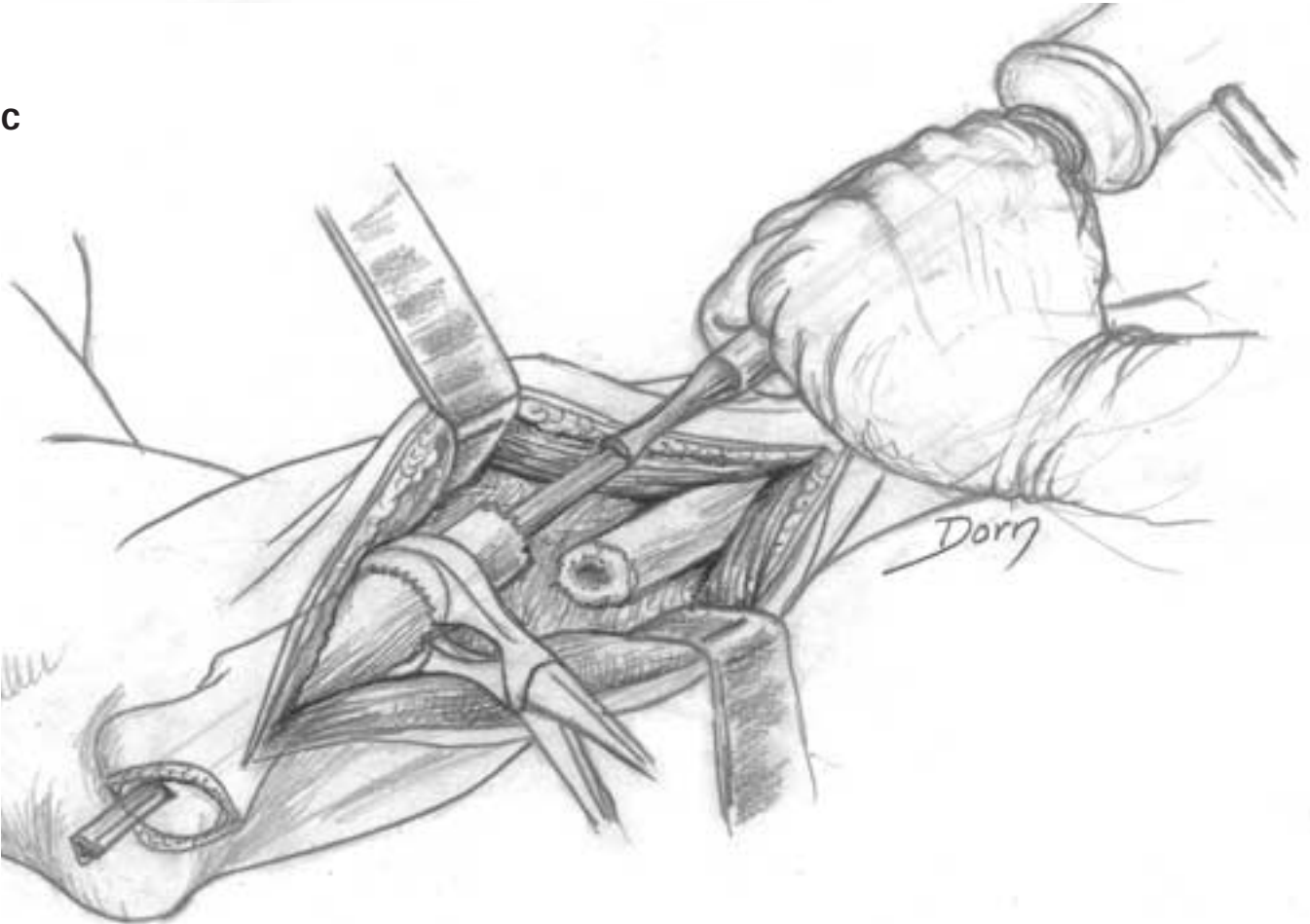
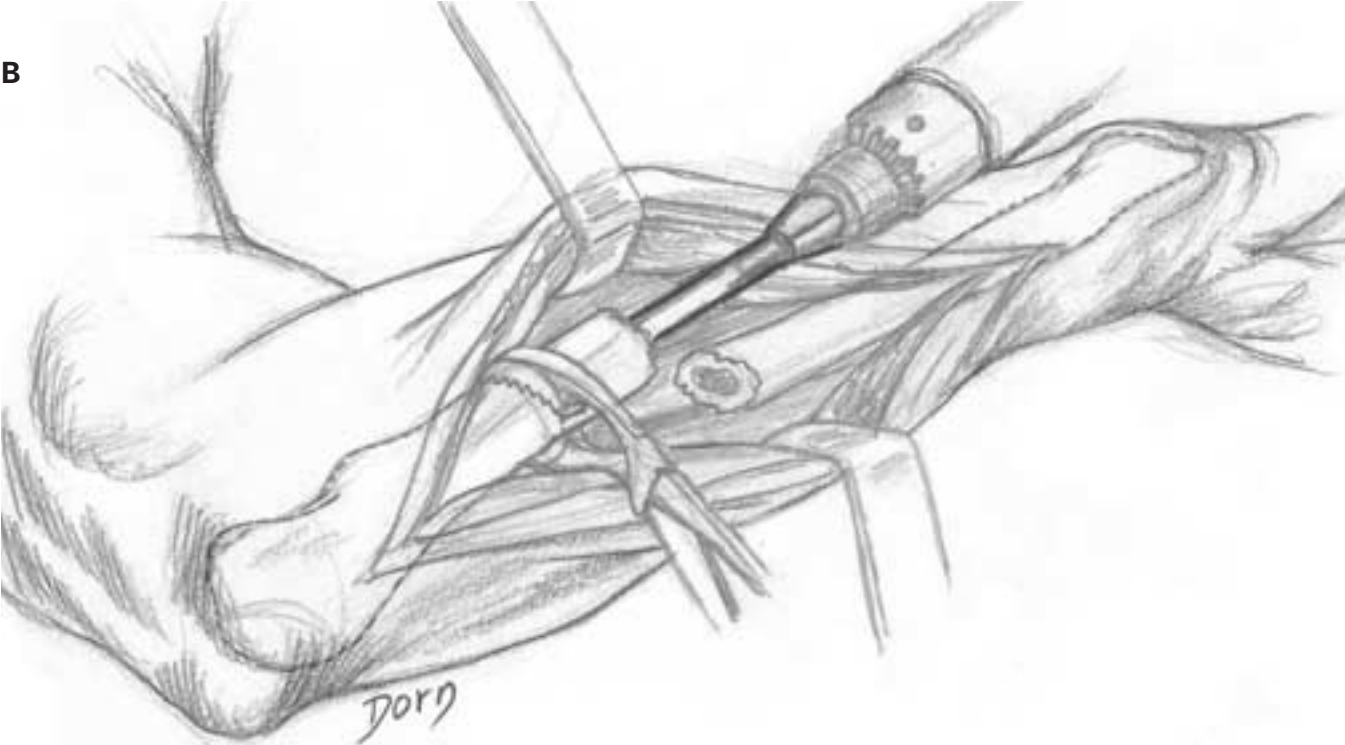
The following early series of drawings allows us to assess the evolution of Dorn's style. As a matter of fact, this technique was designed in 1970 for Merle d'Aubigné. Very few details are visible in the soft tissues and the shape of the bones is approximate.

A Fracture of the radius treated by a plate.



Upper limb surgery

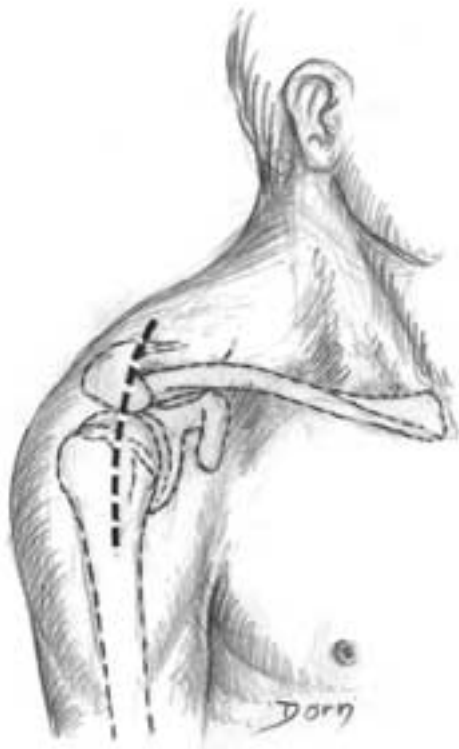
B, C The shaft of the ulna is reamed to put an intramedullar nail. The technique with exposure of the fracture site is obsolete.



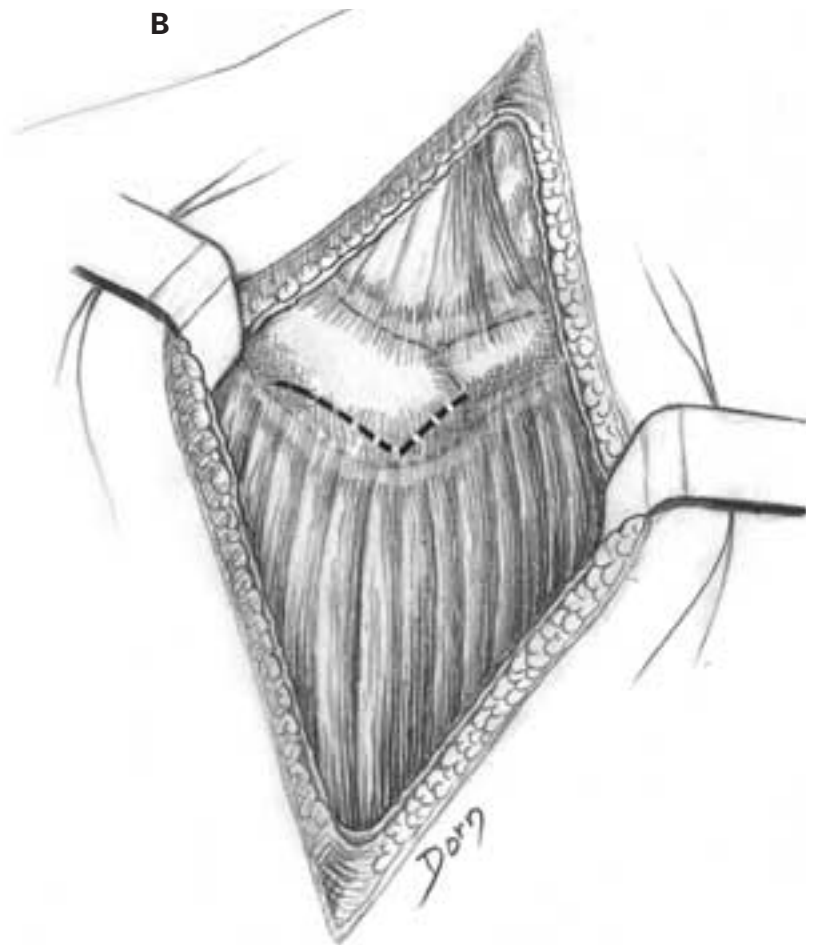
Surgical exposure of the shoulder

Anterior approach to the subacromial space

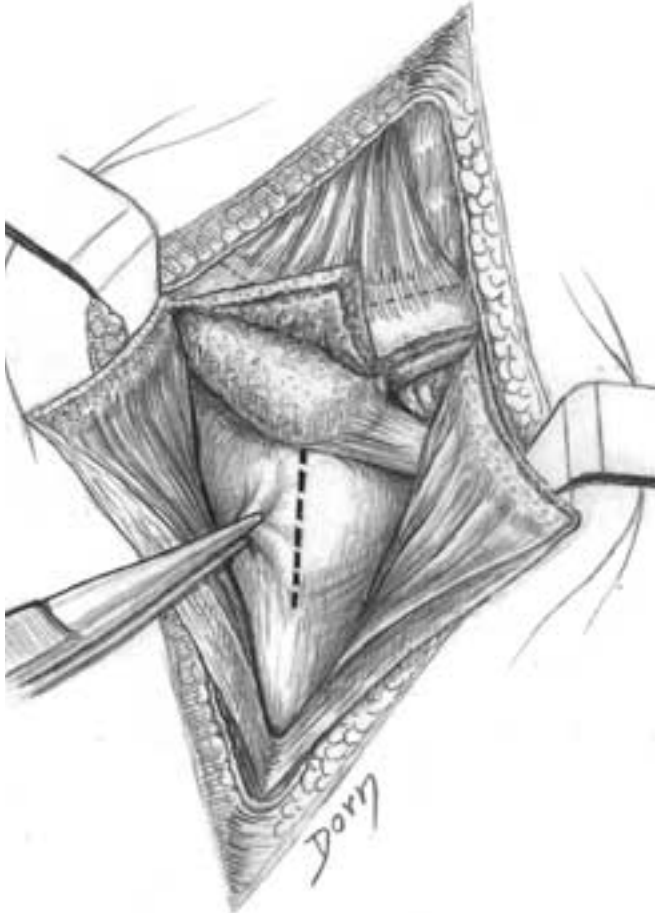
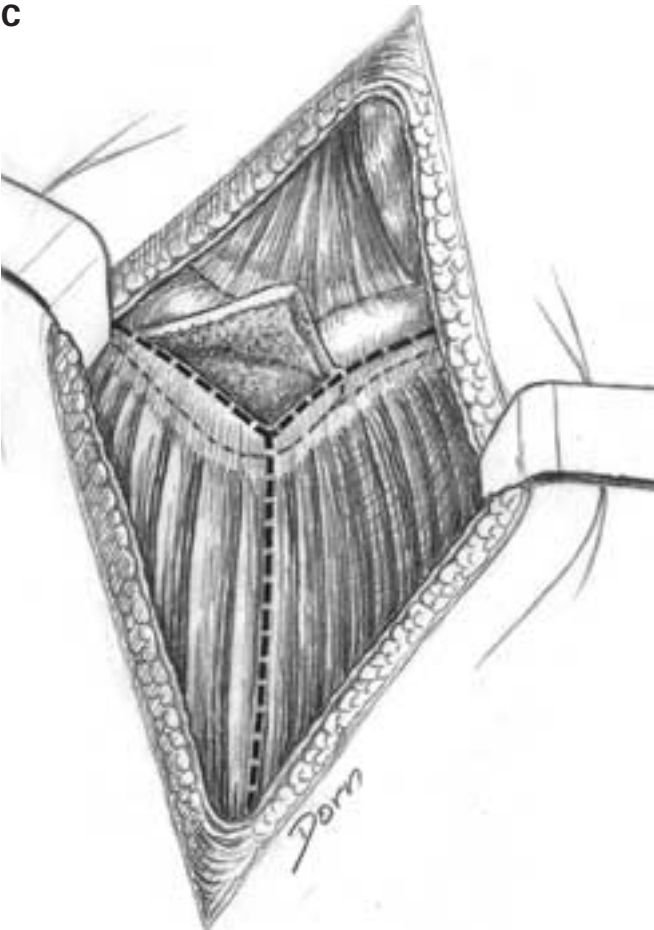
A Skin incision according to the bony landmarks. **B, C** The deltoid origin is raised from the acromion and lateral clavicle.



B



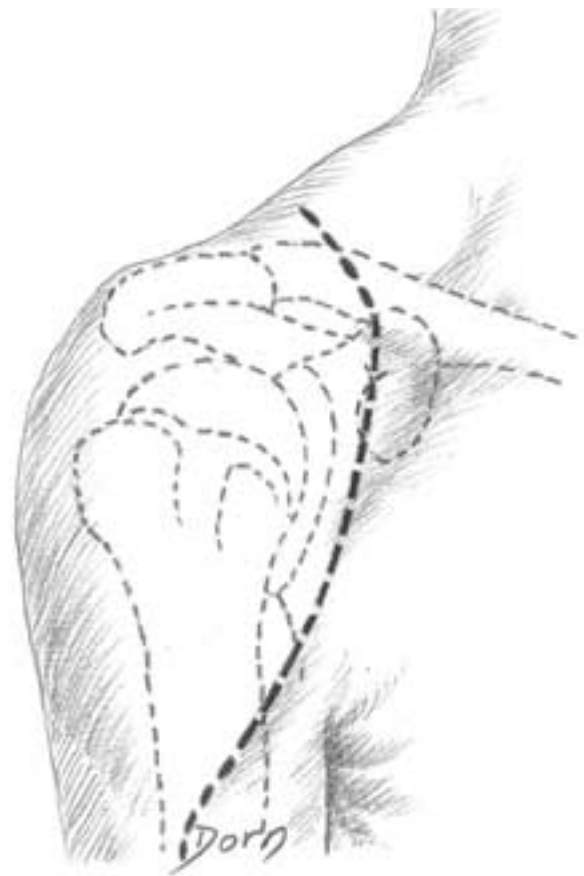
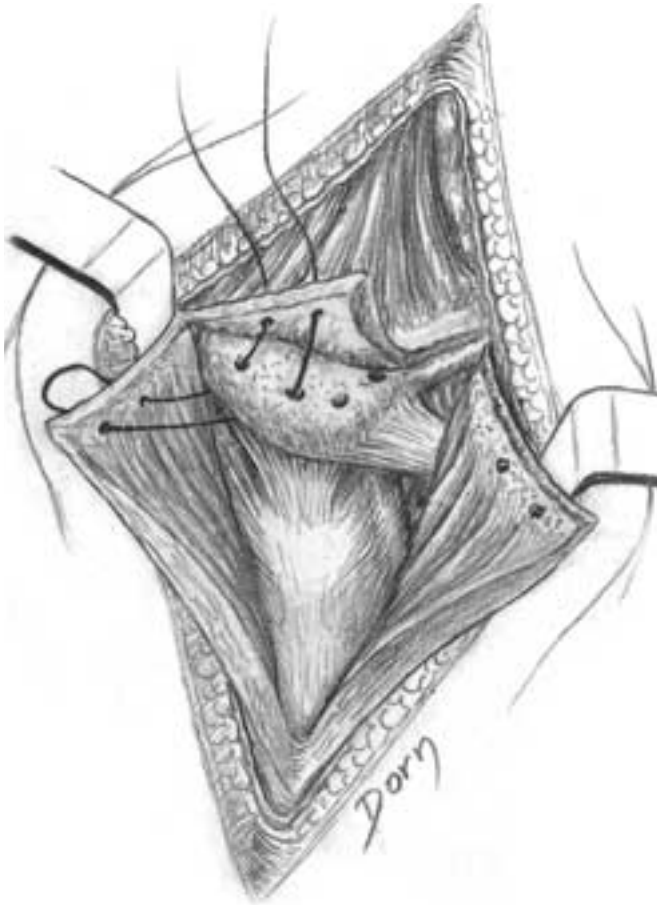
D Exposure and incision of the subdeltoid bursa.



E Musculoperiosteal flaps are reinserted by fixation to the bone.

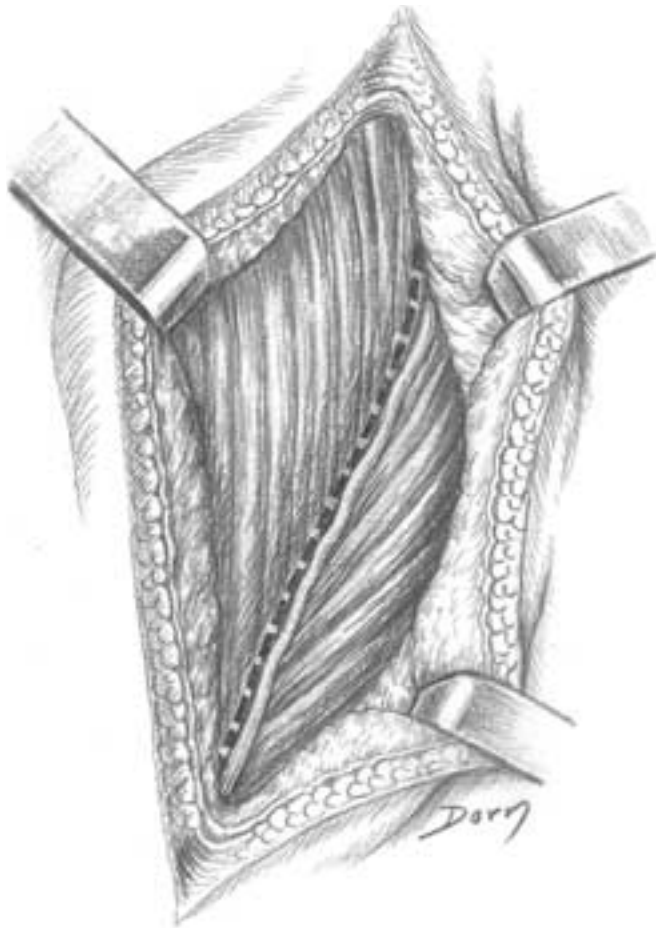
Anterior approach to the glenohumeral joint

A Skin incision.



Upper limb surgery

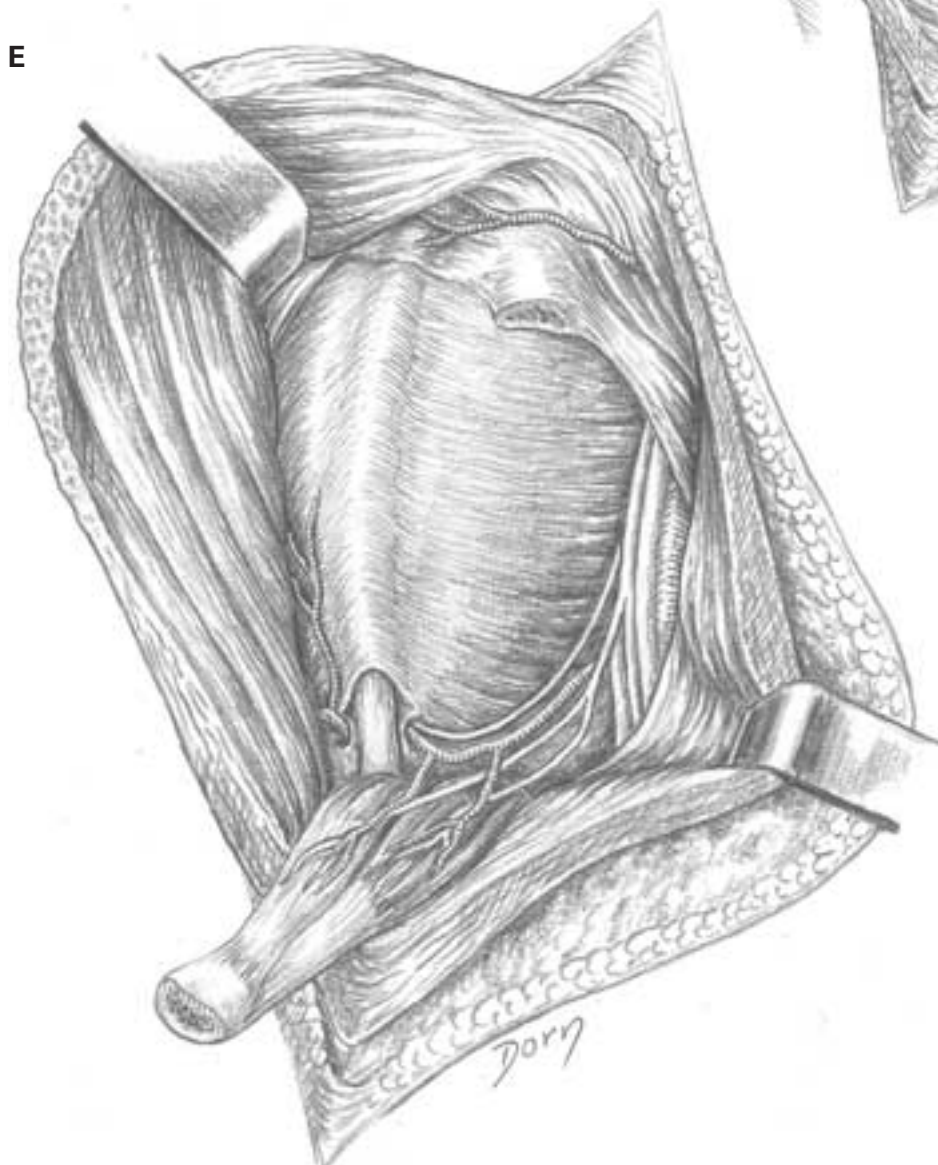
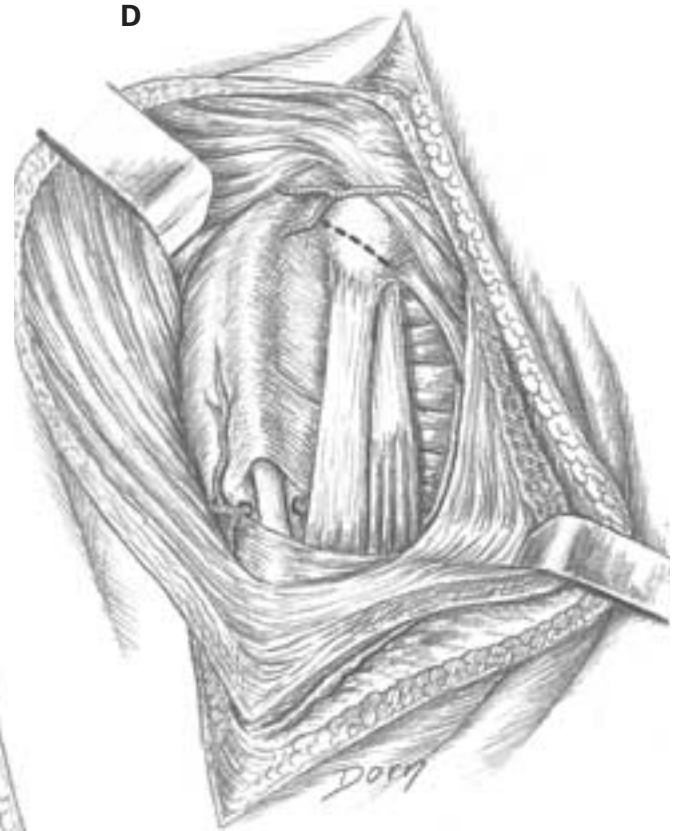B The deltopectoral groove is opened.



C Exposure of the coracobiceps by retracting the deltoid and the pectoralis major muscles.

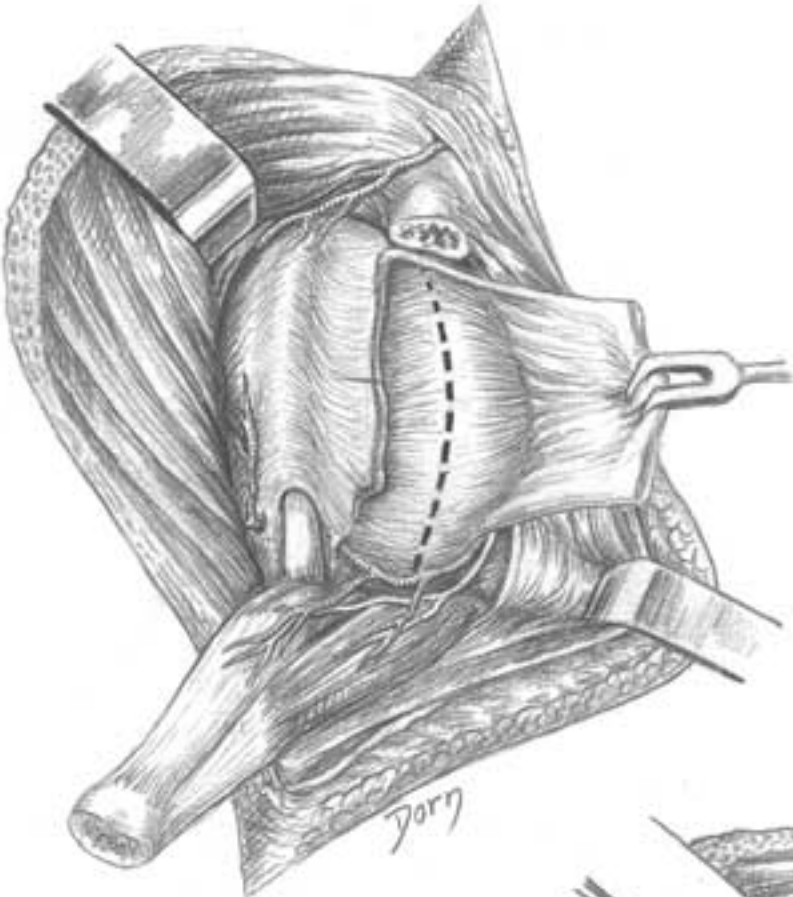


D, E The tip of the coracoid process is osteotomised. The coracobiceps is retracted, exposing the subscapularis muscle.

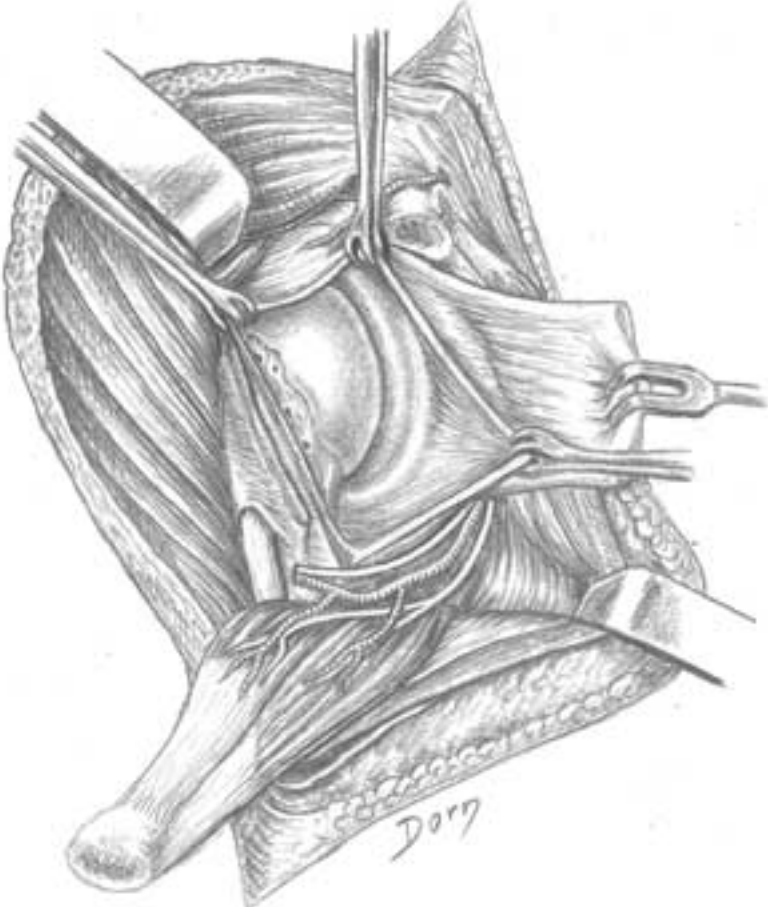


Upper limb surgery

F The tendon of the subscapularis is severed and retracted. Exposure of the capsule.



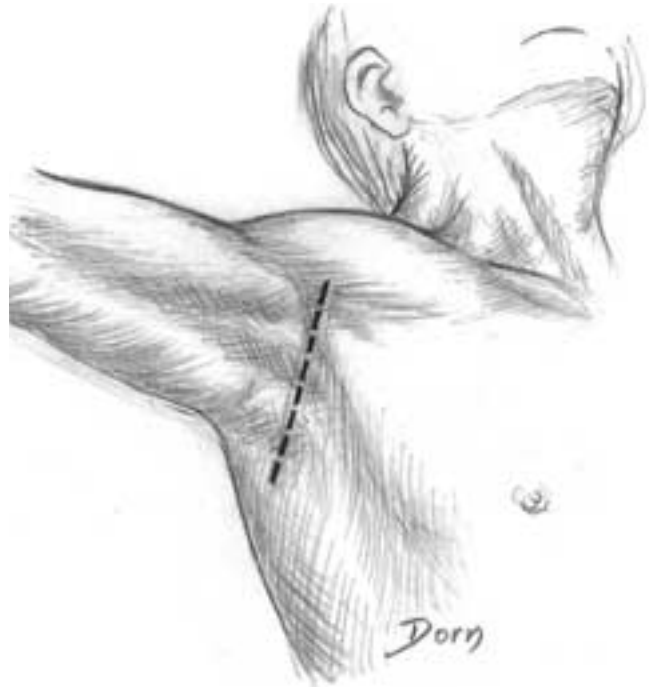G The capsule is opened.



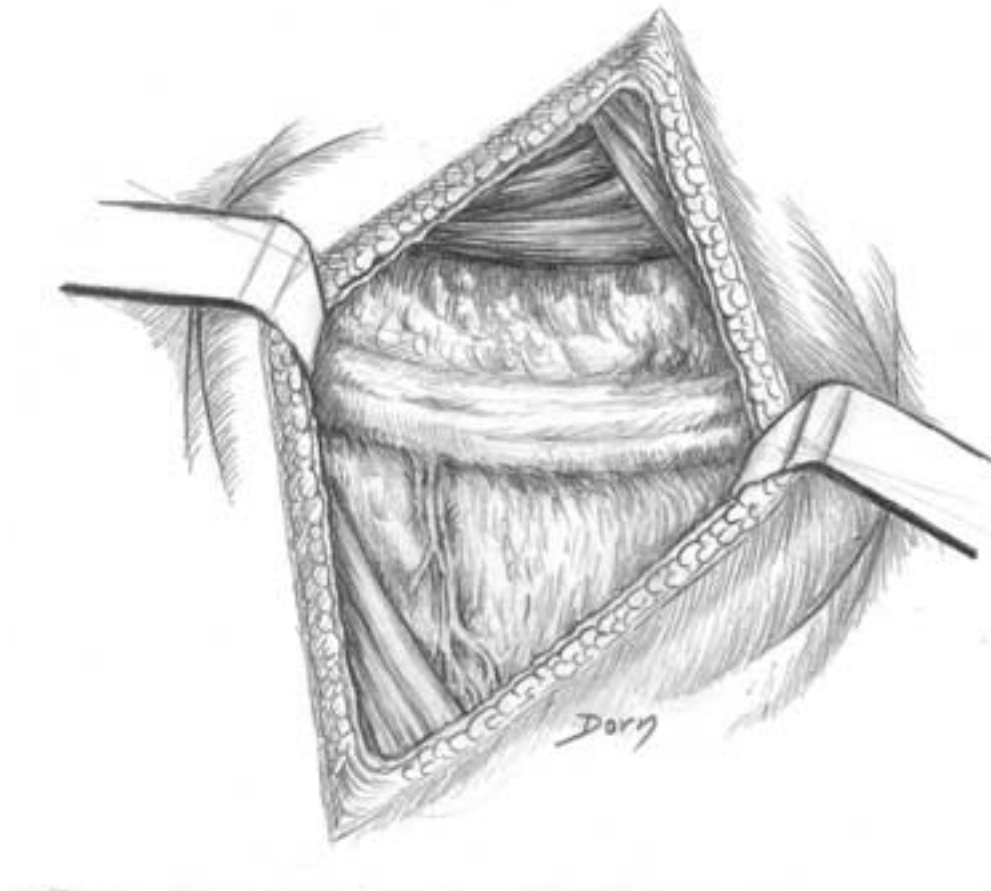
Axillary approach to the glenohumeral joint

Although rarely used because of the dissection of the neurovascular pedicles, this approach has the main advantage of a cosmetically acceptable scar.

A Skin incision.

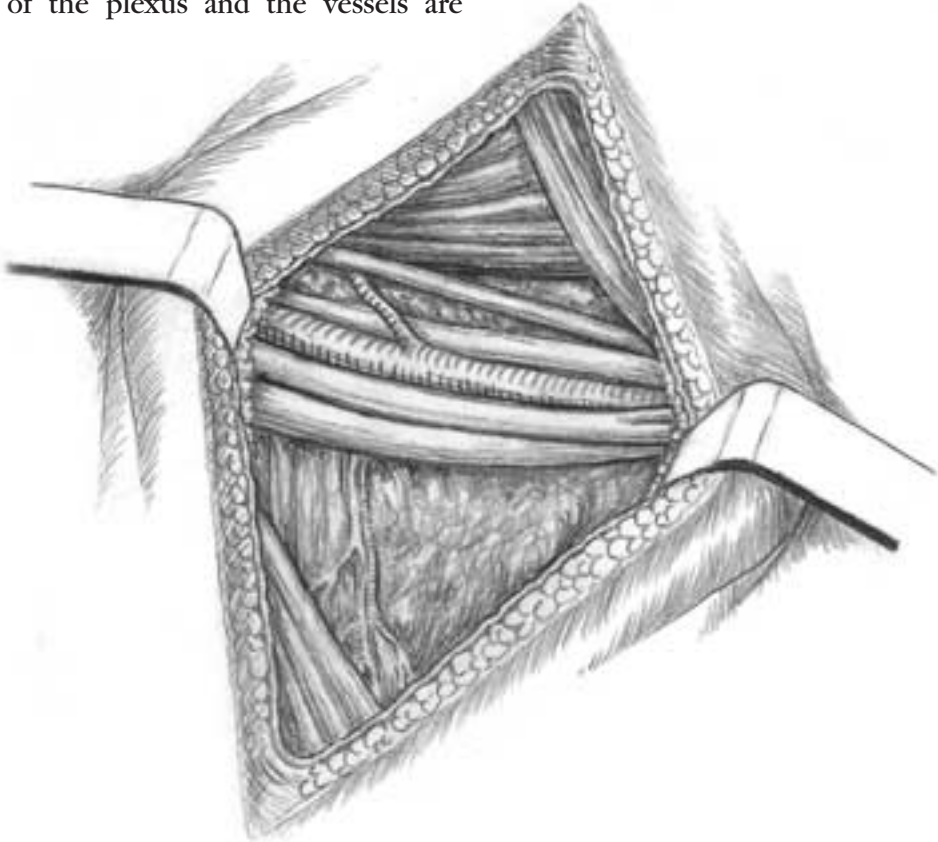


B The neurovascular bundle is lying in the axillary fat.

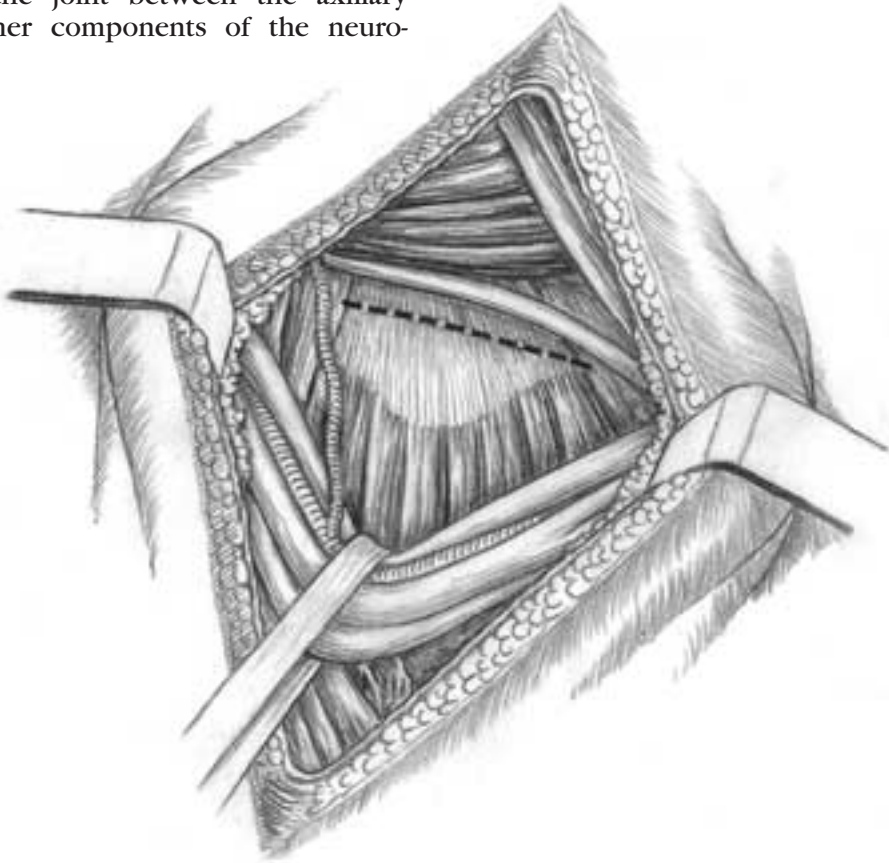


Upper limb surgery

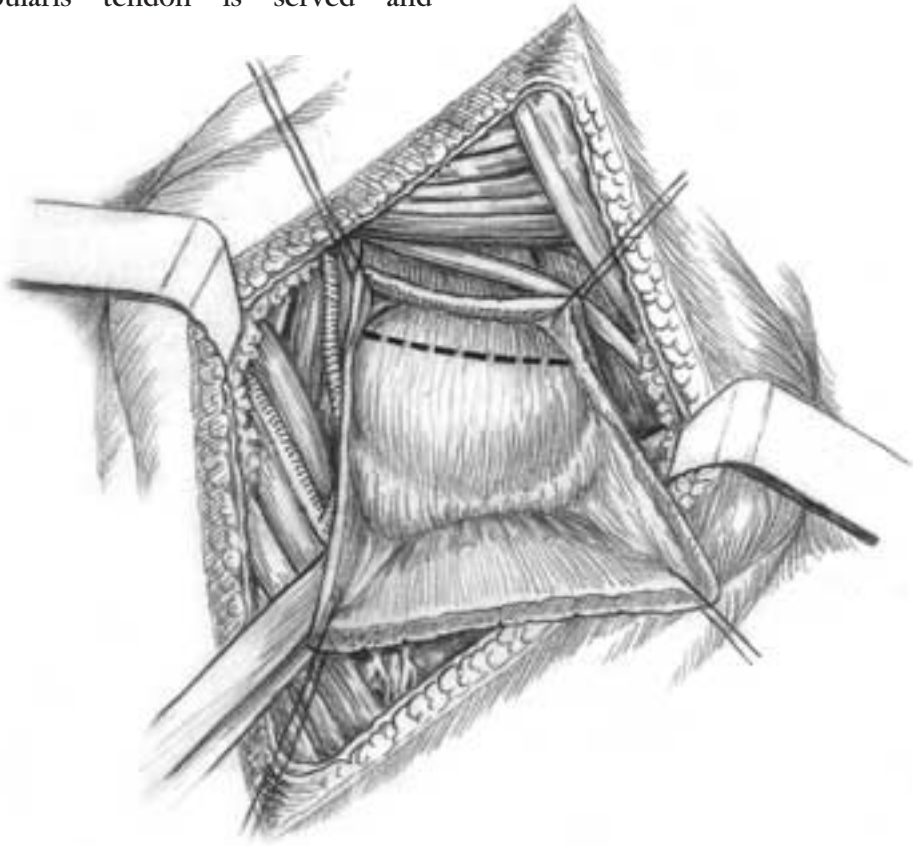
C The cords of the plexus and the vessels are visible.



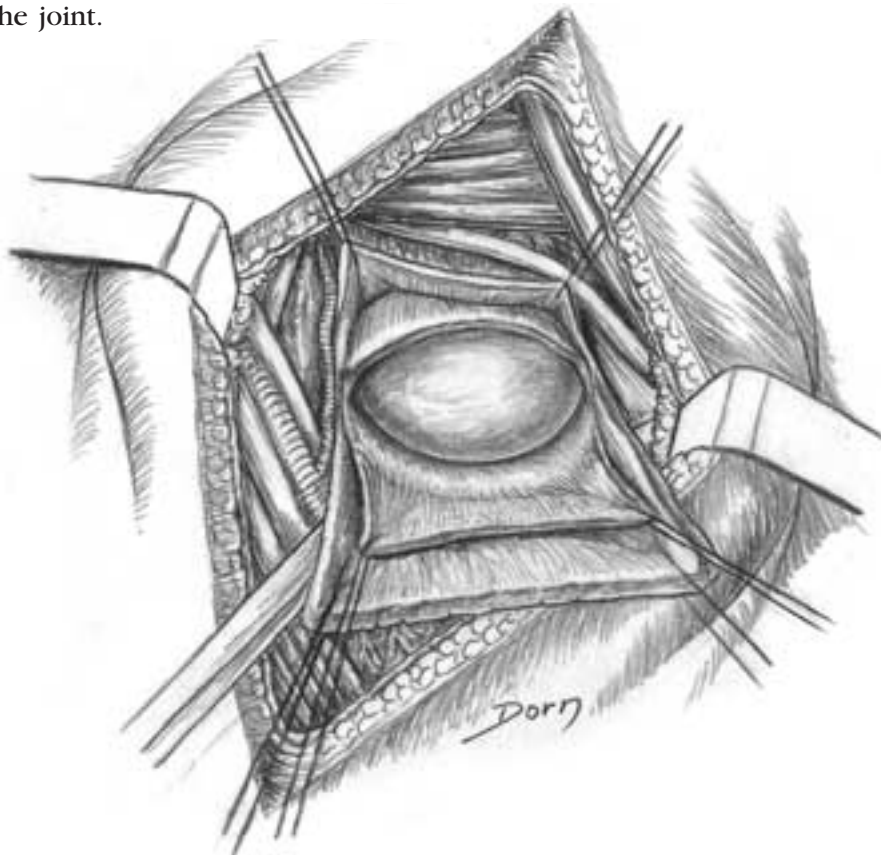
D Approach to the joint between the axillary nerve and the other components of the neurovascular bundle.



E The subscapularis tendon is served and retracted.



F Exposure of the joint.

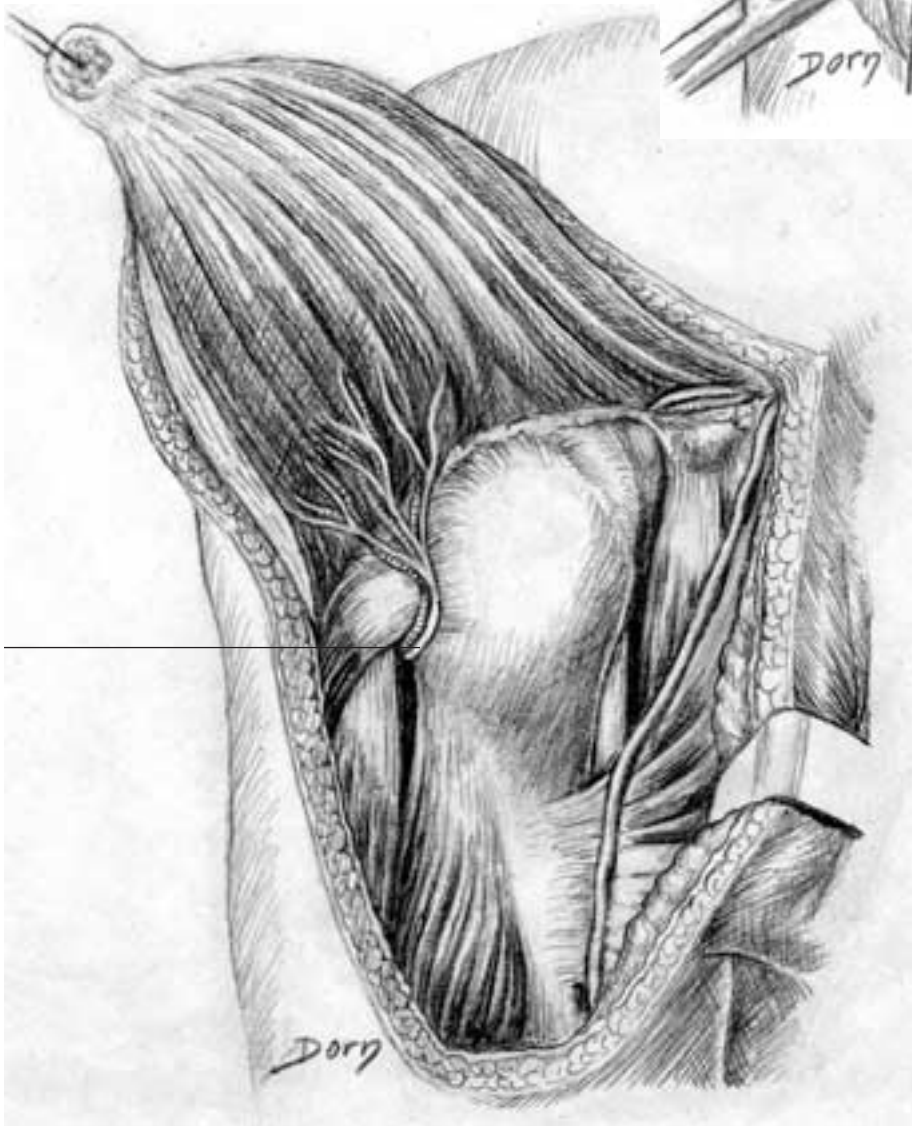
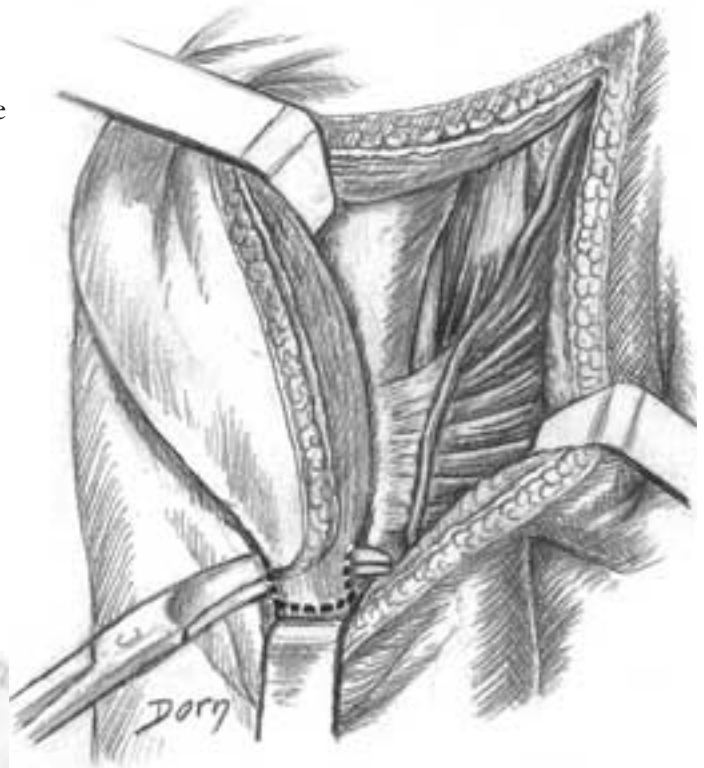


Upper limb surgery

Subdeltoid approach to the proximal metaphysis of the humerus

This approach is rarely used. Its indications are tumours and malunited fractures.

A The skin incision has a U shape.



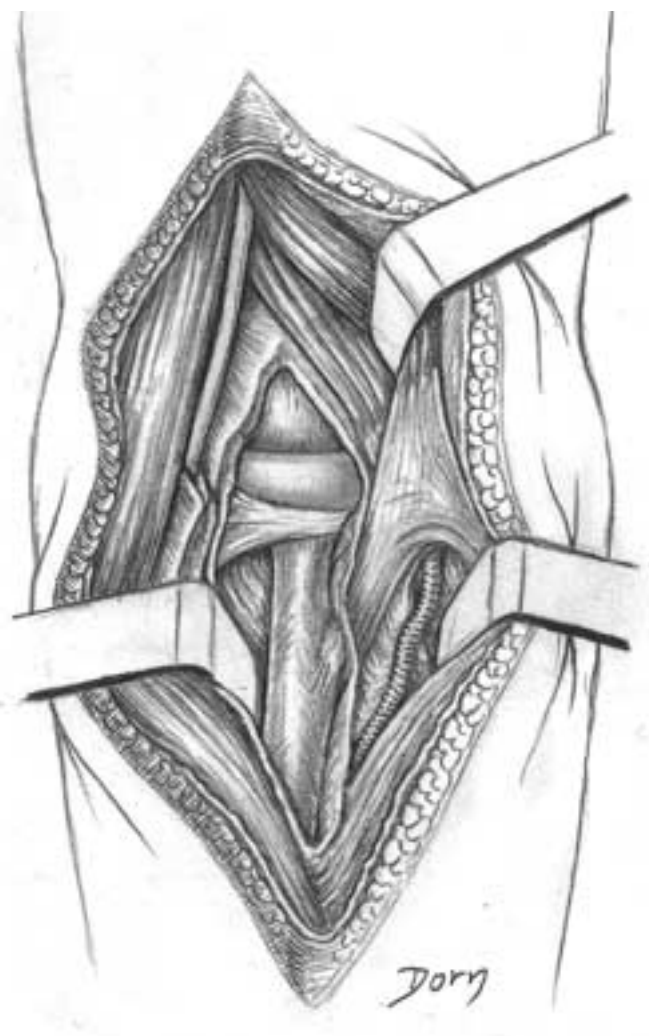
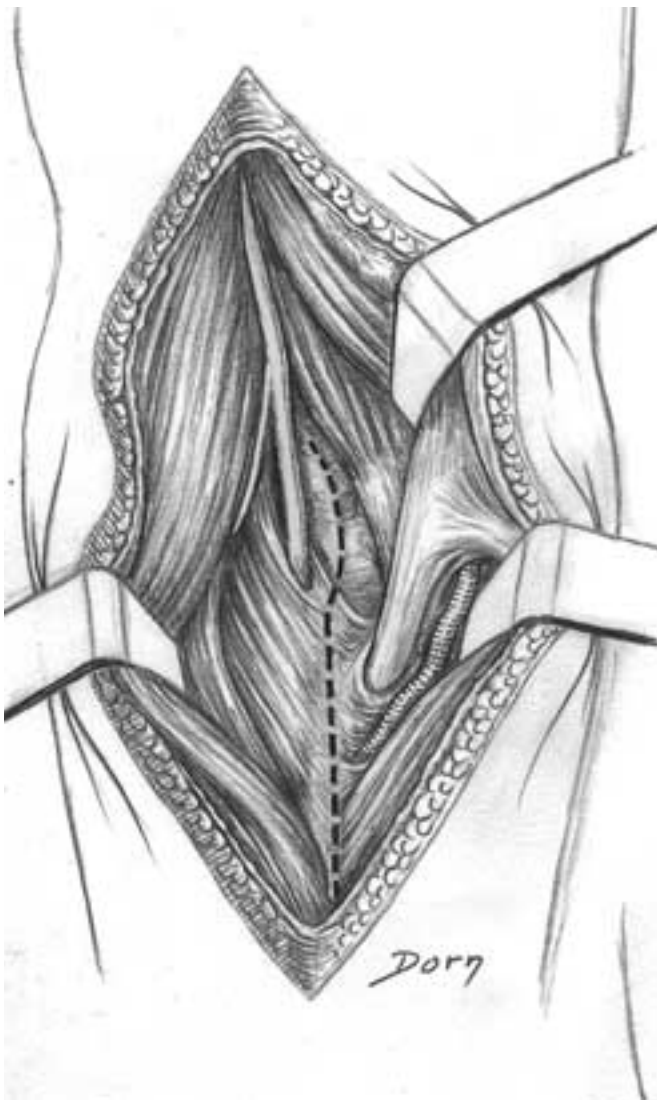B The distal insertion of the deltoid is released with a bone block. the skin flap and the deltoid are retracted *en bloc*.

1 axillary nerve

Anterior approach to the proximal third of the radius

A The approach is made with the forearm in supination. the brachioradialis muscle is retracted laterally exposing the two branches of the radial nerve and the supinator muscle. The biceps are retracted medially. The incision is made medially to the supinator and laterally to the biceps tendon.

B Exposure of the humeroradial joint and the proximal third of the radius.



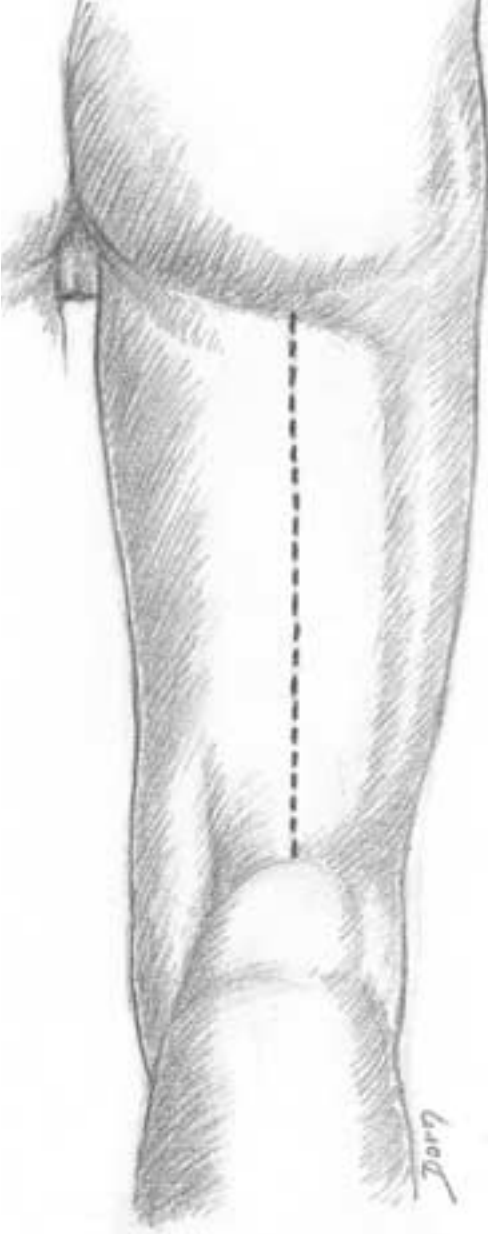
Lower limb surgery

The lower extremity is traditionally an important part of orthopaedic surgery; however, it is also relevant to vascular surgeons. We will survey the following: anatomy, reconstructive surgery of the knee and some approaches to the hip and the foot.

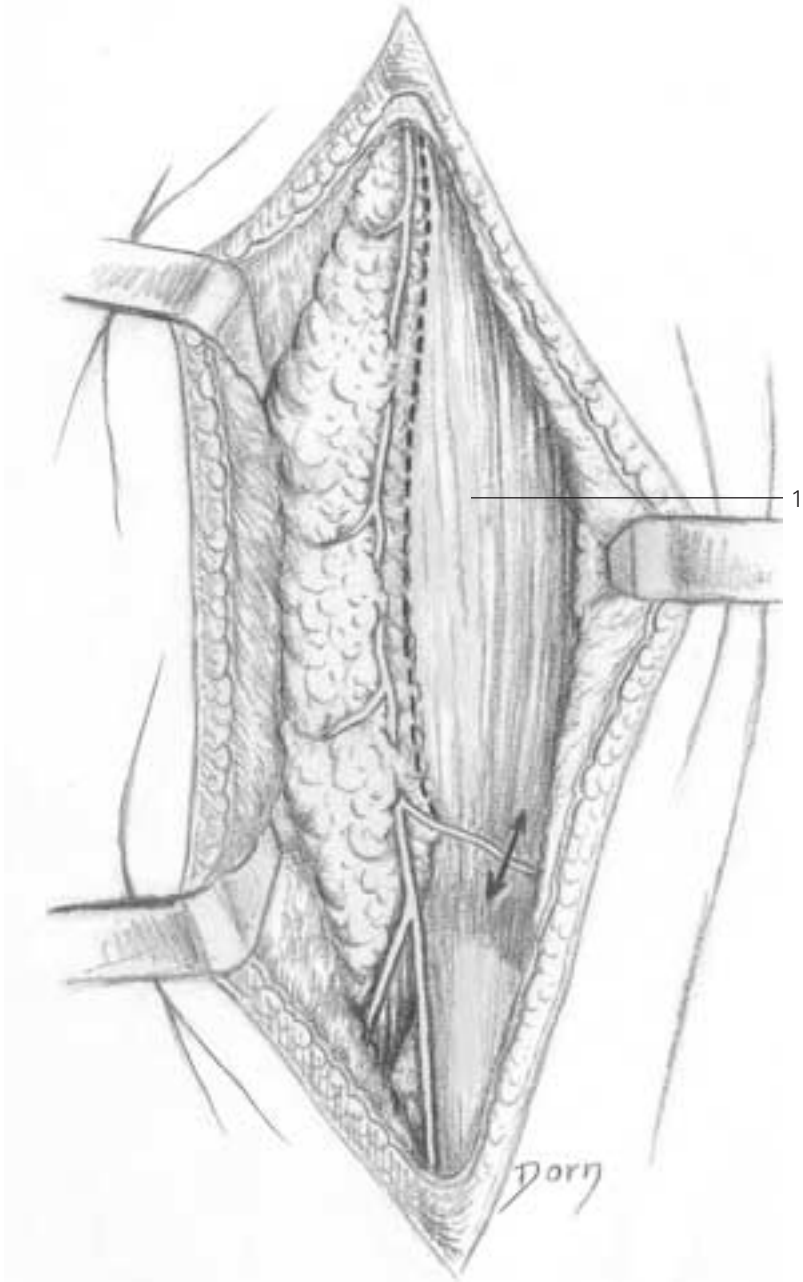
Anatomy

Anatomy of the posterior approach to the femoral shaft

A Skin incision.

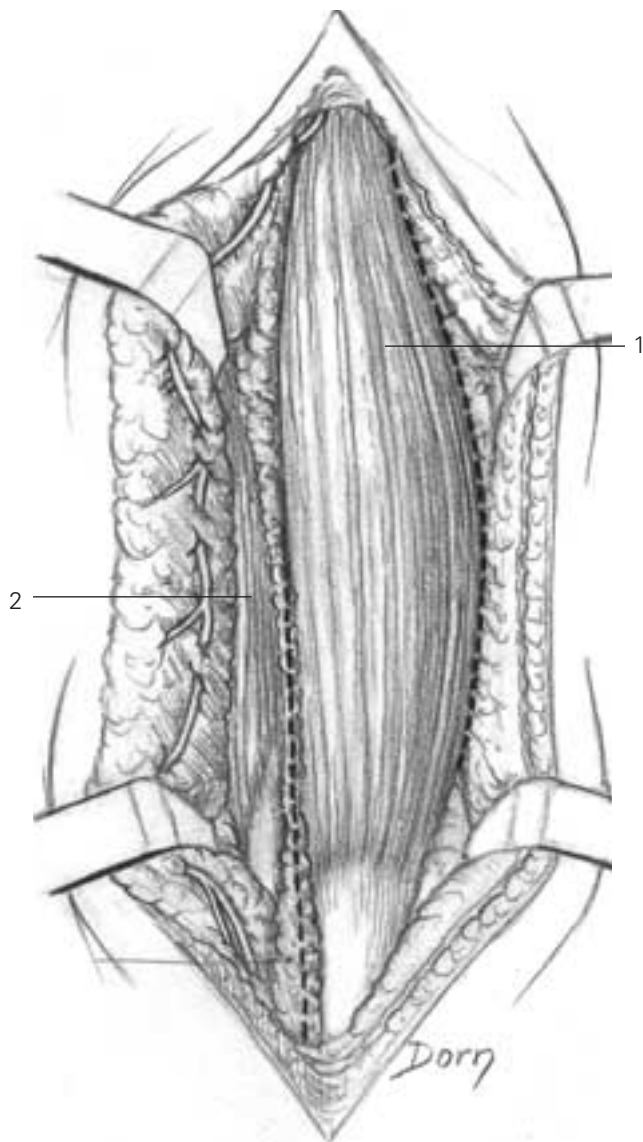


B Identification of the posterior femoral cutaneous nerve.



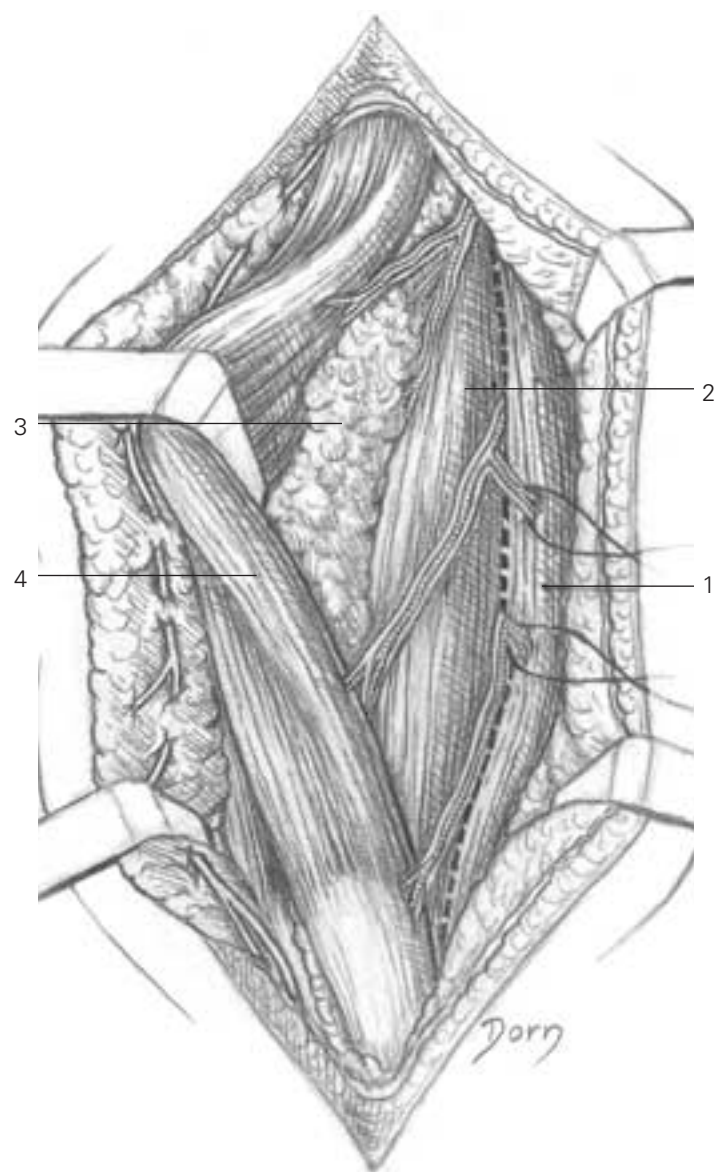
B
1 biceps femoris

C Approach between biceps and vastus lateralis. The lower part of the biceps is released from the semitendinosus.



C
 1 biceps femoris
 2 semitendinosus

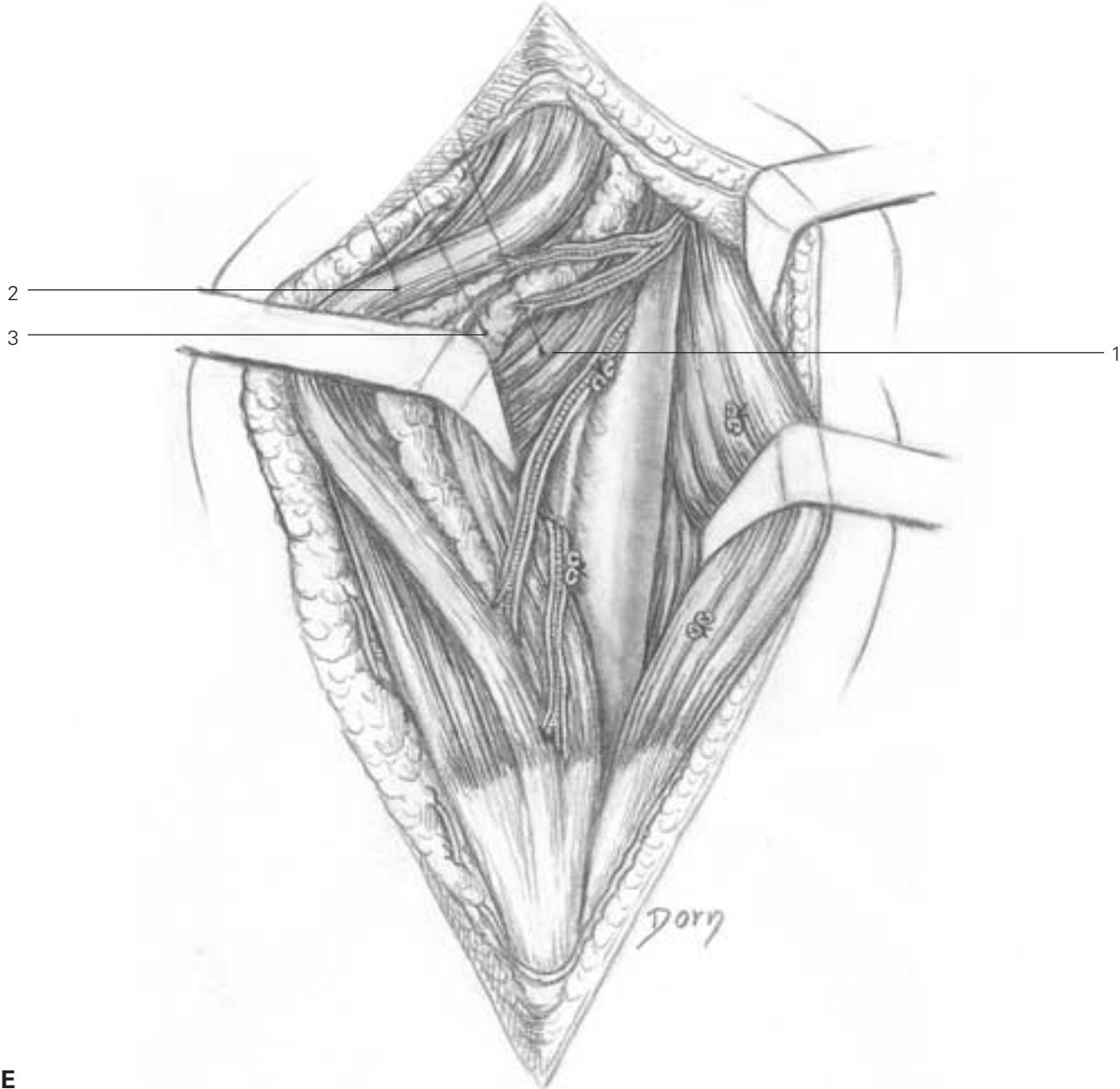
D The long head of biceps femoris is retracted medially; the plane between the short head and vastus lateralis is developed.



D
 1 vastus lateralis
 2 short head of biceps femoris
 3 fatty tissue containing sciatic nerve
 4 long head of biceps femoris

Lower limb surgery

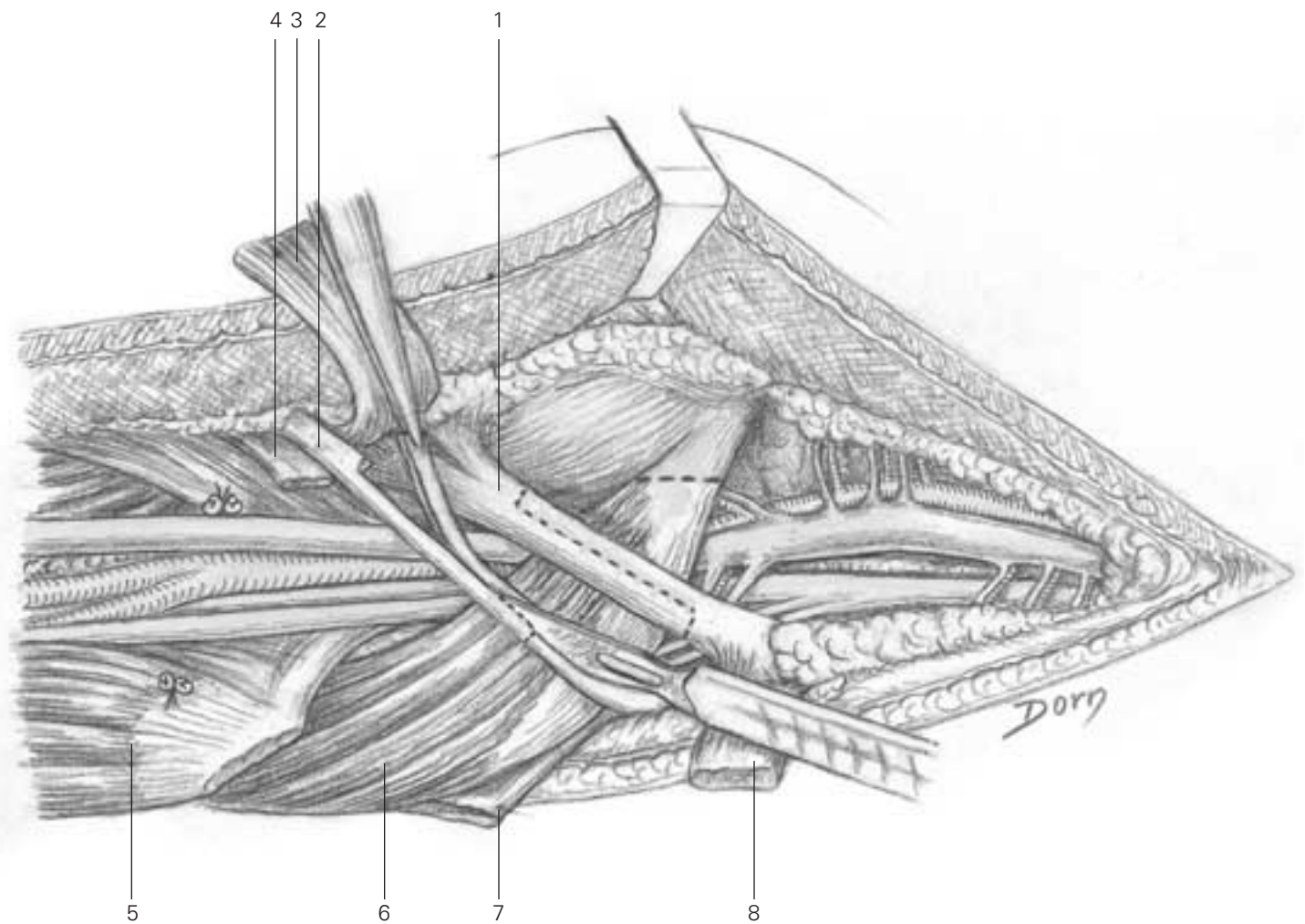
E Exposure of the femoral shaft.



- E**
- 1 short head of biceps
- 2 long head of biceps
- 3 fatty tissue containing sciatic nerve

Extended medial approach to the popliteal vessels

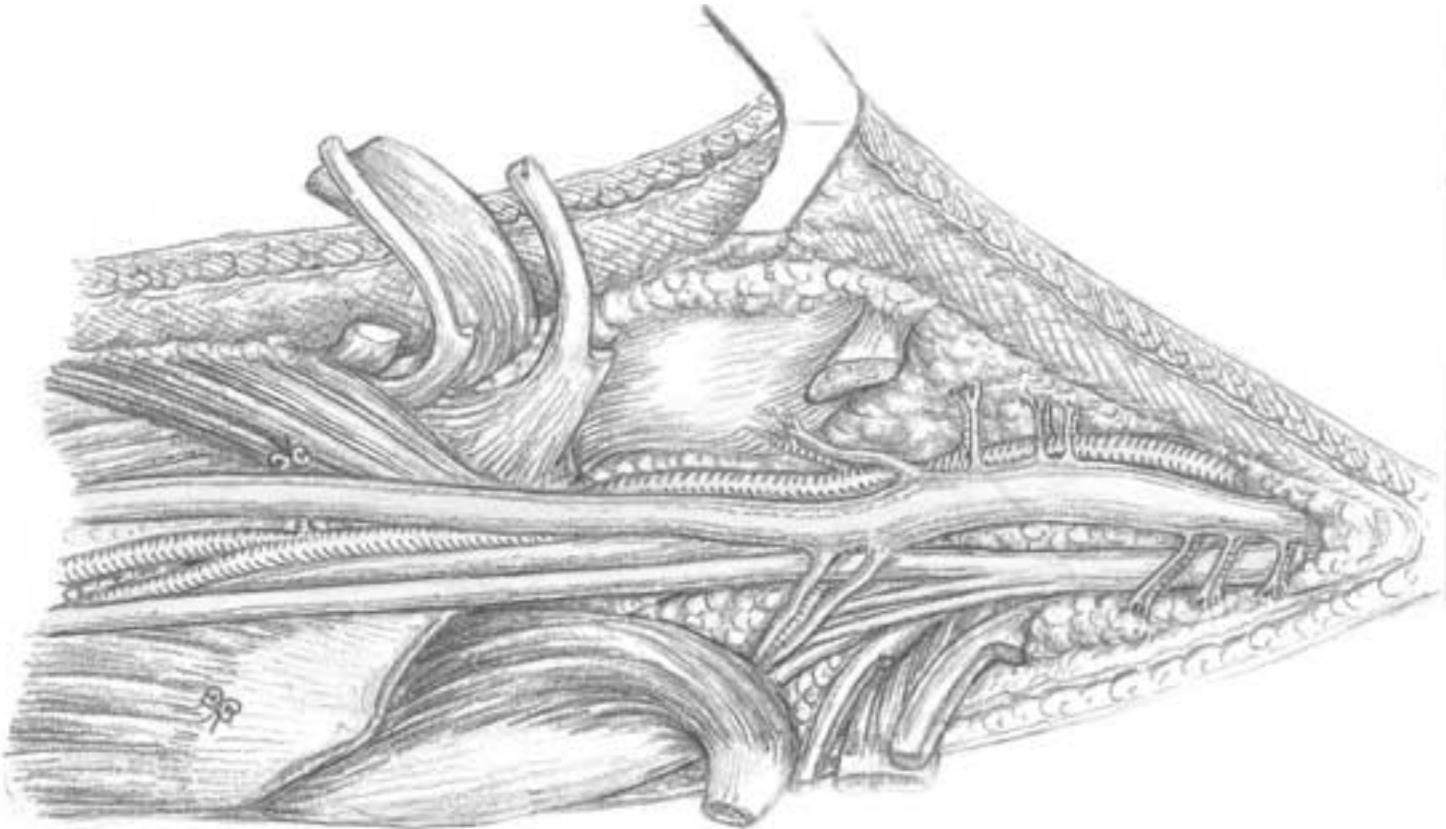
A The soleus has been released from the tibia. The insertion of pes anserinus, semimembranosus and medial head of gastrocnemius are divided.



- A**
- 1 semimembranosus
 - 2 gracilis
 - 3 sartorius
 - 4 semitendinosus
 - 5 soleus
 - 6 gastrocnemius
 - 7 semitendinosus
 - 8 sartorius

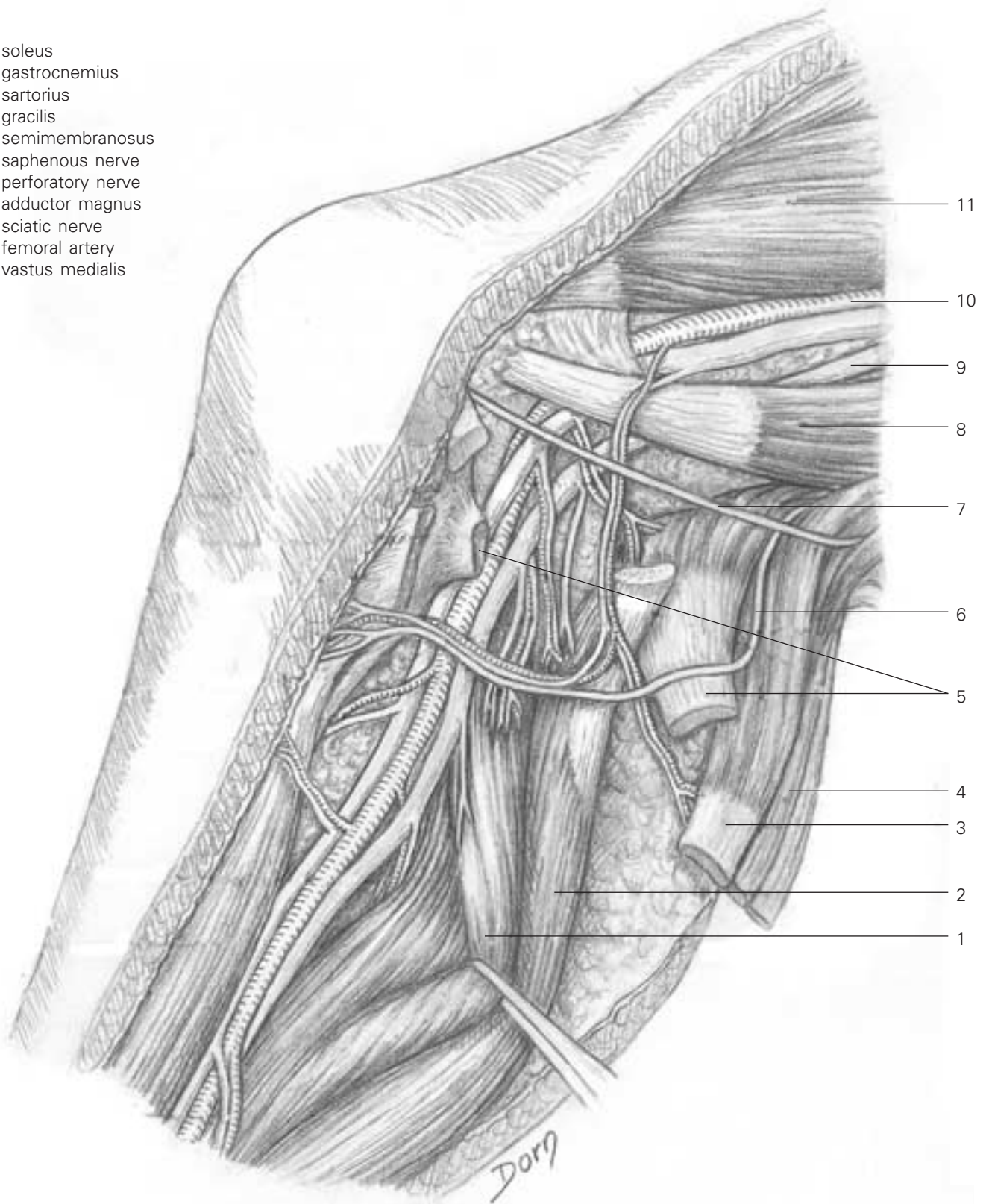
Lower limb surgery

B Medial aspect of the popliteal neurovascular bundle.



C Extended anatomical view of the medial aspect of the knee with the vascular and nerve supply. Only muscle insertions or tendons have been divided.

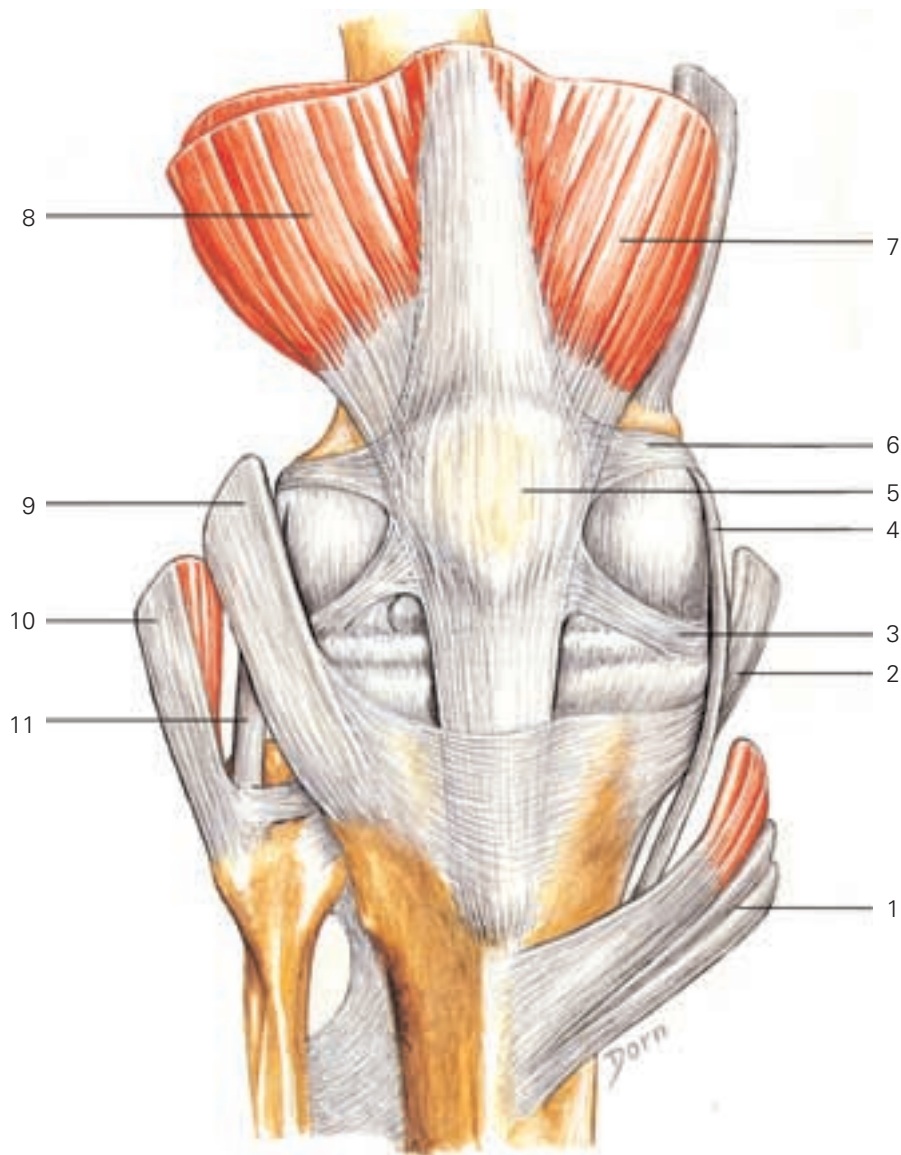
- C**
- 1 soleus
 - 2 gastrocnemius
 - 3 sartorius
 - 4 gracilis
 - 5 semimembranosus
 - 6 saphenous nerve
 - 7 perforatory nerve
 - 8 adductor magnus
 - 9 sciatic nerve
 - 10 femoral artery
 - 11 vastus medialis



Lower limb surgery

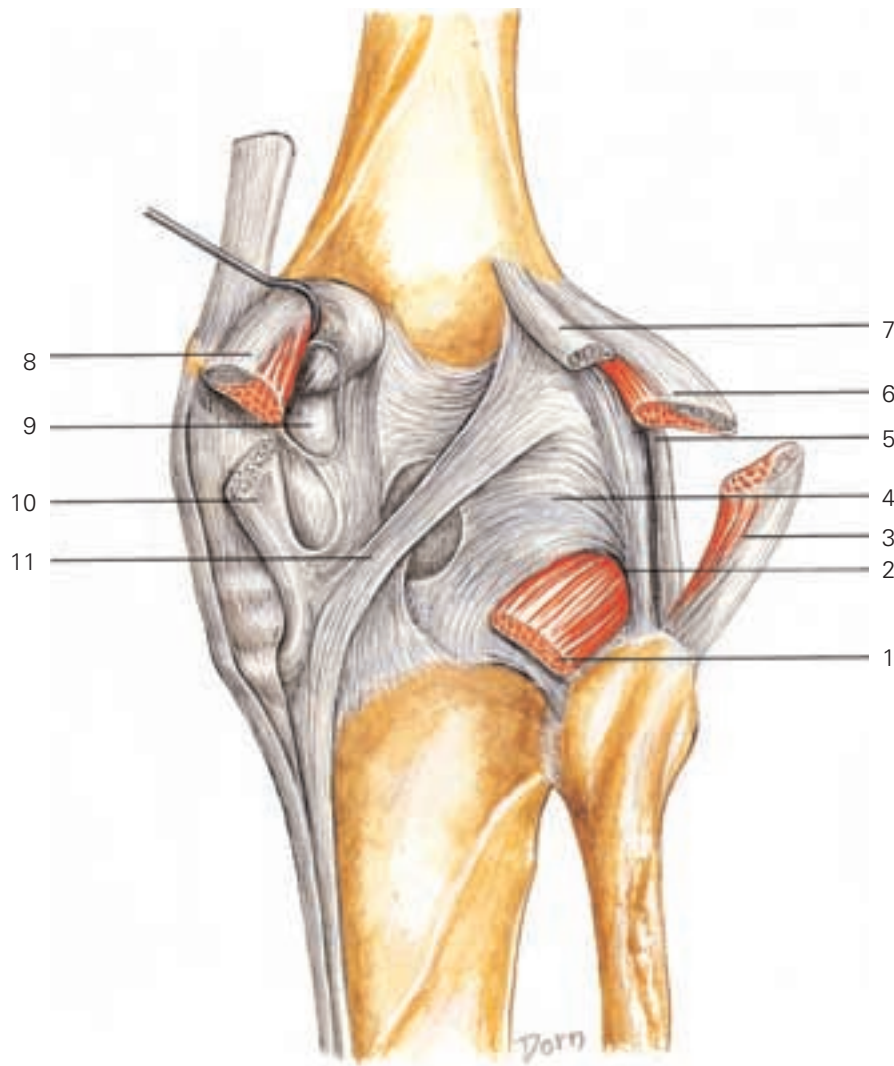
Anatomy of the knee

A Anterior view.



- 1 pes anserinus muscles
- 2 semimembranosus
- 3 patellomeniscal ligament
- 4 medial collateral ligament
- 5 patella
- 6 patellofemoral ligament
- 7 vastus medialis
- 8 vastus lateralis
- 9 iliotibial band
- 10 biceps femoris
- 11 lateral collateral ligament

B Posterior view.

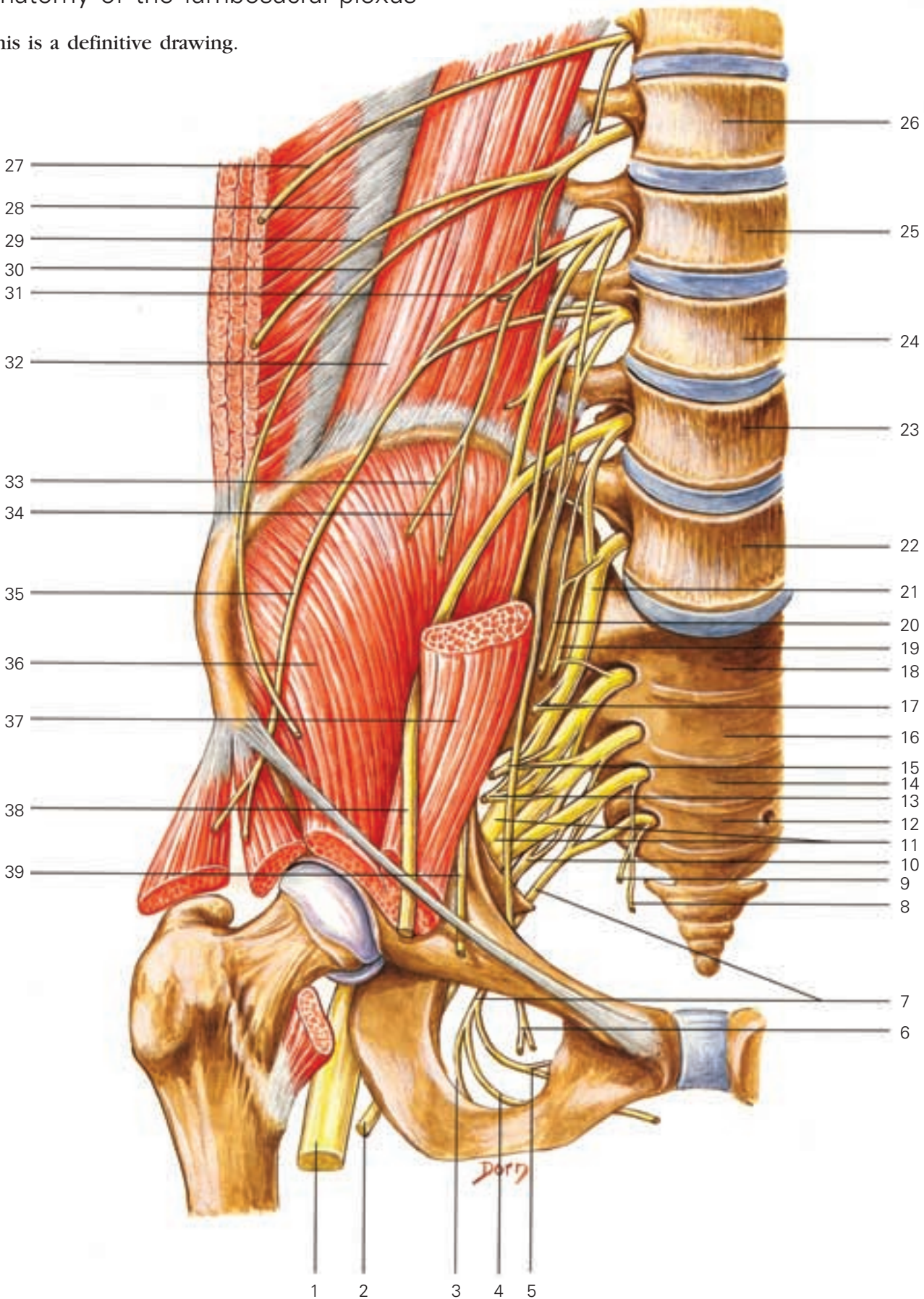


- 1 popliteus
- 2 popliteus hiatus
- 3 biceps femoris
- 4 arcuate ligament
- 5 lateral collateral ligament
- 6 lateral head of gastrocnemius
- 7 plantaris
- 8 medial head of gastrocnemius
- 9 bursa
- 10 semimembranosus
- 11 oblique ligament

Lower limb surgery

Anatomy of the lumbosacral plexus

This is a definitive drawing.

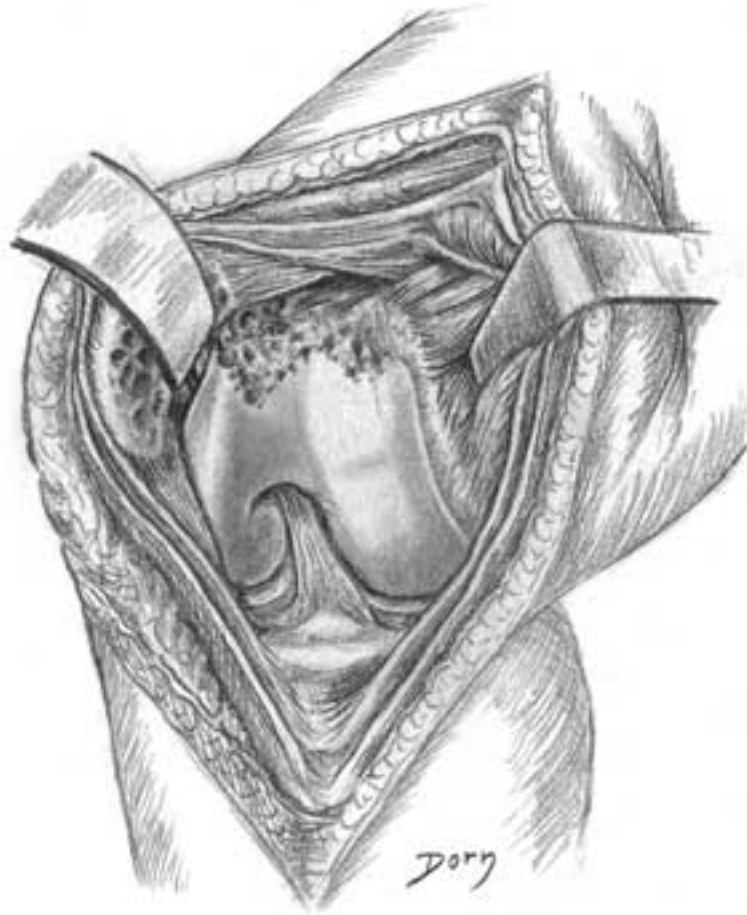


- 1 sciatic nerve
- 2 posterior cutaneous nerve of thigh
- 3 perineal nerve
- 4 dorsal nerve of penis/clitoris
- 5 inferior rectal nerve
- 6 obturator nerve
- 7 pudendal nerves (S2, 3, 4)
- 8 perineal branch of fourth sacral nerve
- 9 to levator ani and coccygeus (S3, 4)
- 10 posterior cutaneous nerve of thigh (S1, 2, 3)
- 11 sciatic nerve
- 12 S4
- 13 inferior gluteal nerve (L5, S1, 2)
- 14 S3
- 15 to piriformis (S1, 2)
- 16 S2
- 17 superior gluteal nerve (L4, 5, S1)
- 18 S1
- 19 to obturator internus and superior gemellus (L5, S1, 2)
- 20 to quadratus femoris and inferior gemellus (L5, S1, 2)
- 21 lumbosacral trunk
- 22 L5
- 23 L4
- 24 L3
- 25 L2
- 26 L1
- 27 subcostal nerve
- 28 transversus abdominis
- 29 iliohypogastric nerve (T12, L1)
- 30 ilioinguinal nerve (L1)
- 31 to psoas
- 32 quadratus lumborum
- 33 femoral branch of genitofemoral nerve
- 34 genital branch of genitofemoral nerve
- 35 lateral cutaneous nerve of thigh
- 36 iliacus
- 37 psoas
- 38 femoral nerve (L2, 3, 4)
- 39 accessory obturator nerve (L3, 4)

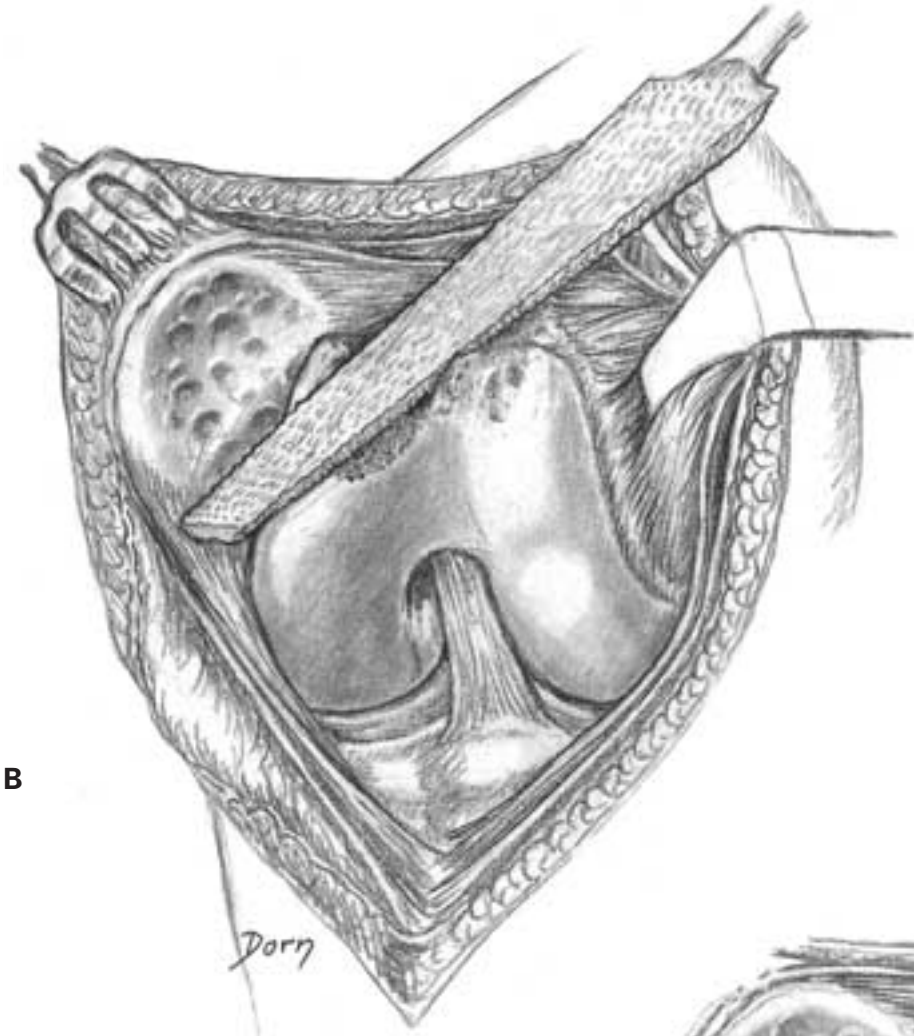
Surgery of the knee

Prosthesis of the patella

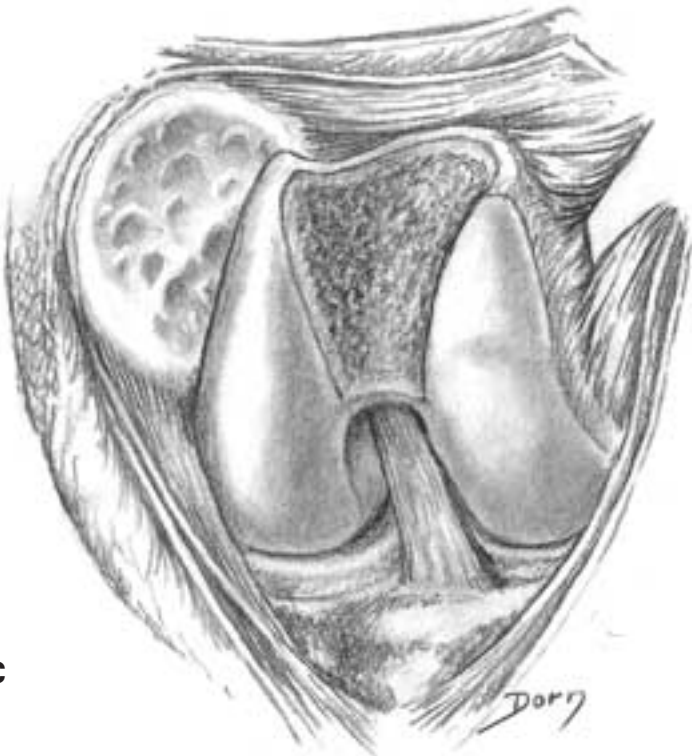
A Medial approach to the femoropatellar joint.



B-D Preparation of the trochlear implant.

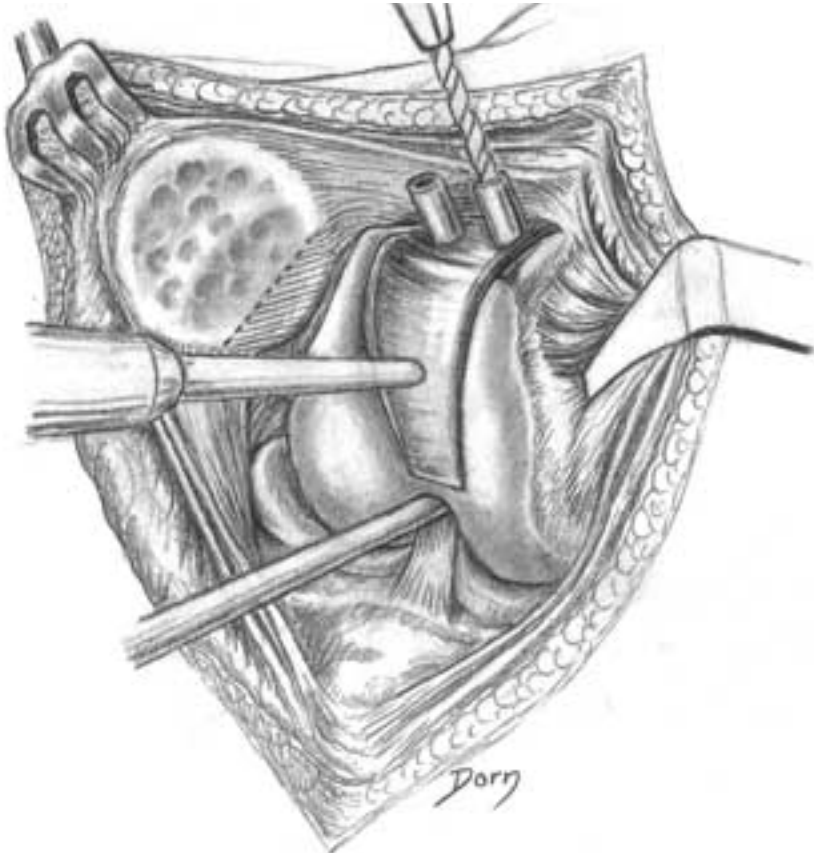


B



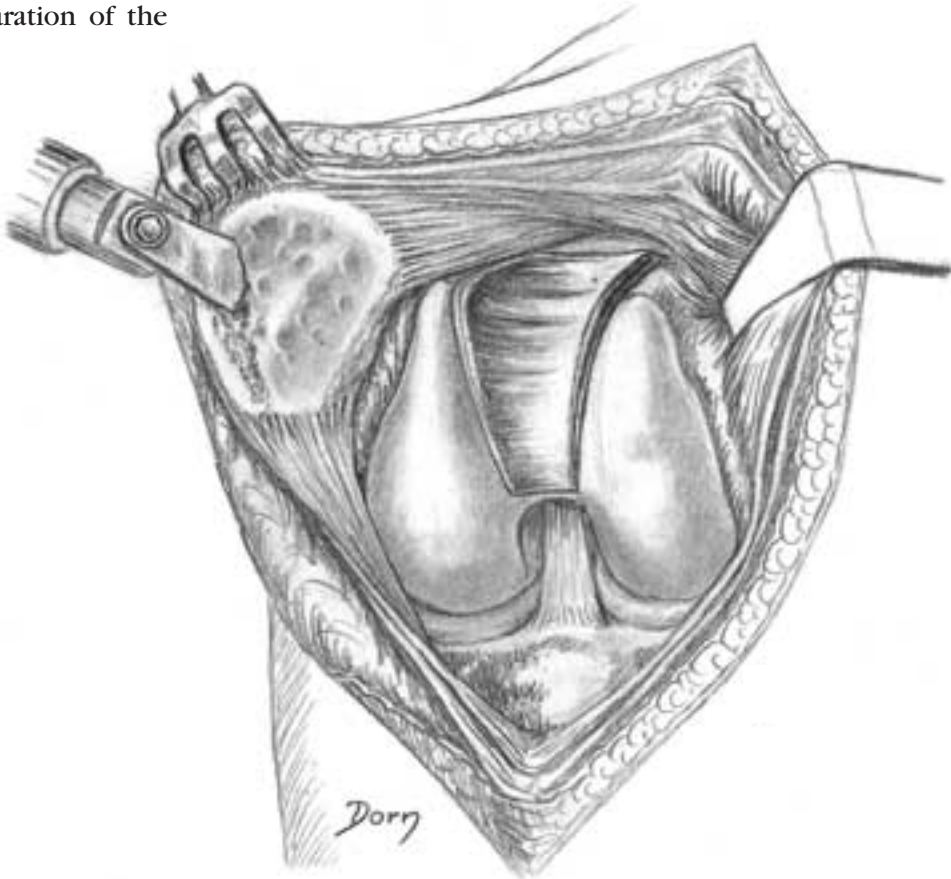
C

D

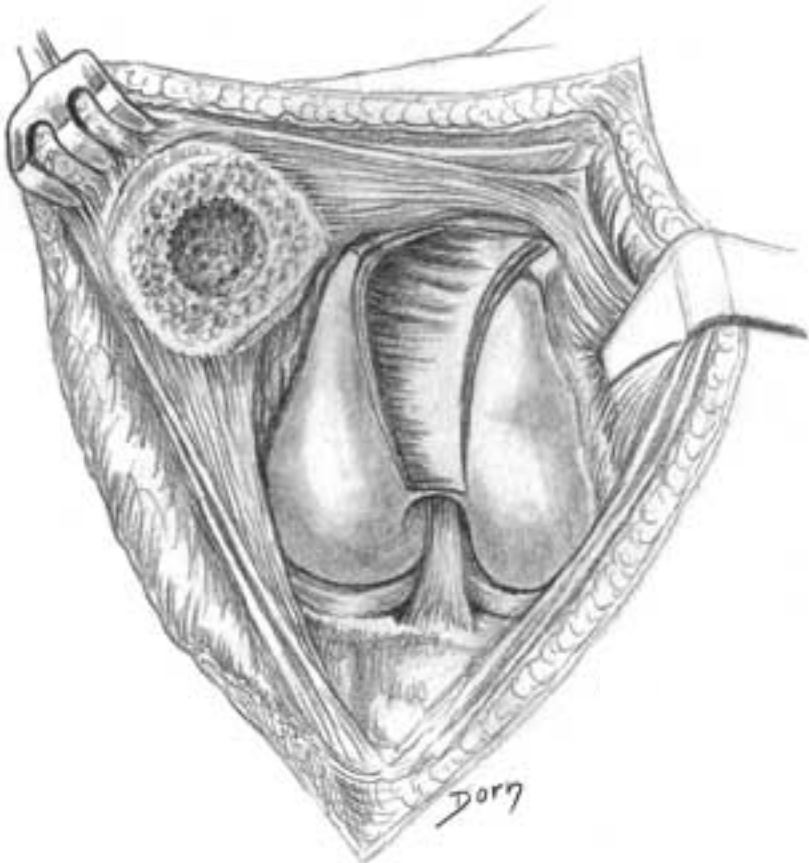


E, F Preparation of the patella.

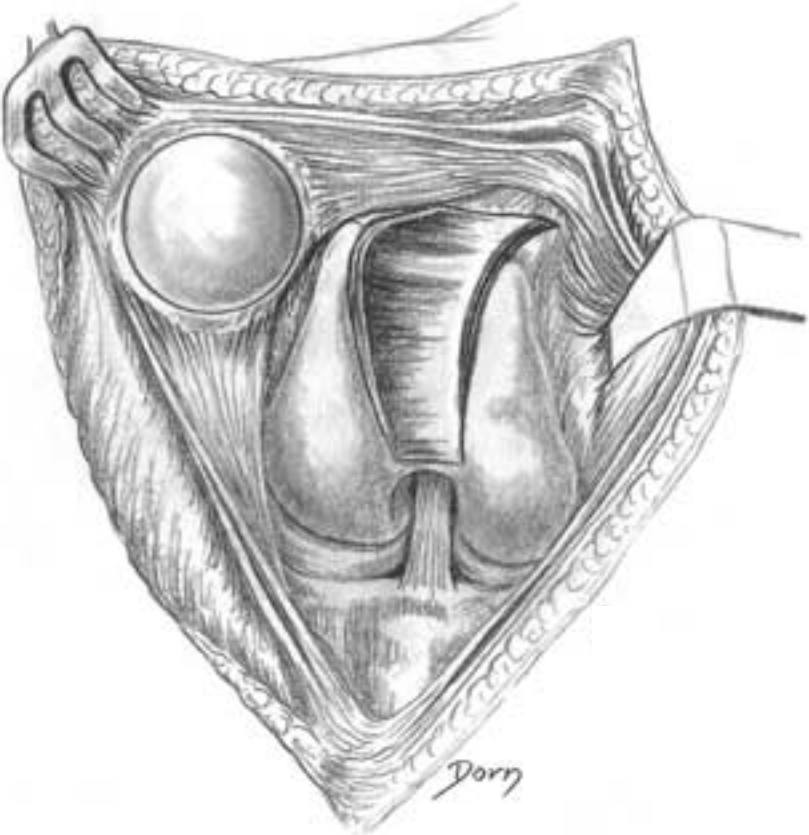
E



F



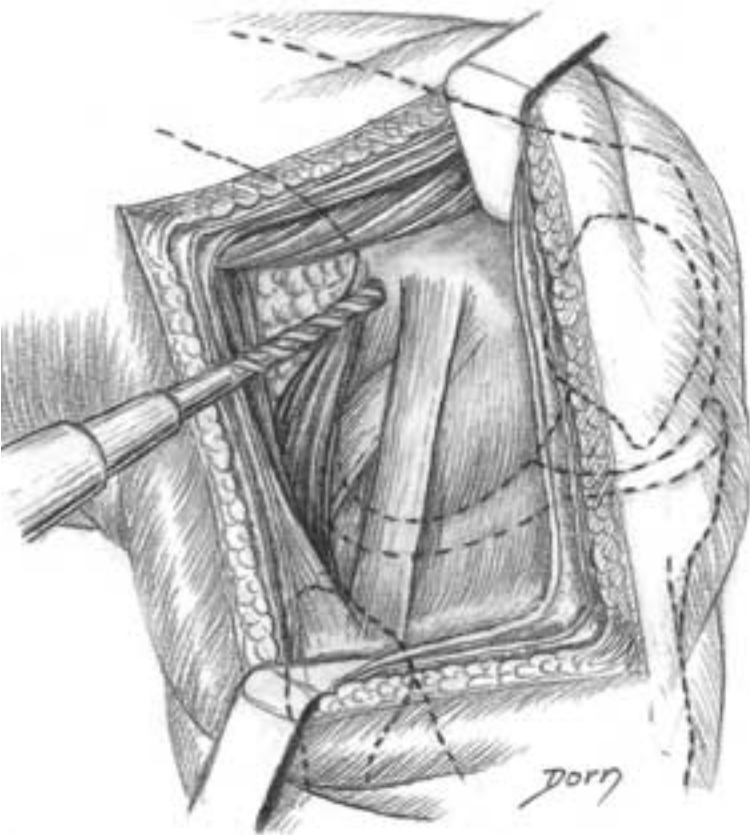
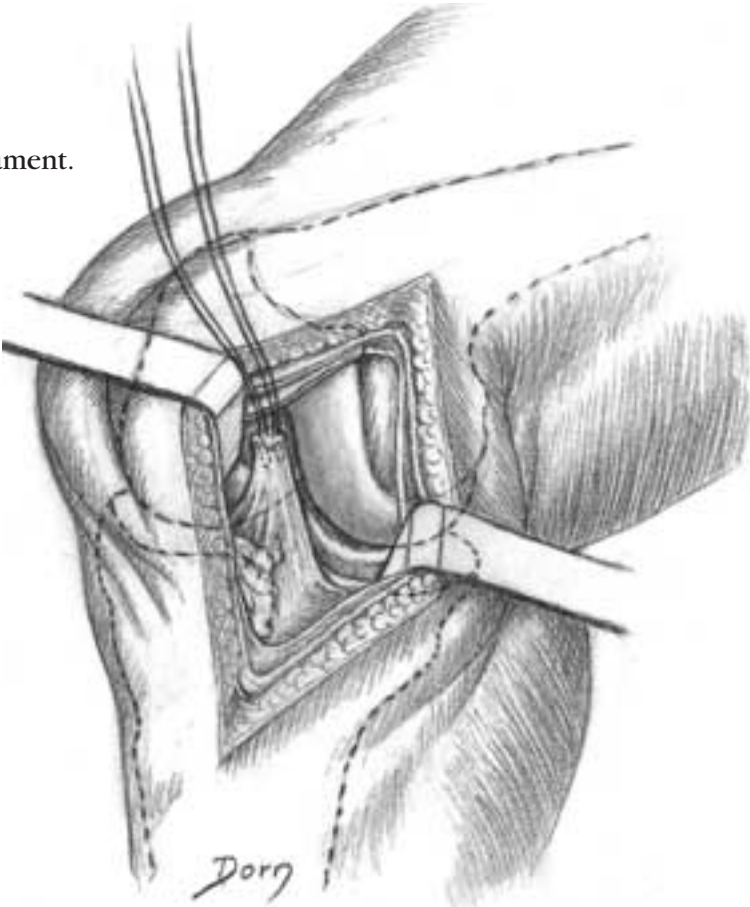
G The two components are in place.



Lower limb surgery

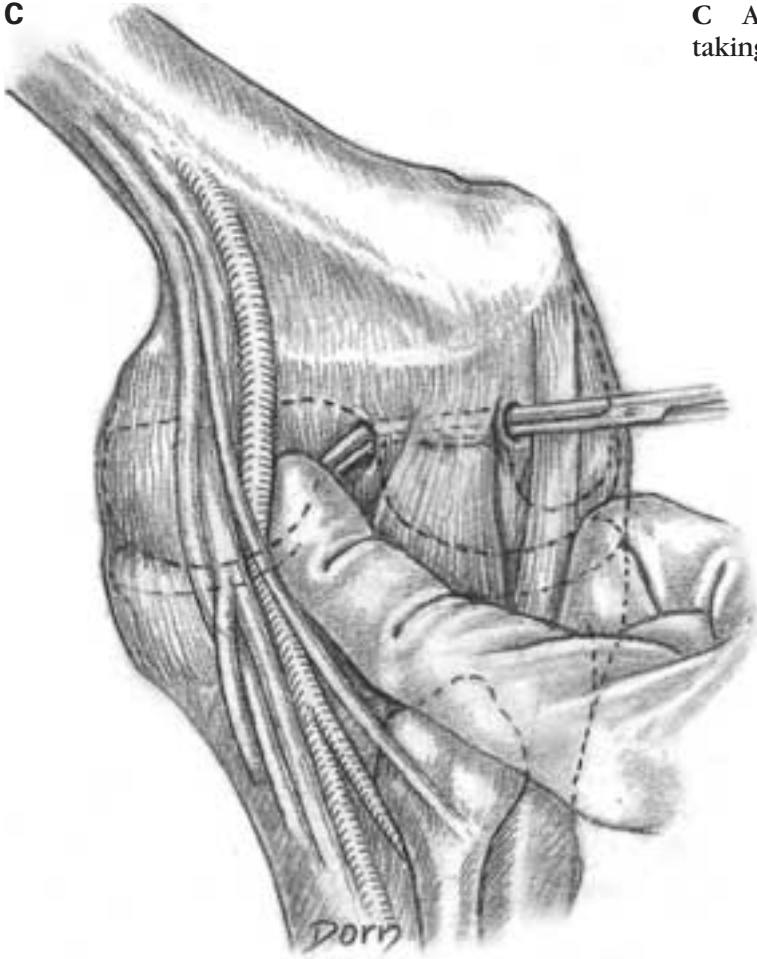
Repair of a rupture of the anterior cruciate ligament

A Anteromedial approach to retrieve the ligament.



B Posterolateral approach to perform a tunnel 'over the top' of the lateral condyle.

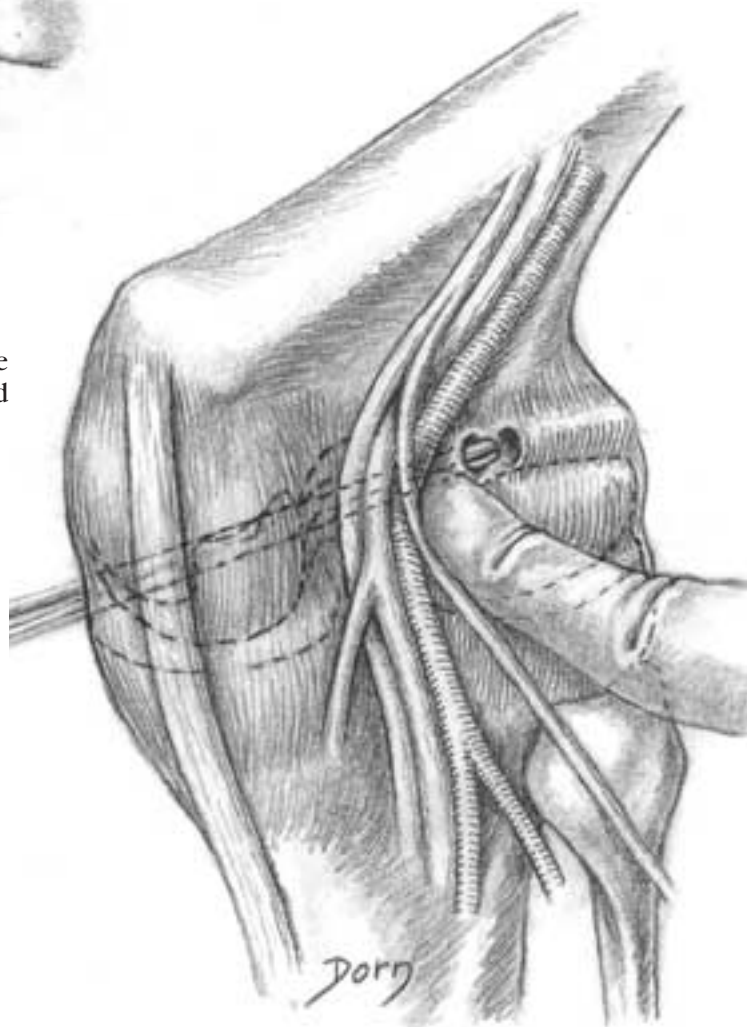
C



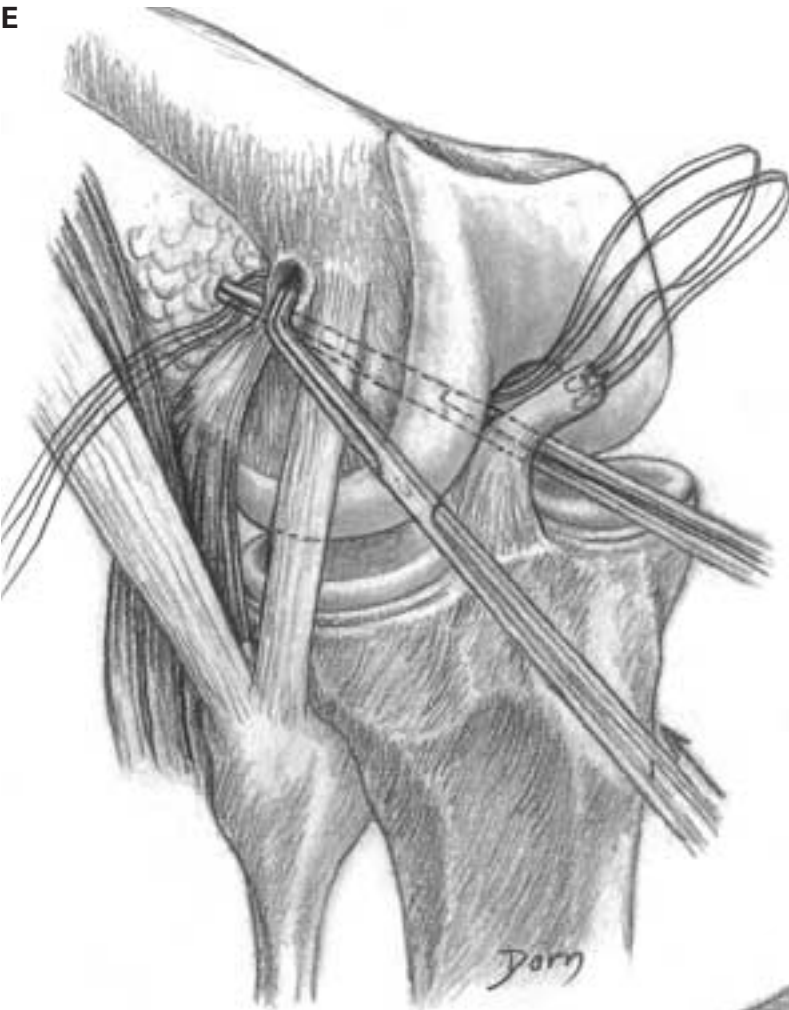
C A long forceps is passed through the tunnel, taking care of the vessels.

D-G The threads attached to the ligament are passed through posterior capsule and retrieved with the other forceps.

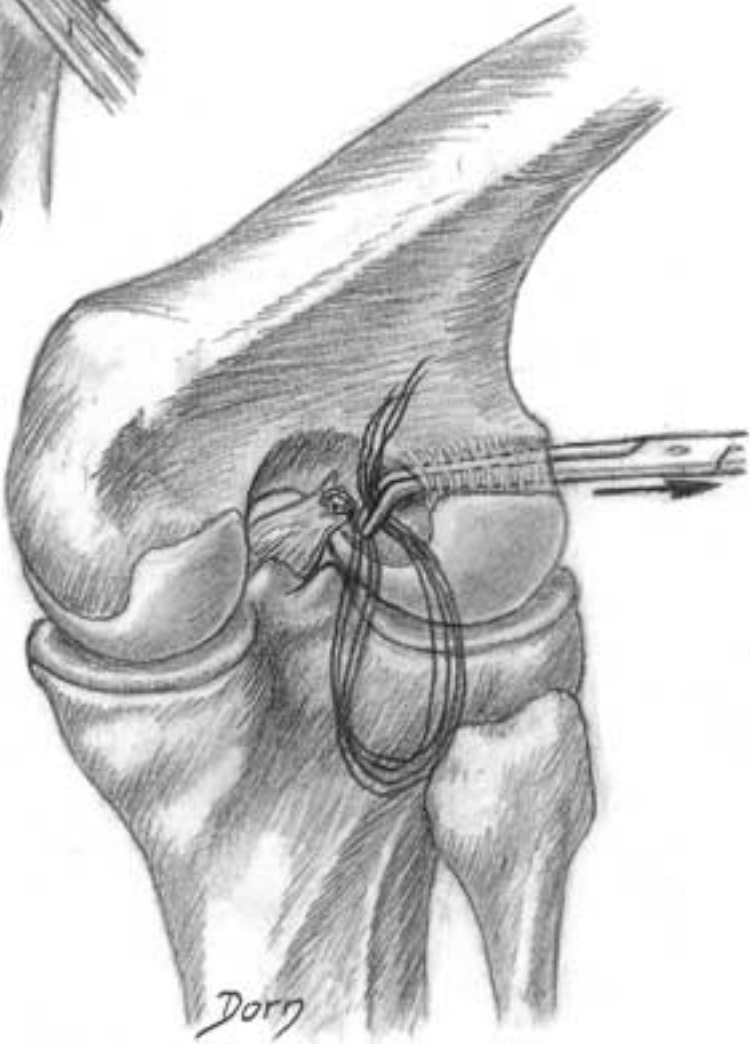
D



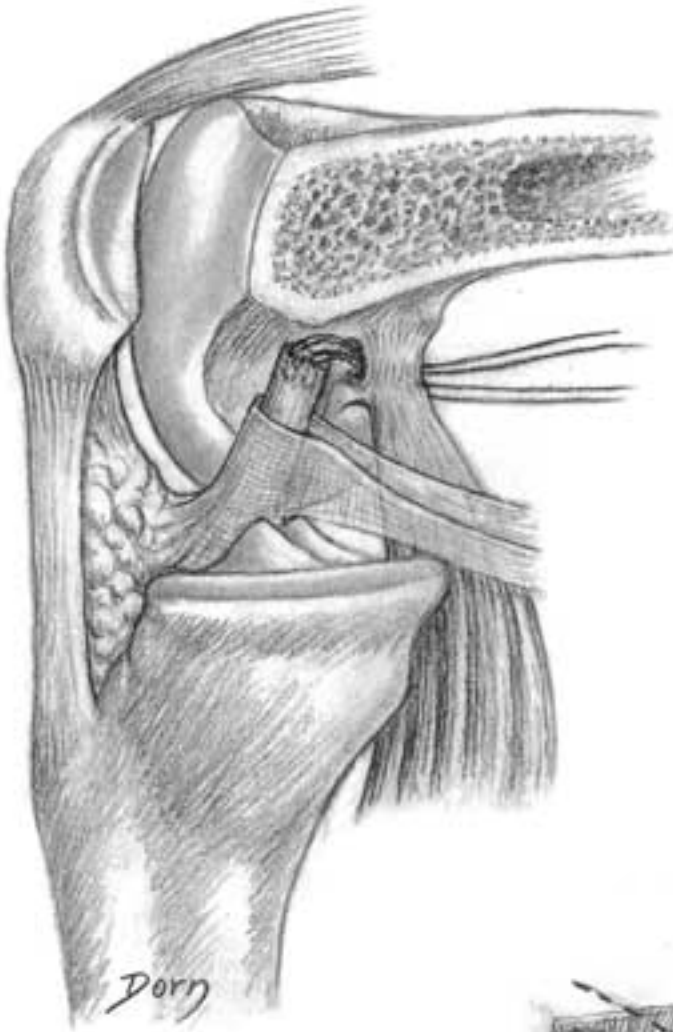E



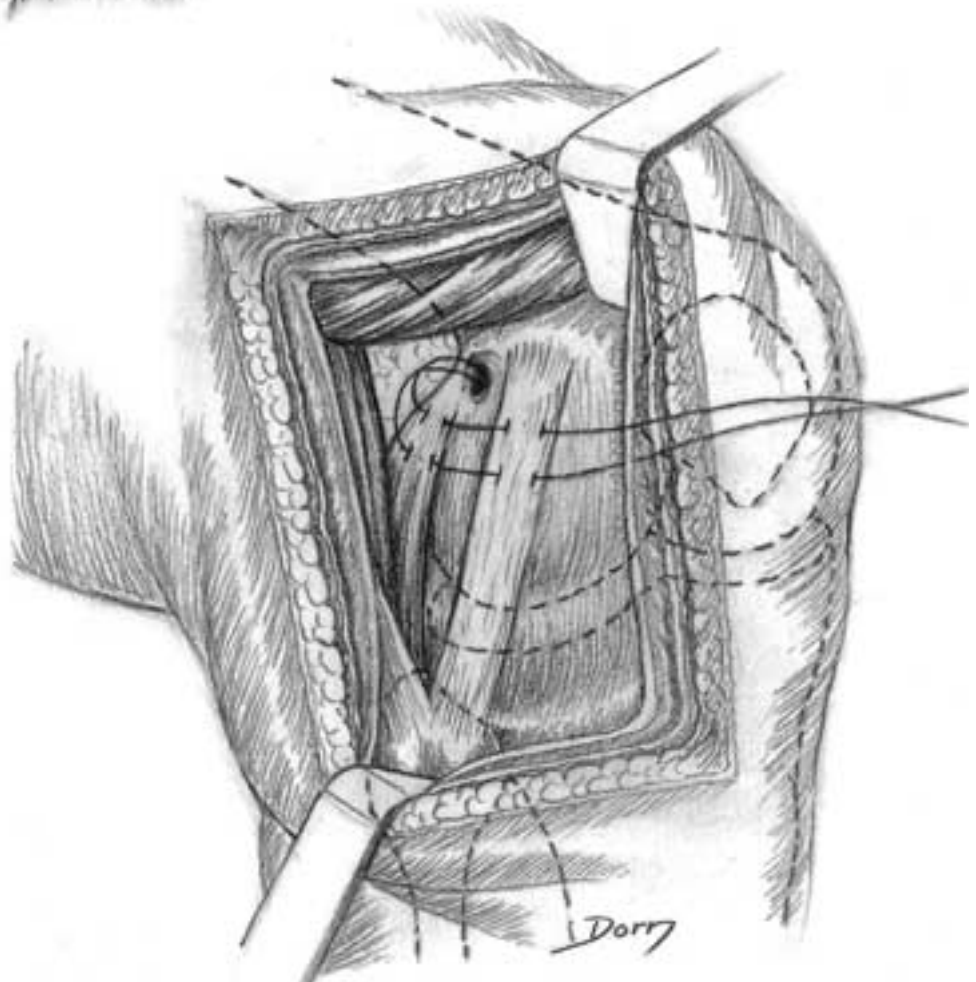
F



G



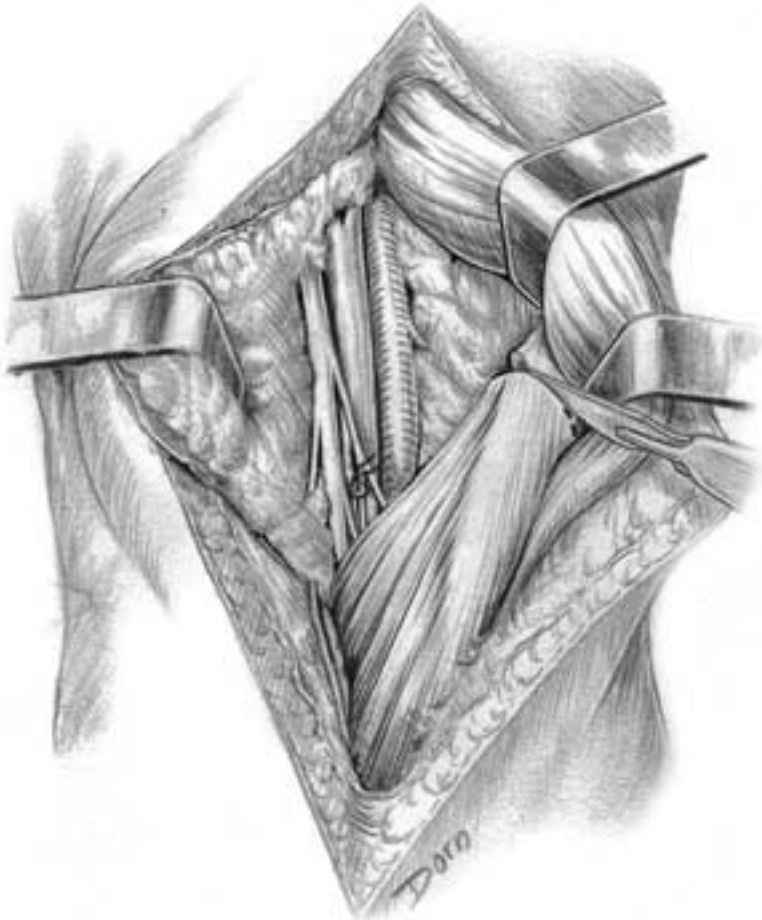
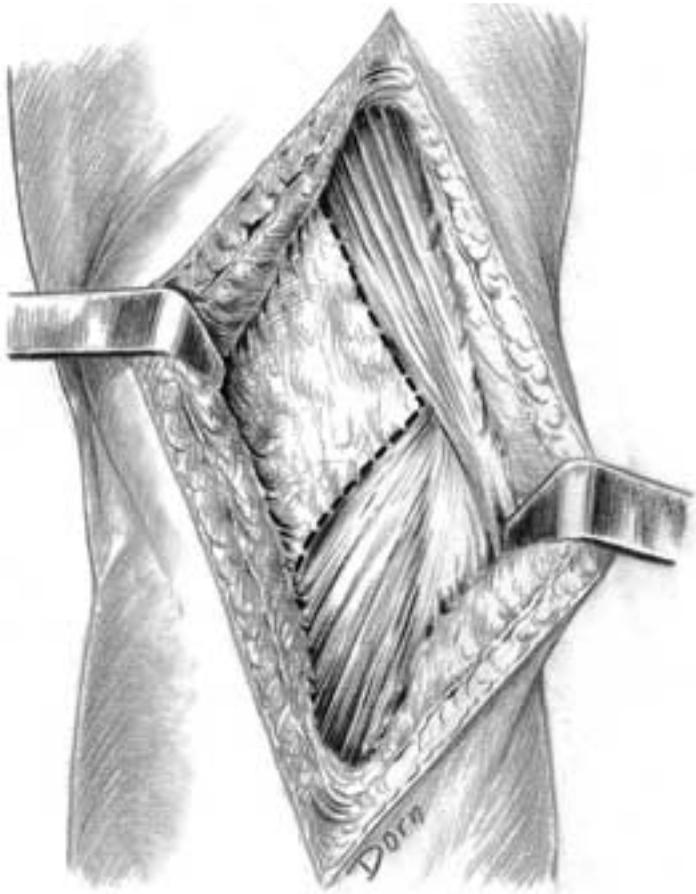
H The threads are passed through the tendon of the popliteal muscle and the lateral collateral ligament.



Lower limb surgery

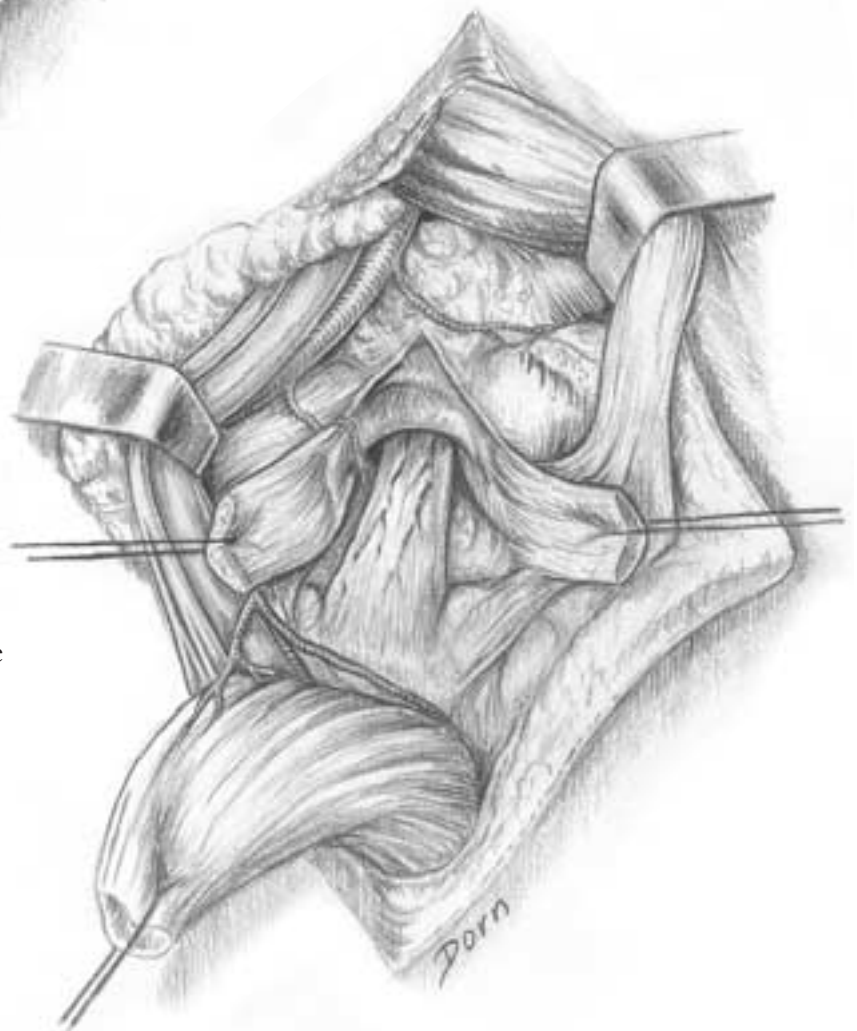
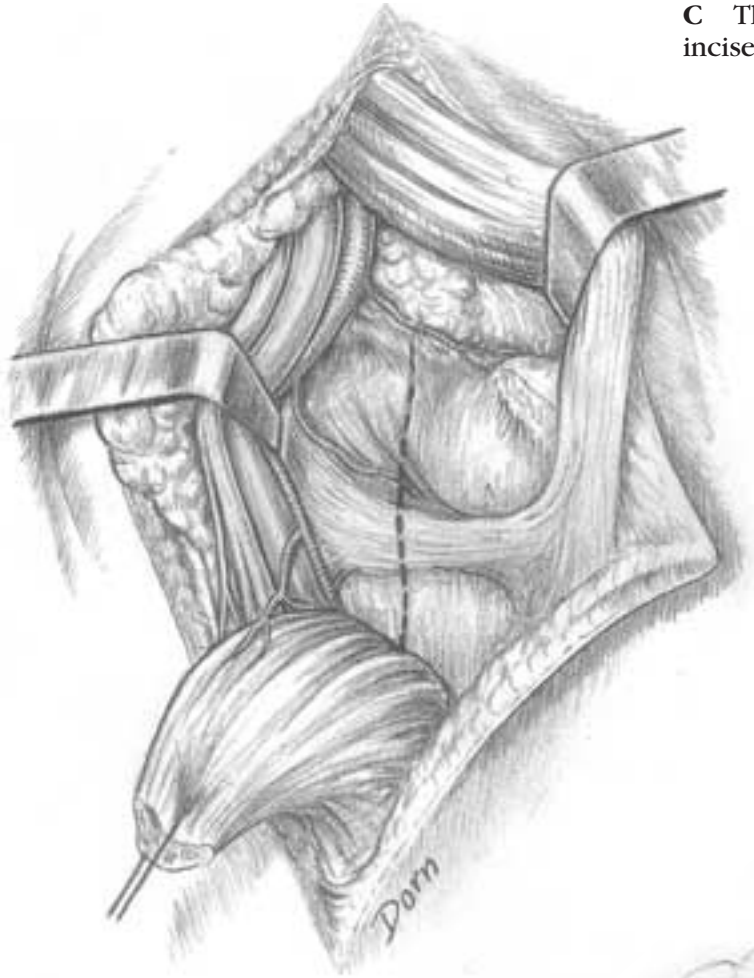Posterior approach to the posterior cruciate ligament (left limb)

A Popliteal fossa with the medial head of gastrocnemius.



B The tendon of the medial head is divided.

C The head is retracted laterally. The capsule is incised.

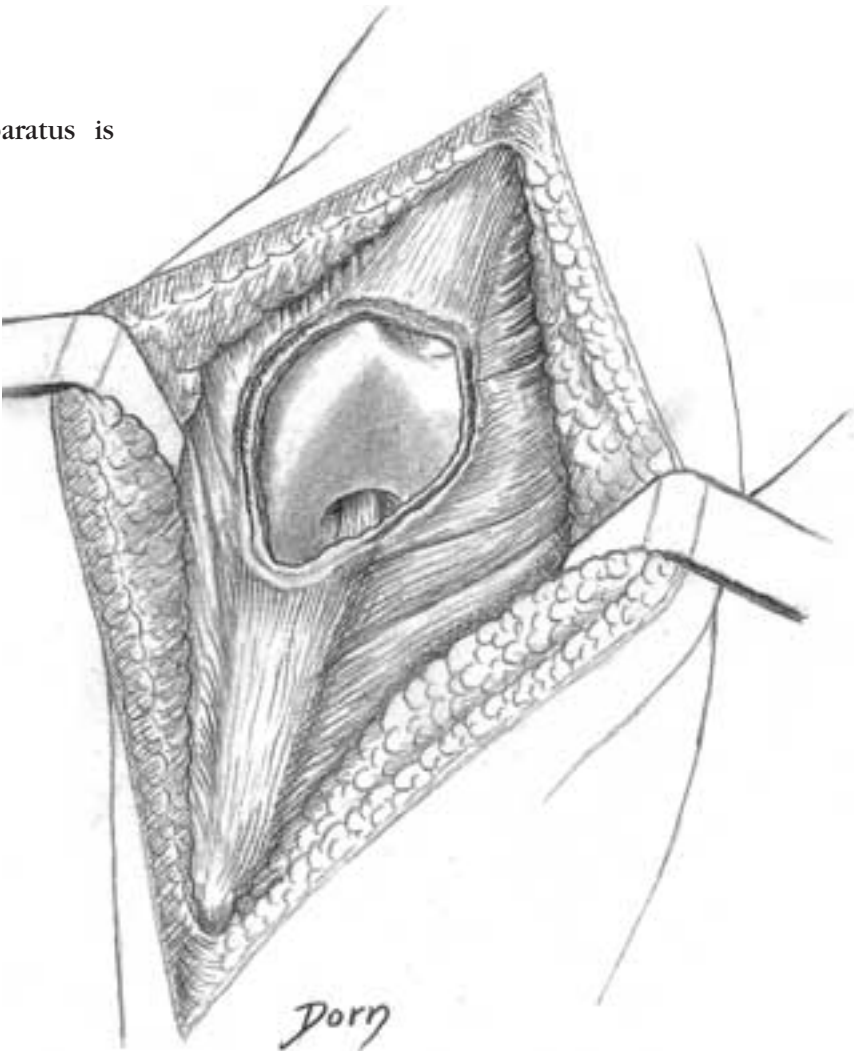
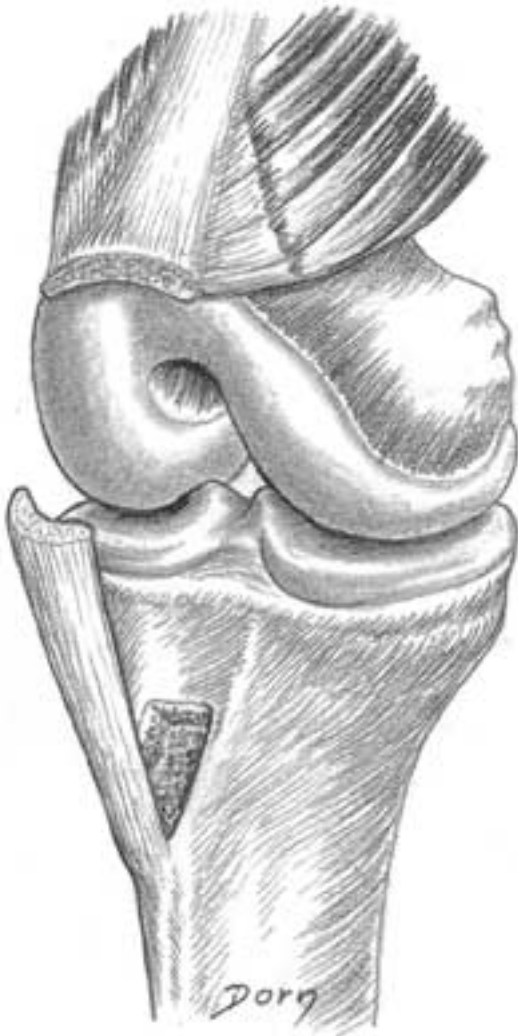

D Aspect of the posterior cruciate ligament.

Lower limb surgery

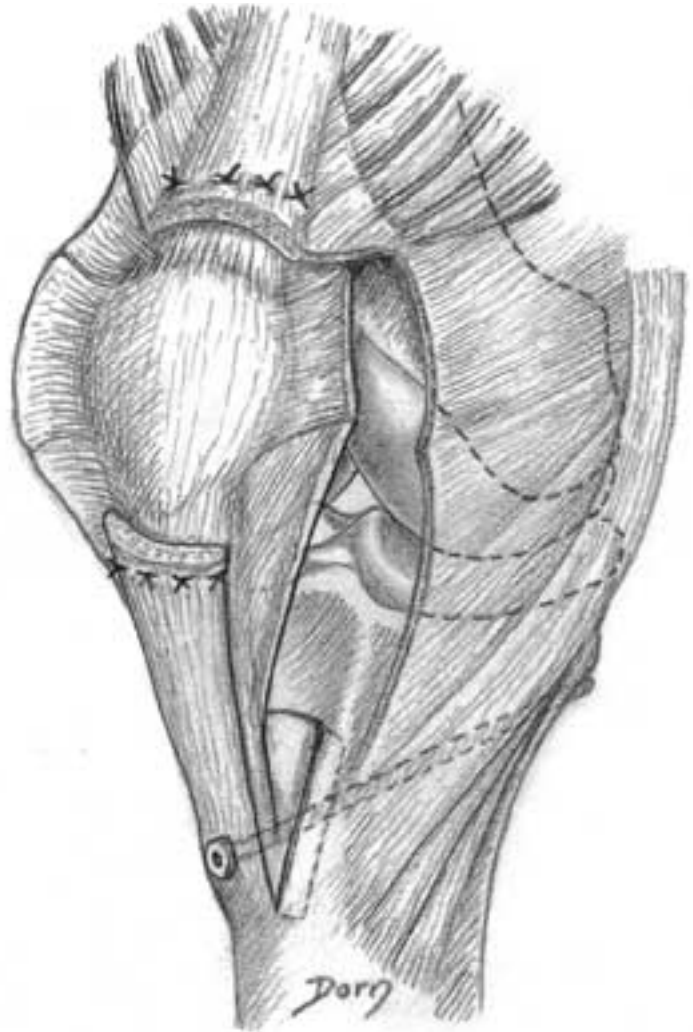
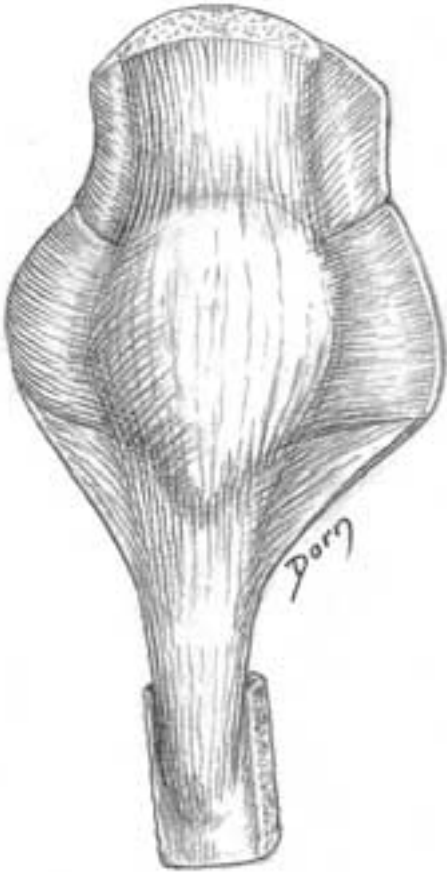
Allograft of patella and patellar ligament

A The continuity of the extensor apparatus is interrupted.



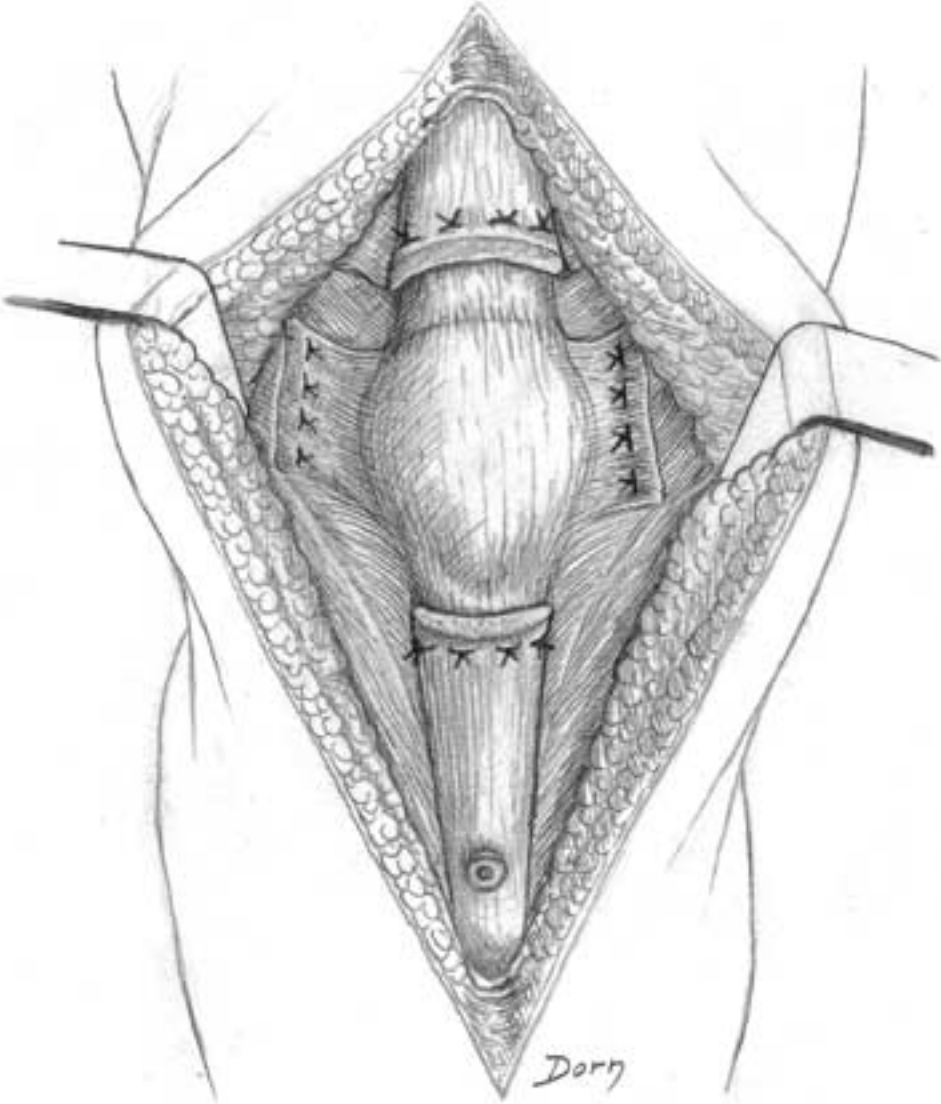
B Preparation of the recipient site.

C The allograft with a bone block and a short portion of rectus femoris tendon. **D** Fixation and suture of the allograft.



Lower limb surgery

E Final aspect with the sutures of the lateral patellar retinaculi.



Exposures of the acetabulum

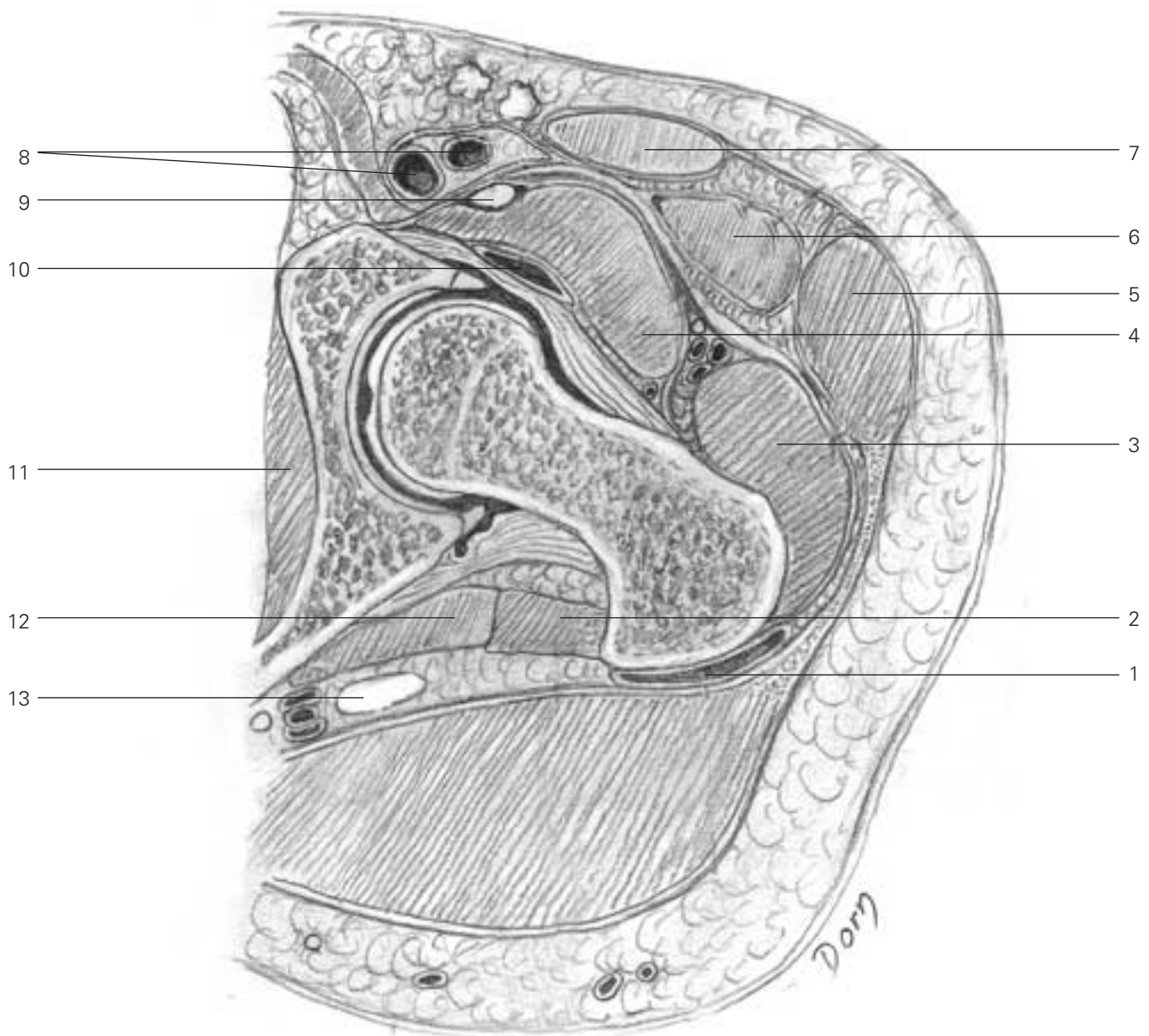
Surgery of the acetabulum is difficult given the depth of the joint and the extensive bone lesions.

Reconstructive surgery of the acetabulum was popularised by R. Judet and E. Letournel. The following series of drawings is among the most beautiful and precise artwork of Léon Dorn.

Cross-section through the hip joint

Note the thick (and unknown) fascia lying at the deep aspect of the rectus femoris.

- 1 trochanteric bursa
- 2 obturator extremis
- 3 gluteus medius
- 4 ileopsoas
- 5 tensor fasciae latae
- 6 rectus femoris
- 7 sartorius
- 8 femoral vessels
- 9 femoral nerve
- 10 ilio psoas bursa
- 11 obturator internus
- 12 gemellus inferior
- 13 sciatic nerve



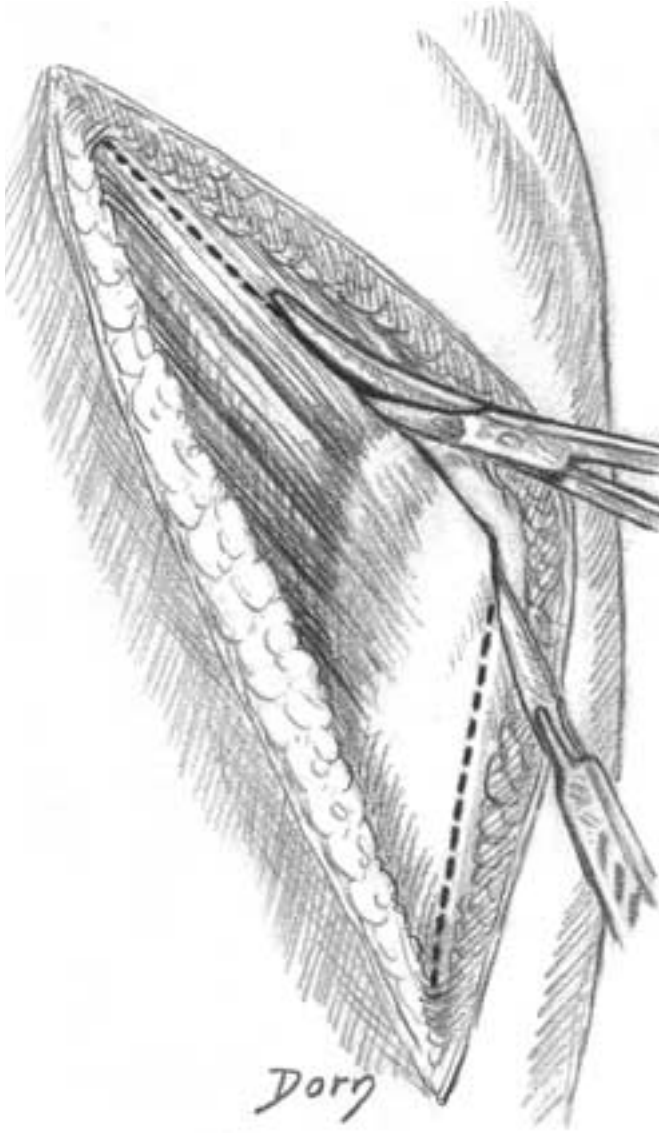
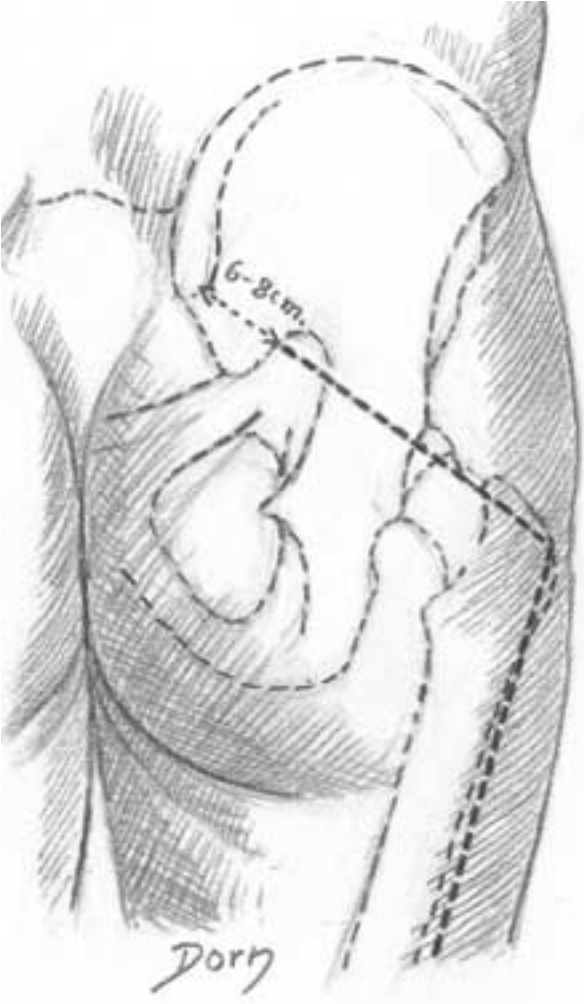
Lower limb surgery

Posterior approach to the acetabulum (Kocher–Langenbeck)

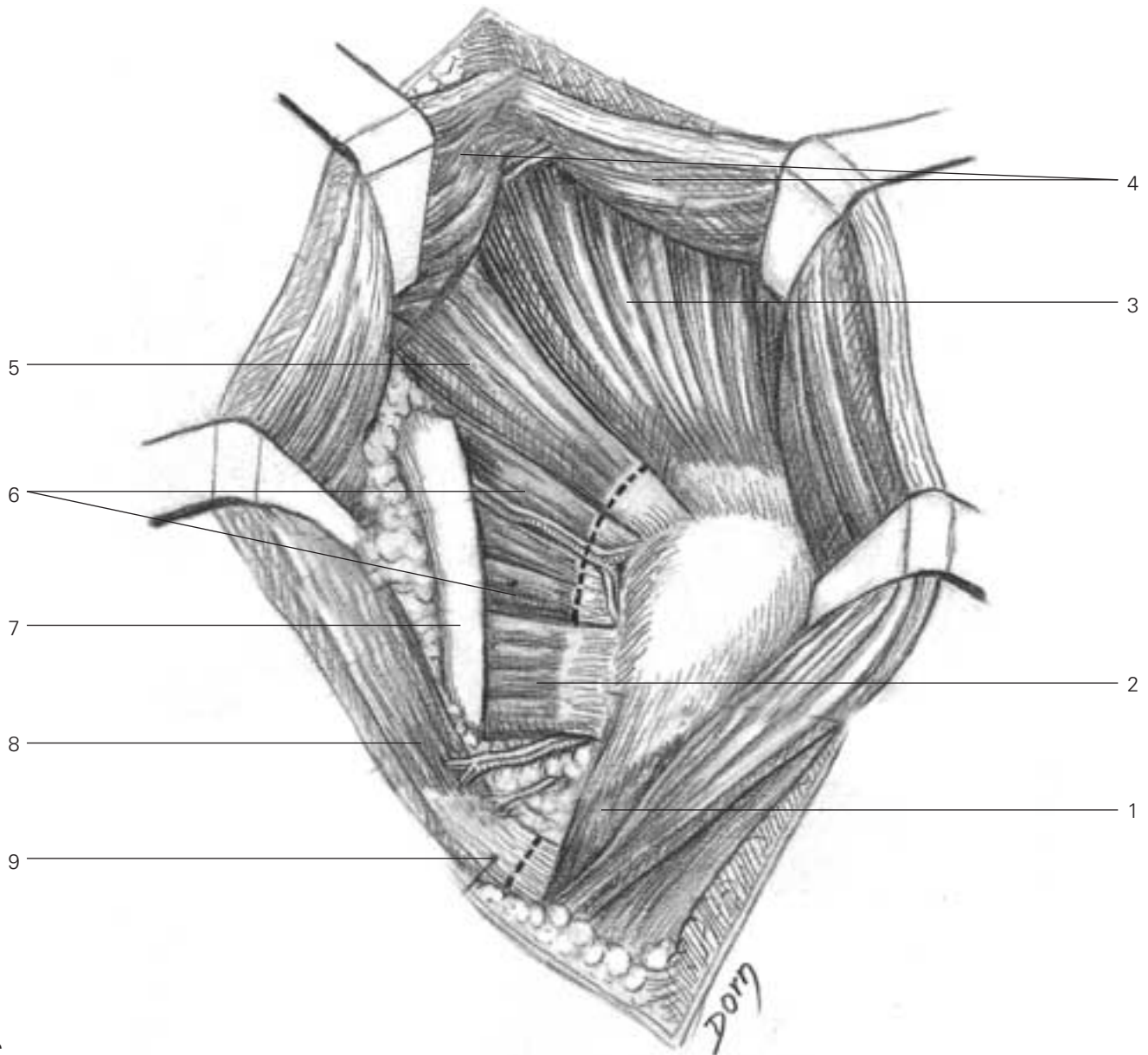
Its indication is the fracture of the posterior wall.

A Skin incision.

B Incision of the iliotibial tract and splitting of the fibres of the gluteus maximum muscle.



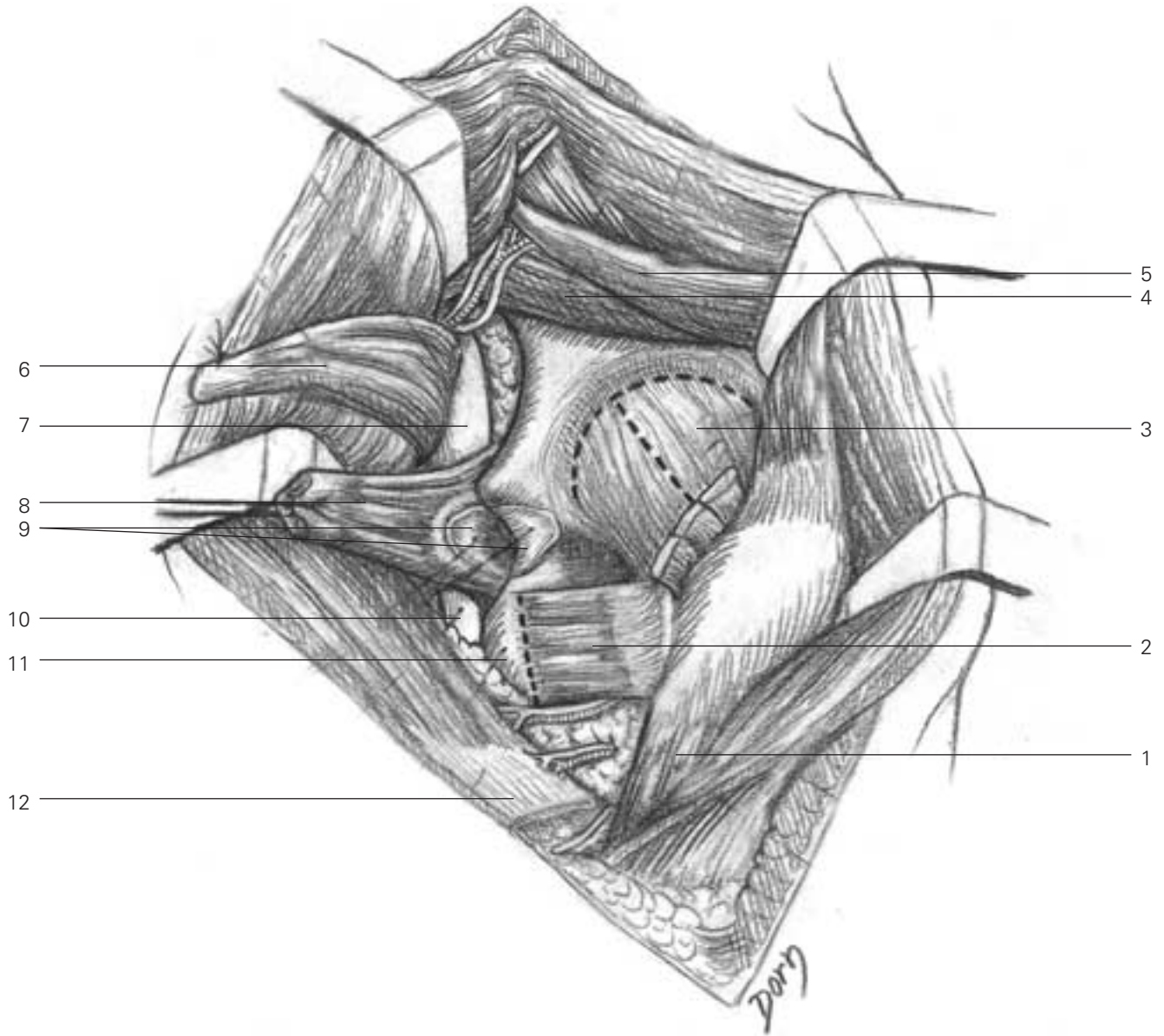
C Exposure of the sciatic nerve and the external rotators of the hip.



- C**
- 1 vastus lateralis
 - 2 quadratus femoris
 - 3 gluteus medius
 - 4 gluteus maximus, split
 - 5 piriformis
 - 6 obturator internus and gemelli
 - 7 sciatic nerve
 - 8 gluteus maximus
 - 9 distal tendon of gluteus maximus (to be cut)

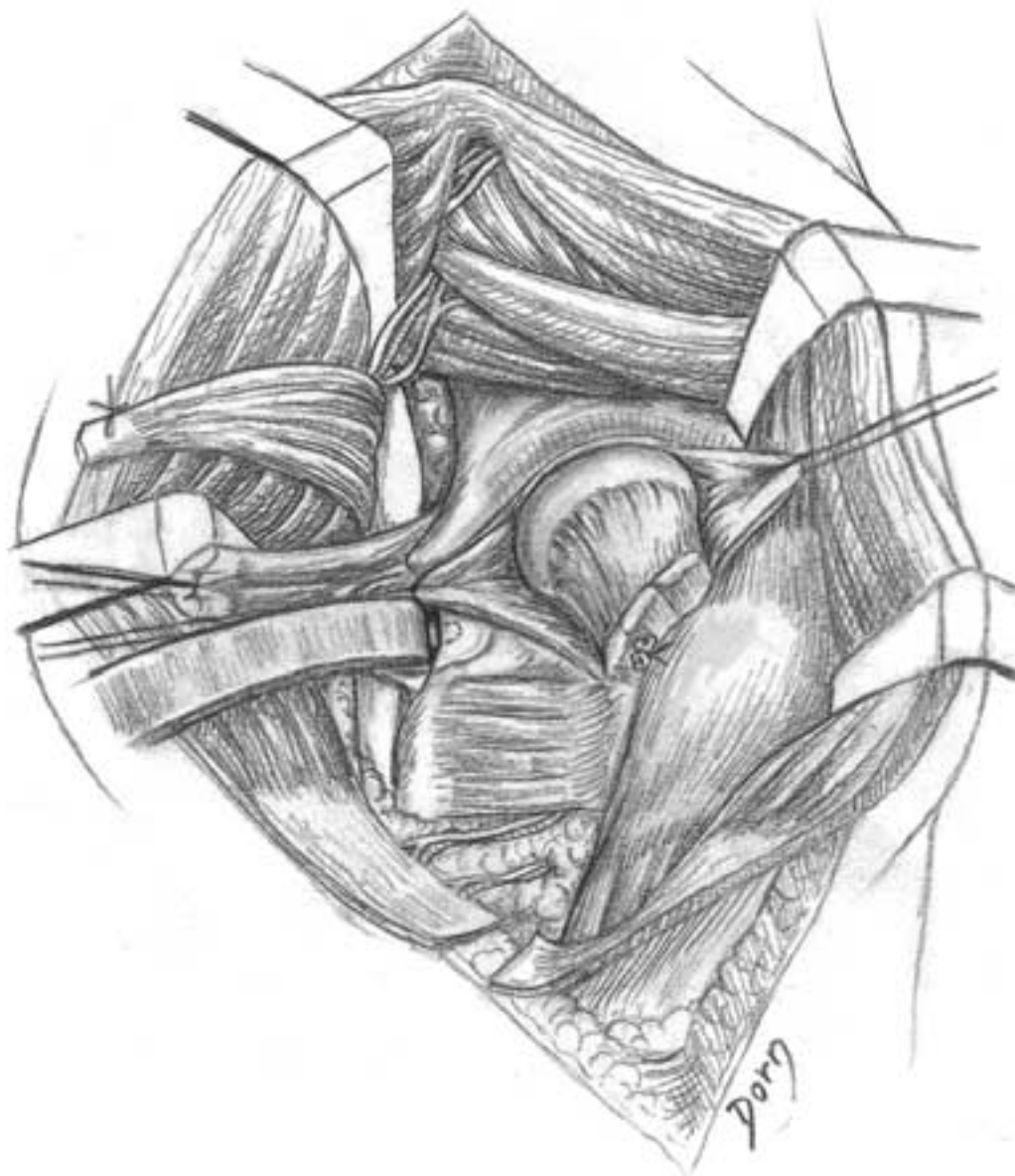
Lower limb surgery

D The rotators are retracted, exposing the capsule; one of the key steps is to find the bursa between the ischium and the obturator internis and the gemelli.



- D**
- 1 vastus lateralis
 - 2 quadratus femoris
 - 3 capsule
 - 4 gluteus minimus
 - 5 gluteus medius
 - 6 piriformis
 - 7 sciatic nerve
 - 8 obturator internus and gemelli
 - 9 lesser sciatic notch and bursa
 - 10 sciatic nerve
 - 11 ischion
 - 12 distal tendon of gluteus maximus

E The capsule is incised. Note the retractor which has been placed into the plane of the bursa.

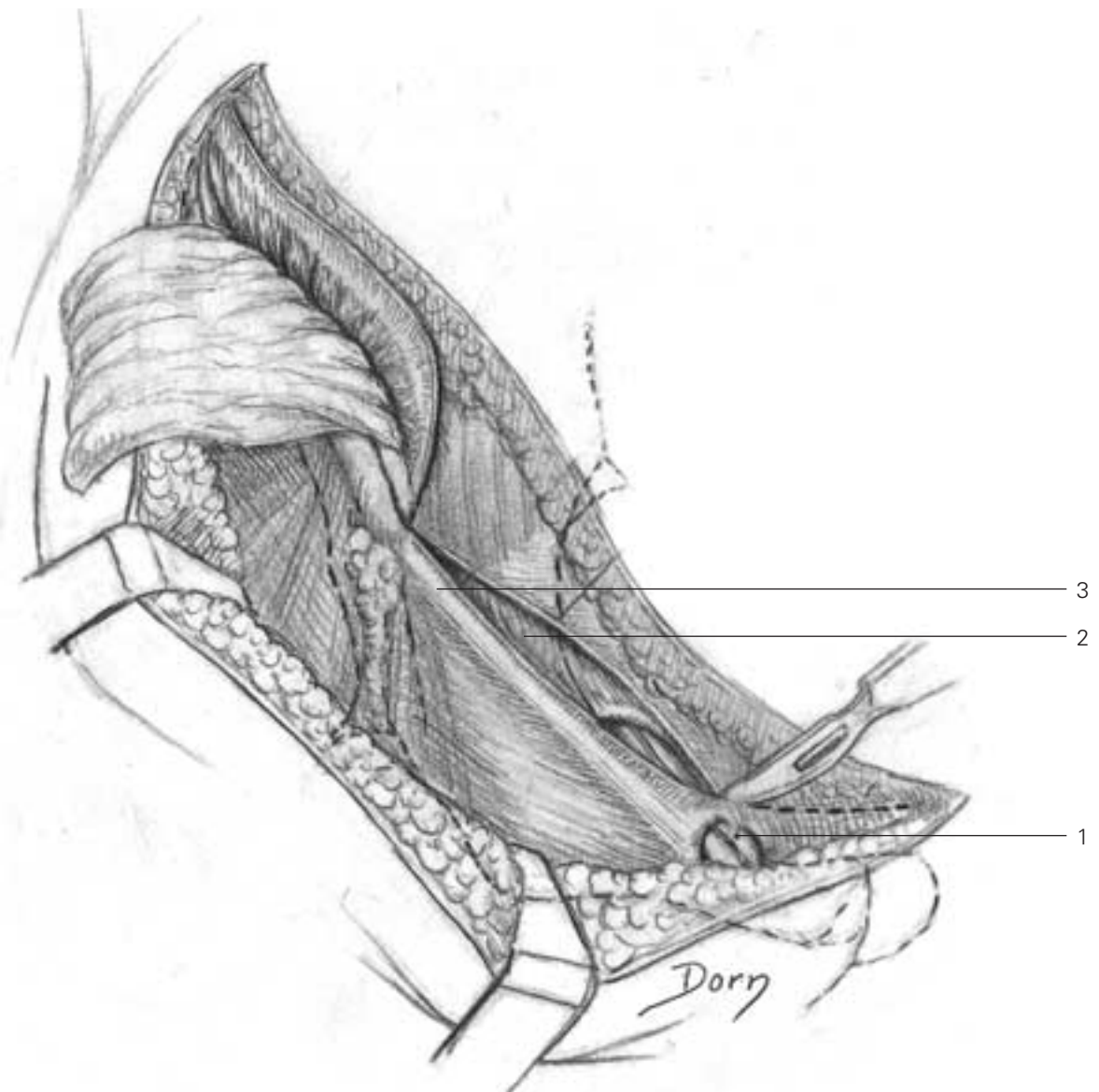


Lower limb surgery

Inguinal approach to the acetabulum

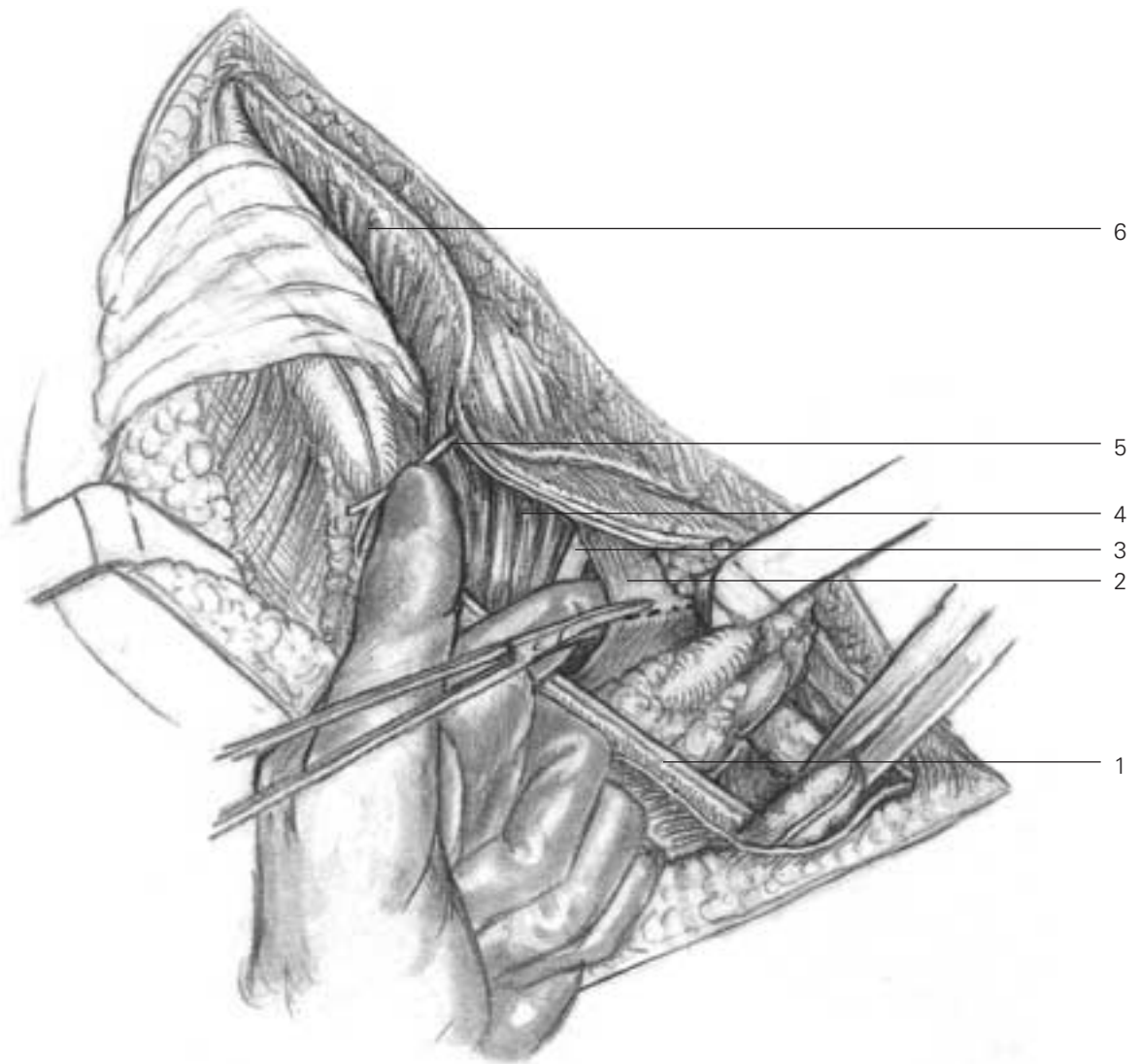
Its indications are the fracture of anterior wall or anterior column and some complex fractures involving both columns of the acetabulum.

A The fascia is incised in line with the skin incision.



- A**
- 1 spermatic cord
 - 2 internal oblique
 - 3 inguinal ligament

B The spermatic cord, the external iliac vessels, the femoral nerve, the psoas muscle and the lateral cutaneous nerve of the thigh have been isolated. The iliopsoas fascia is severed.

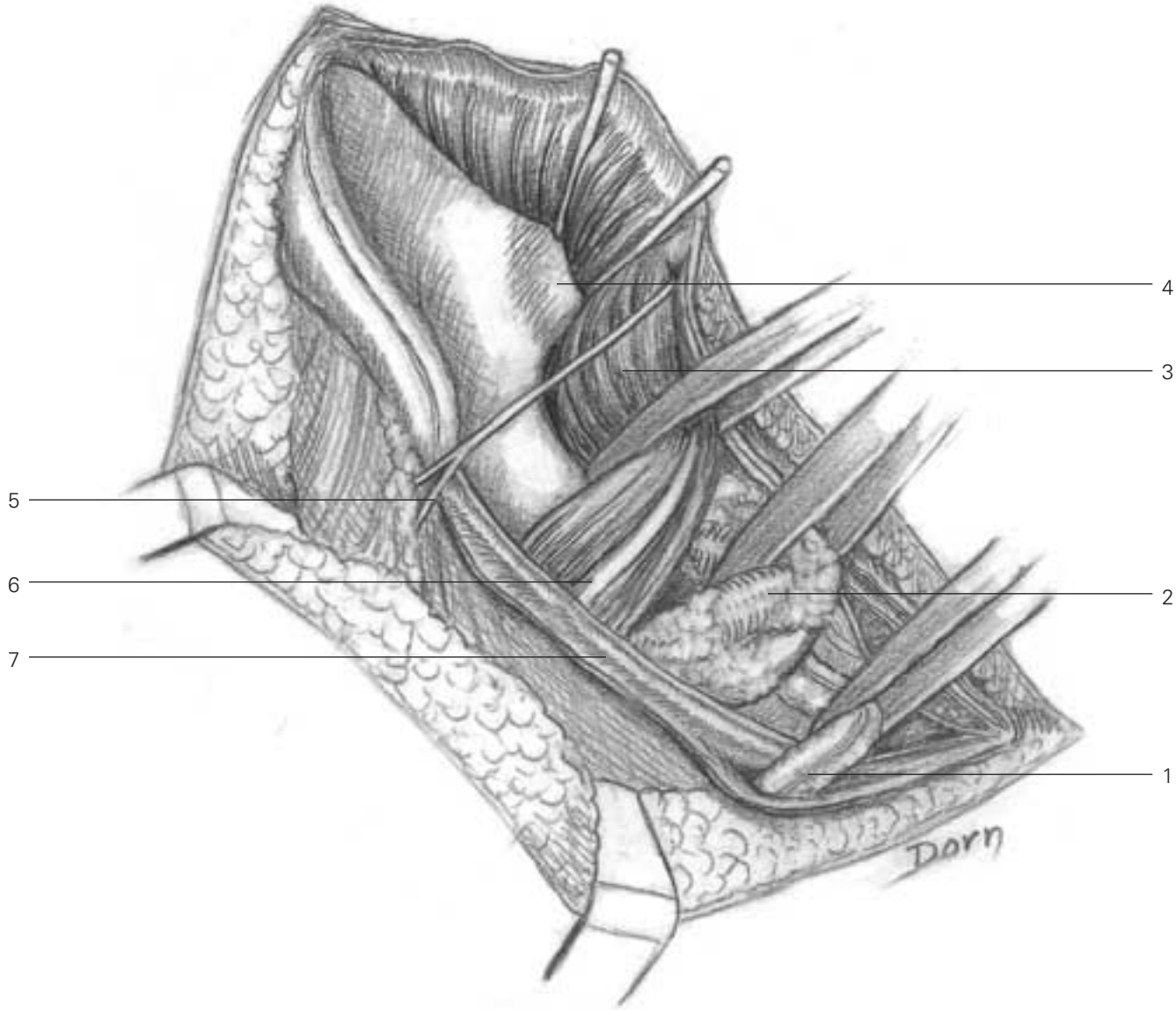


B

- 1 inguinal ligament
- 2 iliopsoas fascia
- 3 femoral nerve
- 4 iliopsoas
- 5 lateral cutaneous nerve of thigh
- 6 iliacus

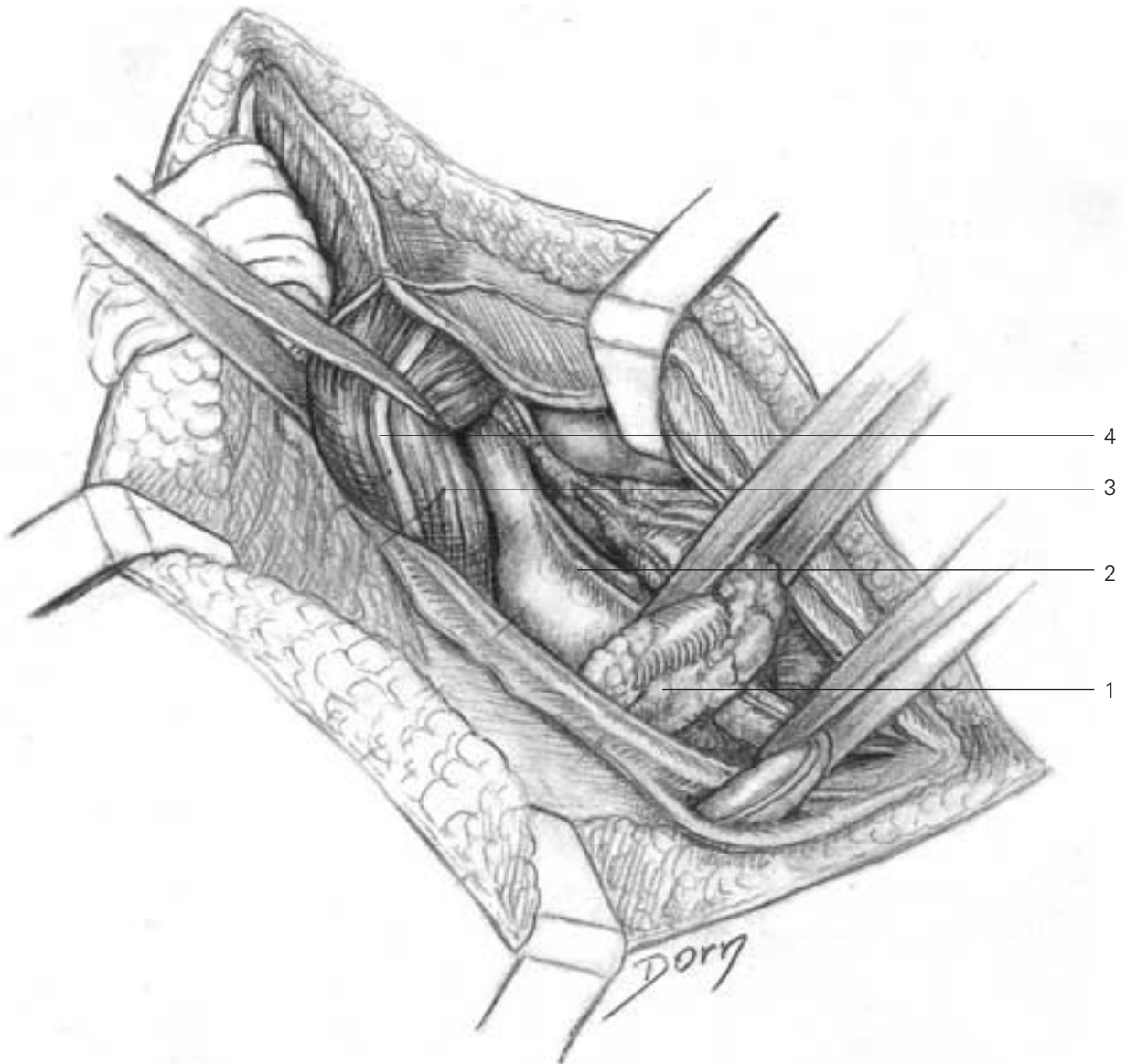
Lower limb surgery

C All the structures are held and retracted by rubber slings. Medial retraction of the iliopsoas provides access to the iliac fossa.



- C**
- 1 spermatic cord
 - 2 external iliac vessels sheath
 - 3 ilio psoas
 - 4 sacroiliac joint
 - 5 lateral cutaneous nerve of the thigh
 - 6 femoral nerve
 - 7 inguinal ligament

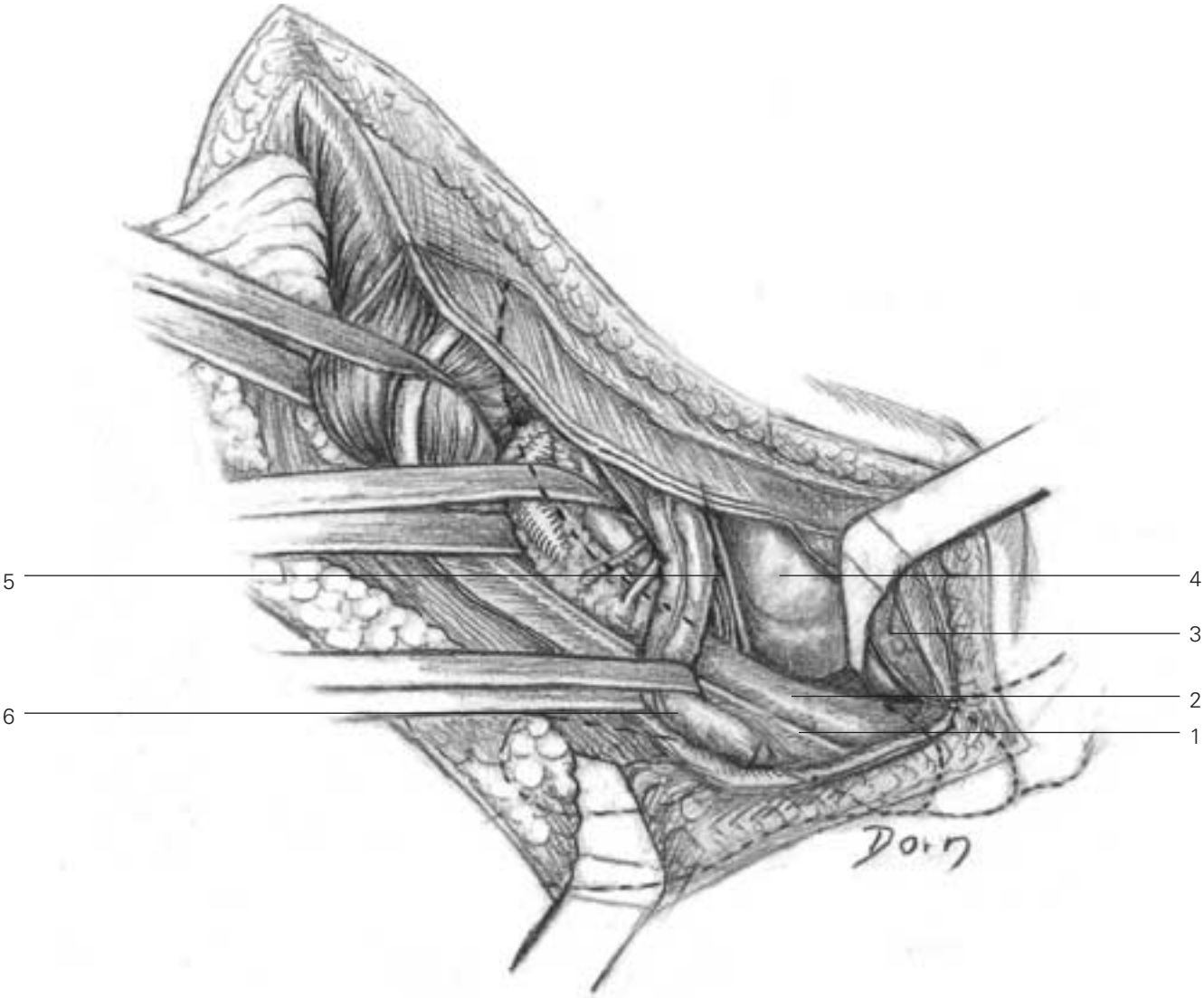
D Lateral retraction of the iliopsoas gives access to the pelvic brim.



- D**
- 1 external iliac vessels
 - 2 ilio pectineal eminence
 - 3 ilio psoas
 - 4 femoral nerve

Lower limb surgery

E Lateral retraction of the vessels and spermatic cord gives access to the superior pubic ramus.

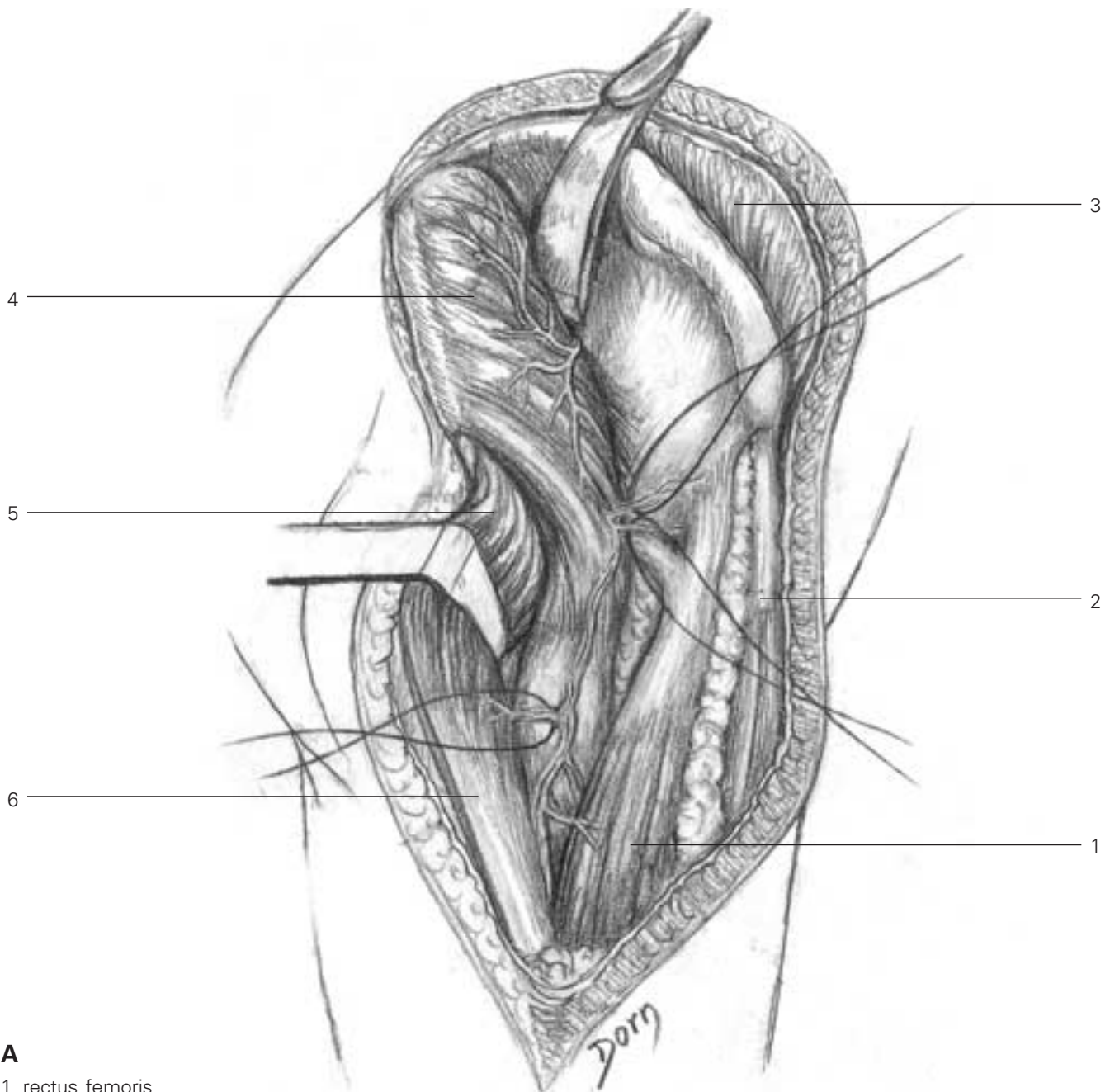


- E**
- 1 inguinal ligament
 - 2 superior pubic rami
 - 3 rectus abdominus
 - 4 urinary bladder
 - 5 neurovascular obturator bundle
 - 6 spermatic cord

Extended iliofemoral approach to the acetabulum

This approach is also indicated in fractures of both columns.

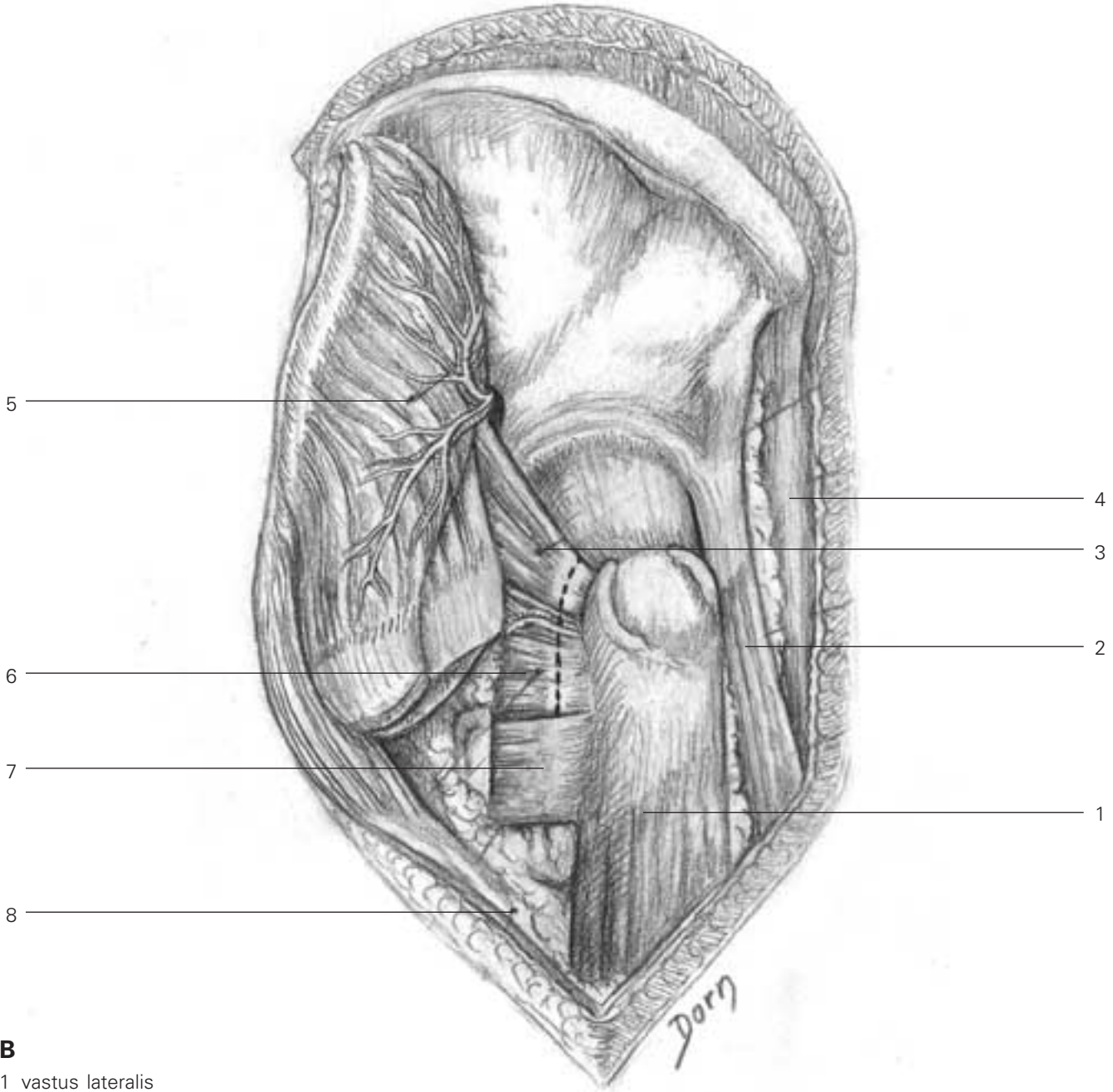
A The gluteal muscles are reflected from the external iliac wing.



- A**
- 1 rectus femoris
 - 2 sartorius
 - 3 iliacus
 - 4 gluteus medius
 - 5 tensor fasciae latae
 - 6 fascia lata

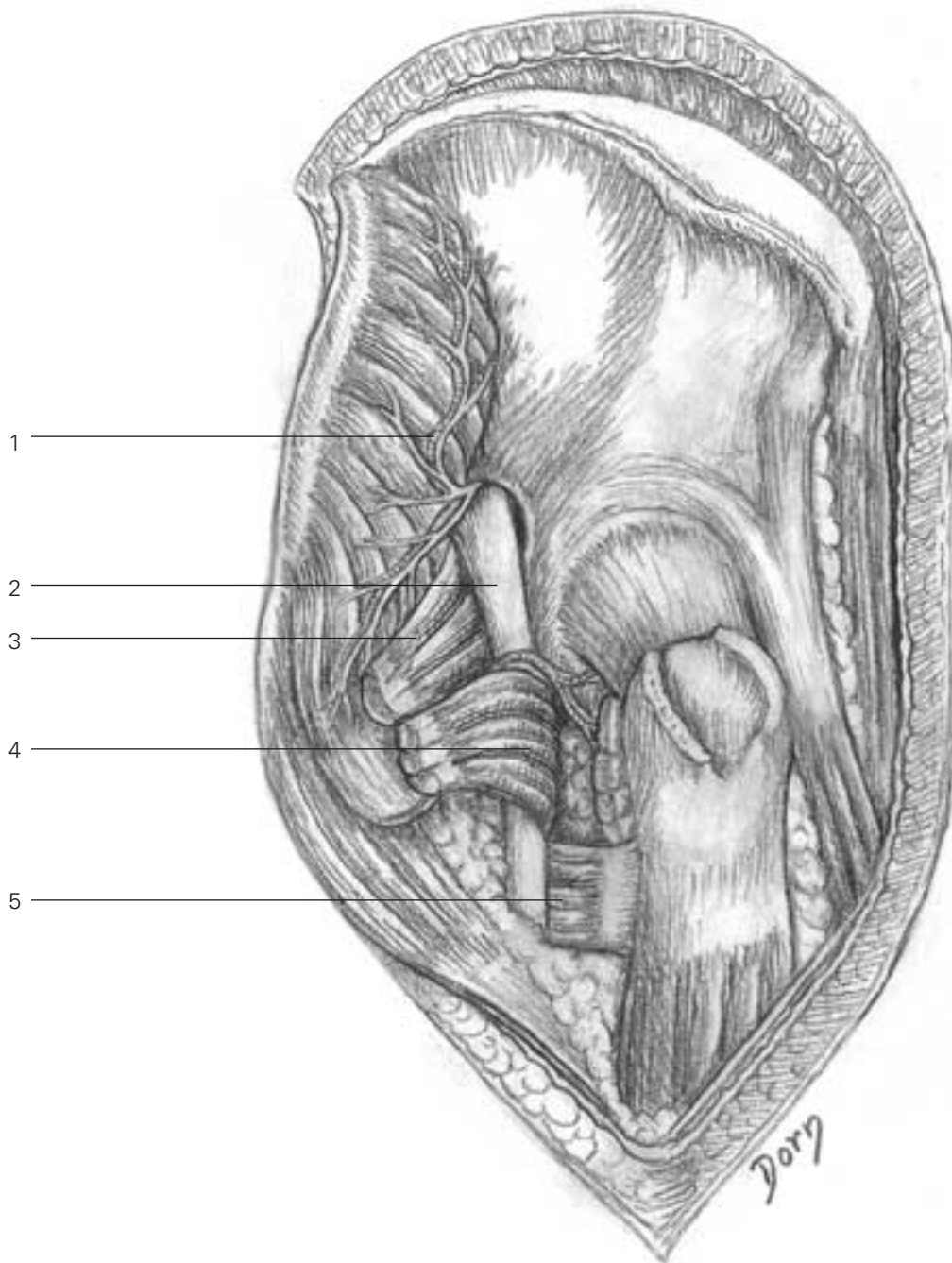
Lower limb surgery

B The insertions of gluteus minimus and gluteus medius have been divided. The massive muscular flap comprising the gluteal muscles and tensor fascia latae is retracted posteriorly, exposing the short external rotators.



- B**
- 1 vastus lateralis
 - 2 rectus femoris
 - 3 piriformis
 - 4 sartorius
 - 5 gluteus medius
 - 6 pelvitrochanteric muscles
 - 7 quadratus femoris
 - 8 distal tendon of gluteus maximus

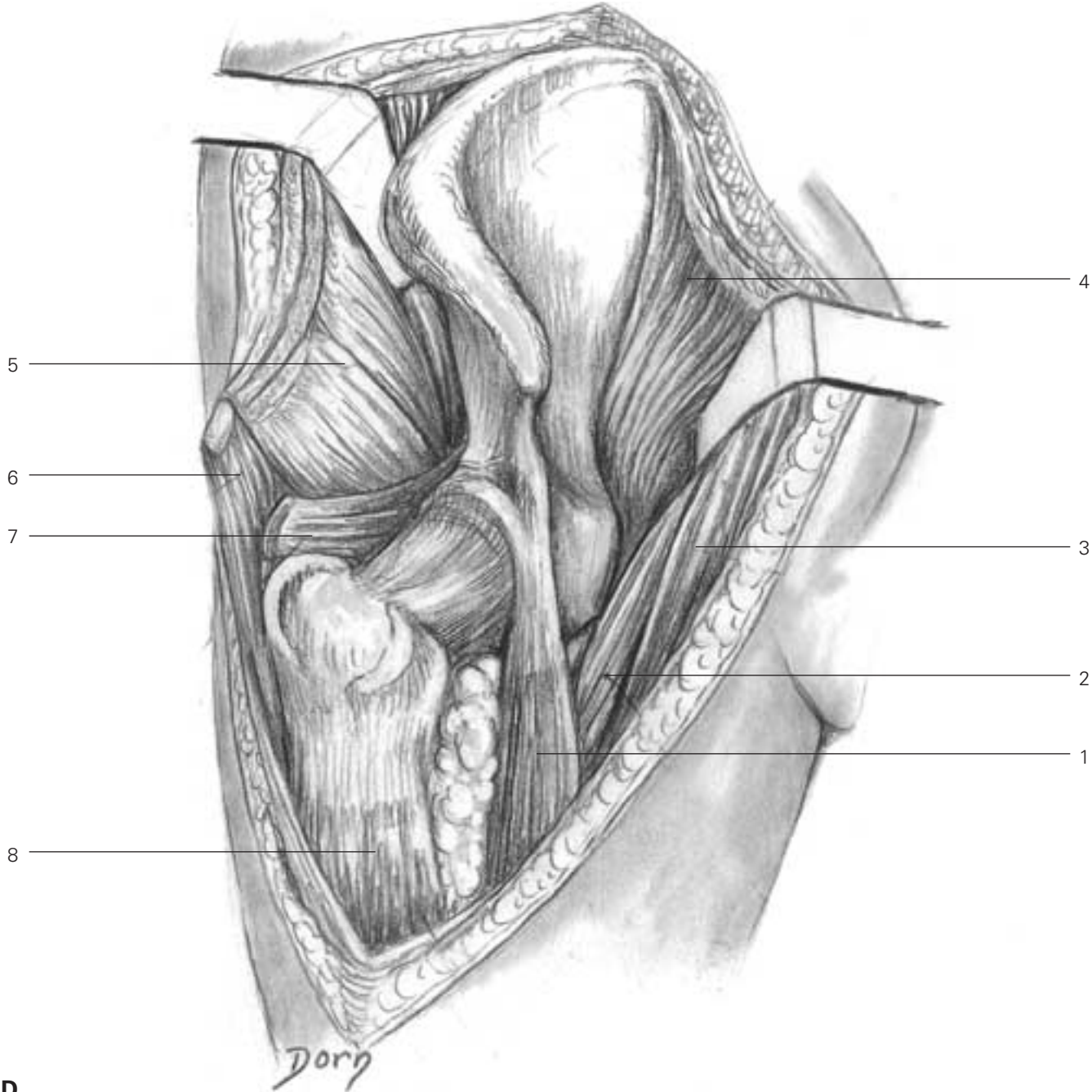
C The short rotators have been divided and retracted. Retraction of the piriformis exposes the sciatic nerve. The whole acetabulum is visible.



- C**
- 1 superior gluteal pedicle and nerve
 - 2 sciatic nerve
 - 3 piriformis
 - 4 obturator internus and the gemelli
 - 5 quadratus femoris

Lower limb surgery

D Elevation of the iliacus, sartorius and inguinal ligament gives access to the internal iliac fossa.

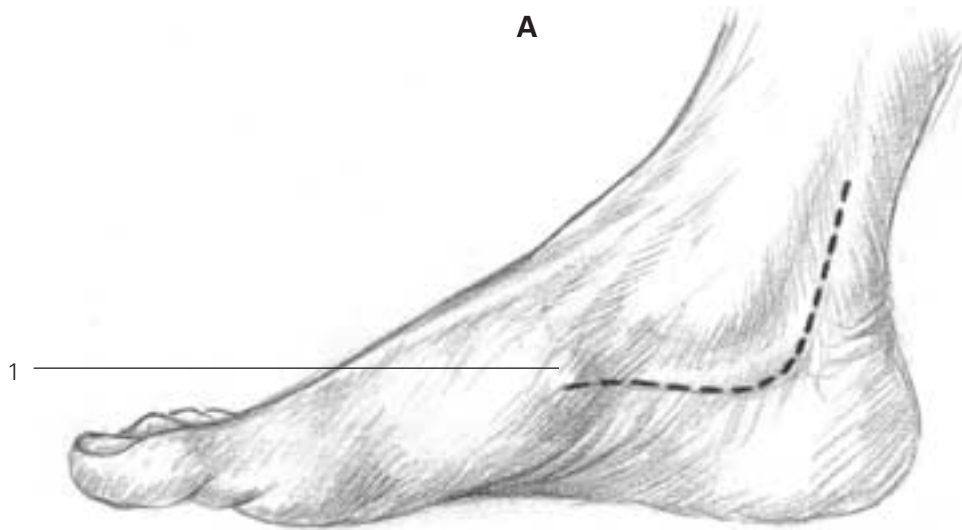


- D**
- 1 rectus femoris
 - 2 iliopsoas
 - 3 sartorius
 - 4 iliacus
 - 5 glutei
 - 6 tensor fasciae latae
 - 7 piriformis
 - 8 vastus lateralis

Approaches to the foot and ankle

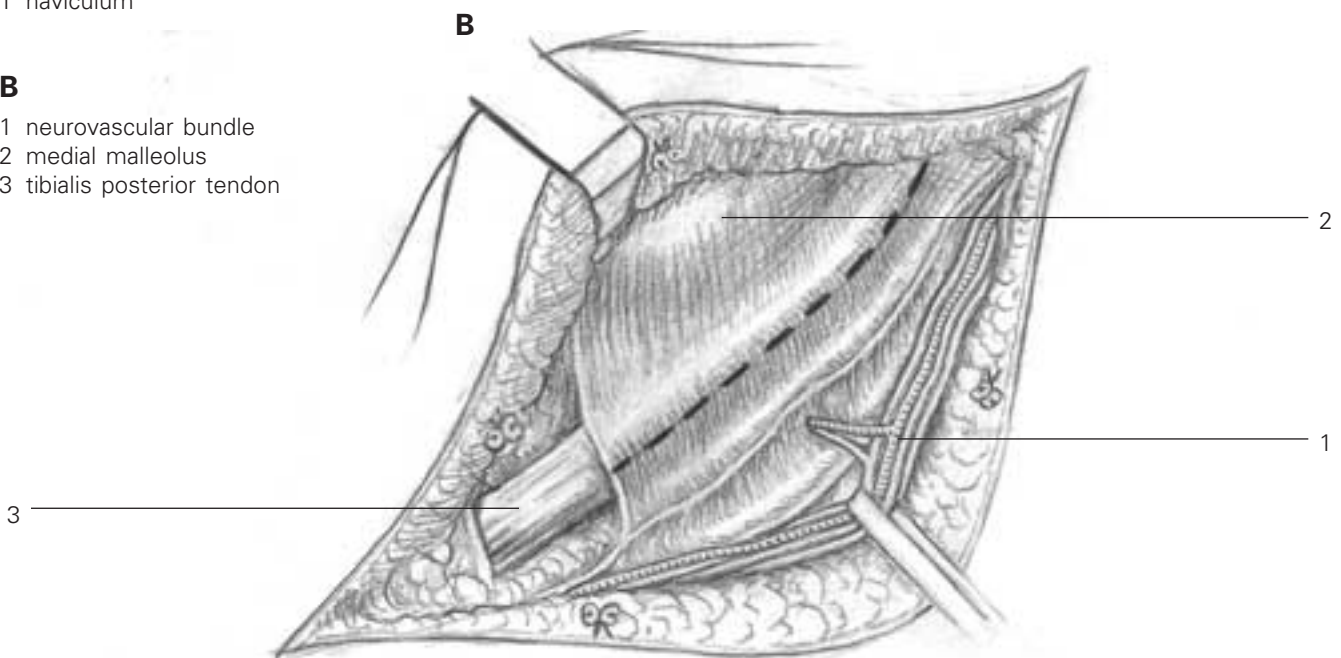
Posteromedial approach to the ankle

A, B Skin incision. The flexor retinaculum is incised in line with the skin. The neurovascular bundle is identified.



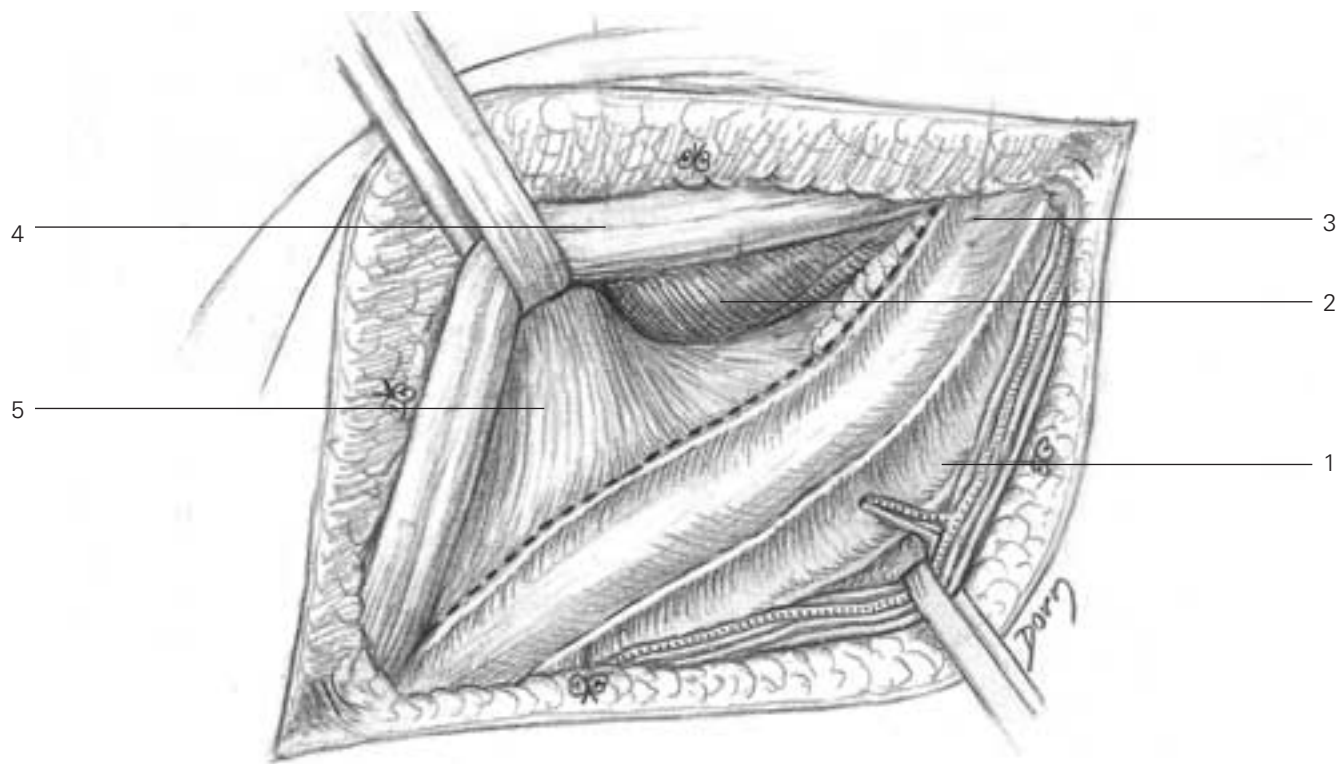
A
1 naviculum

B
1 neurovascular bundle
2 medial malleolus
3 tibialis posterior tendon



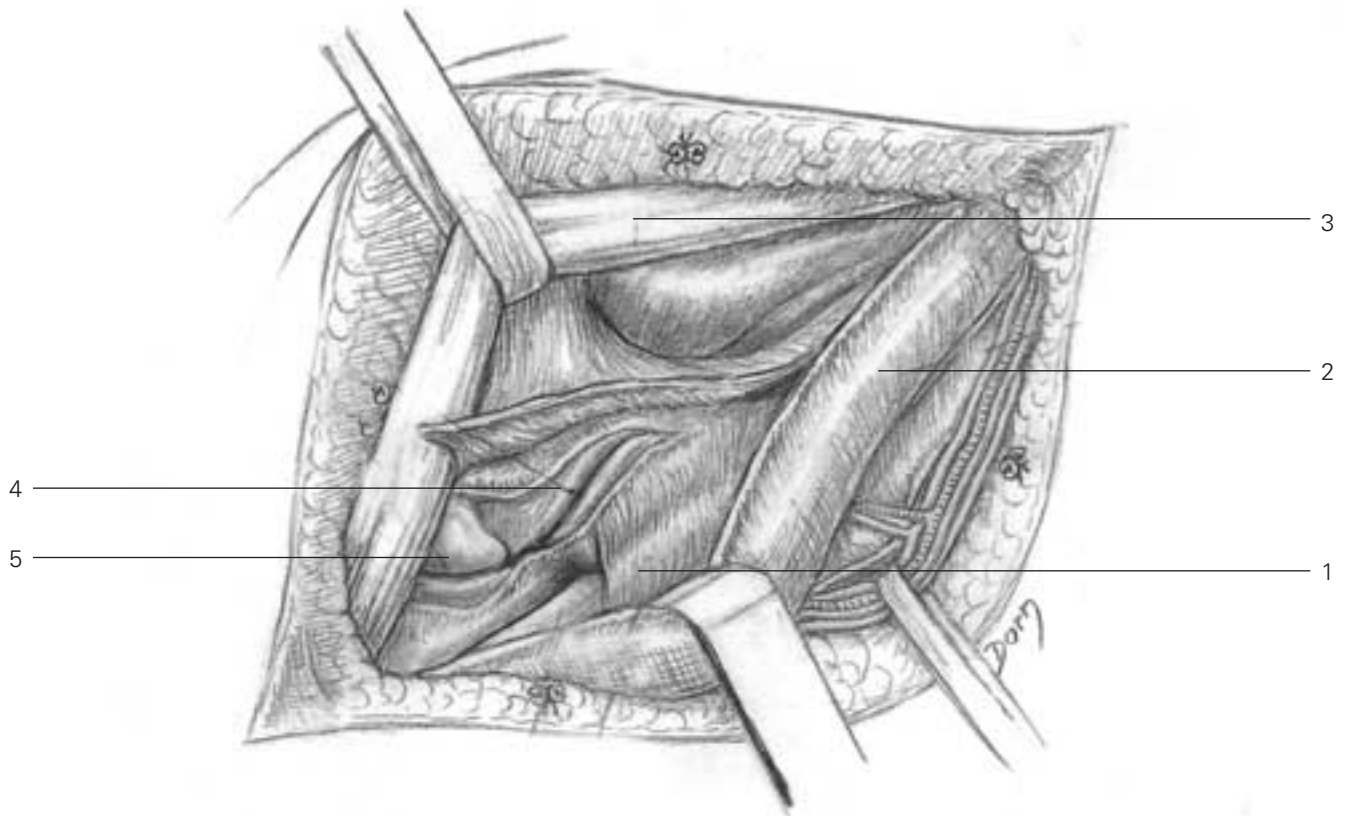
Lower limb surgery

C The tendon of tibialis posterior is retracted anteriorly exposing the deltoid ligament.



- C**
- 1 neurovascular bundle sheath
 - 2 malleolus medialis
 - 3 tendon of flexor digitorum longus within its sheath
 - 4 tibialis posterior tendon
 - 5 deltoid ligament

D The capsule is incised, giving access to the subtalar joint and the posterior aspect of the ankle, chiefly if Achilles' tendon has been divided.



D

- 1 flexor hallucis longus
- 2 flexor digitorum longus retracted
- 3 tibialis posterior tendon
- 4 subtalar joint
- 5 head of talus

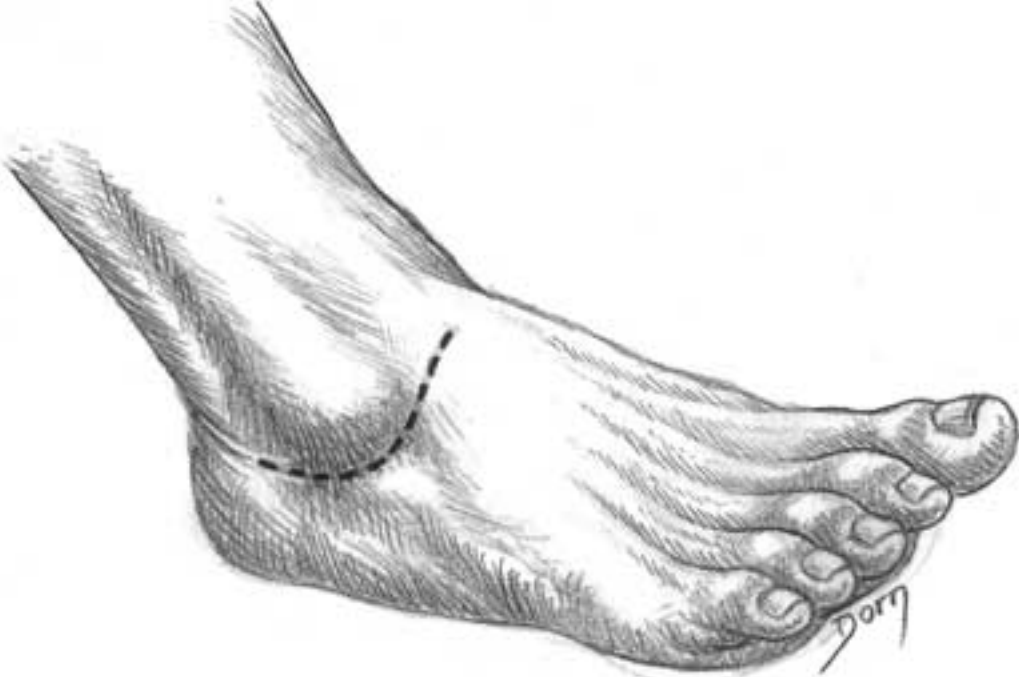Lower limb surgery

Lateral approach to the subtalar and midtarsal joint

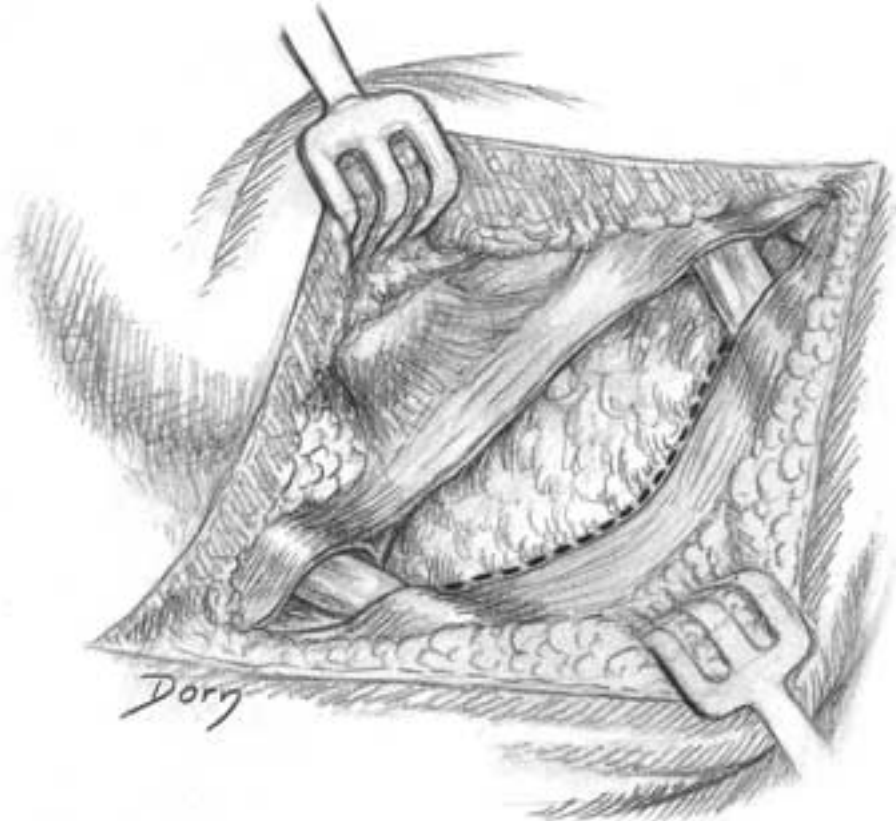
This exposure is used for fusion of the joints.

A, B Skin incision, exposing the inferior extensor retinaculum.

A



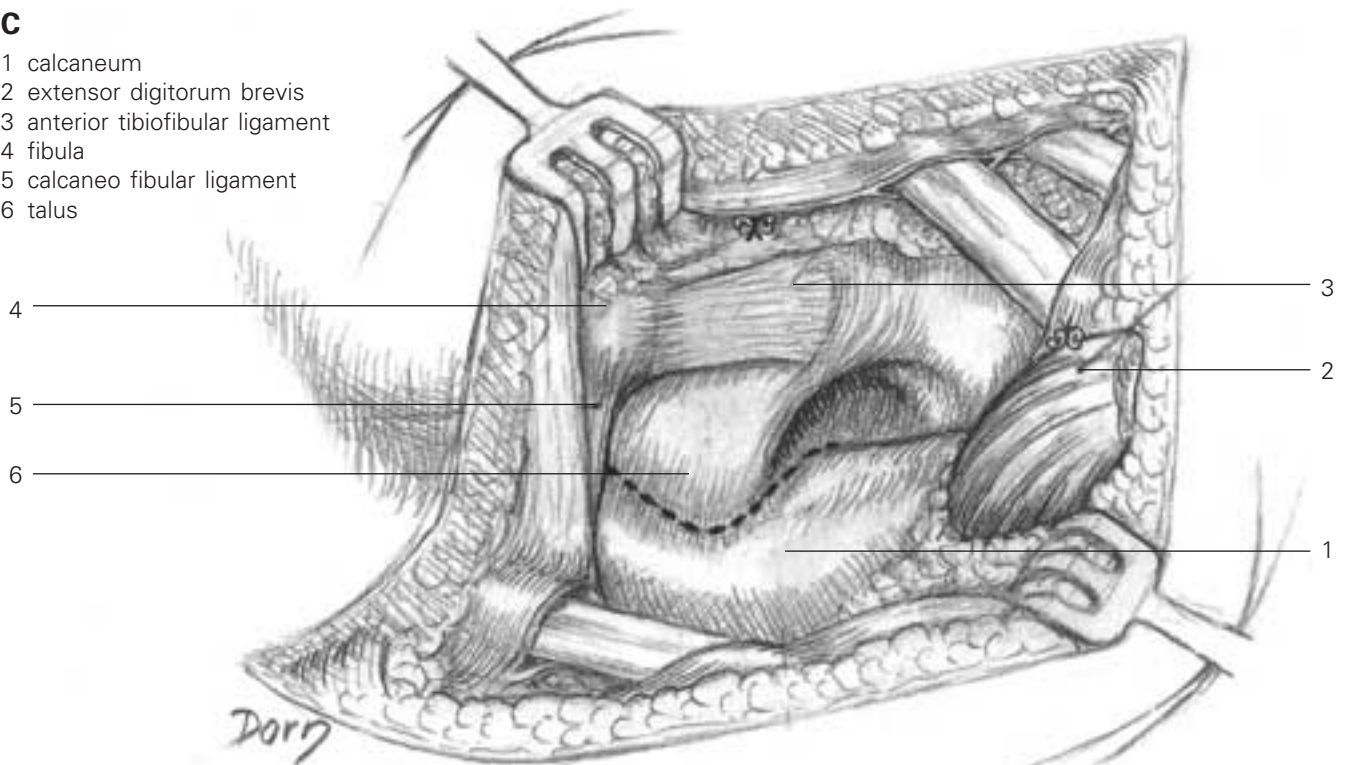
B



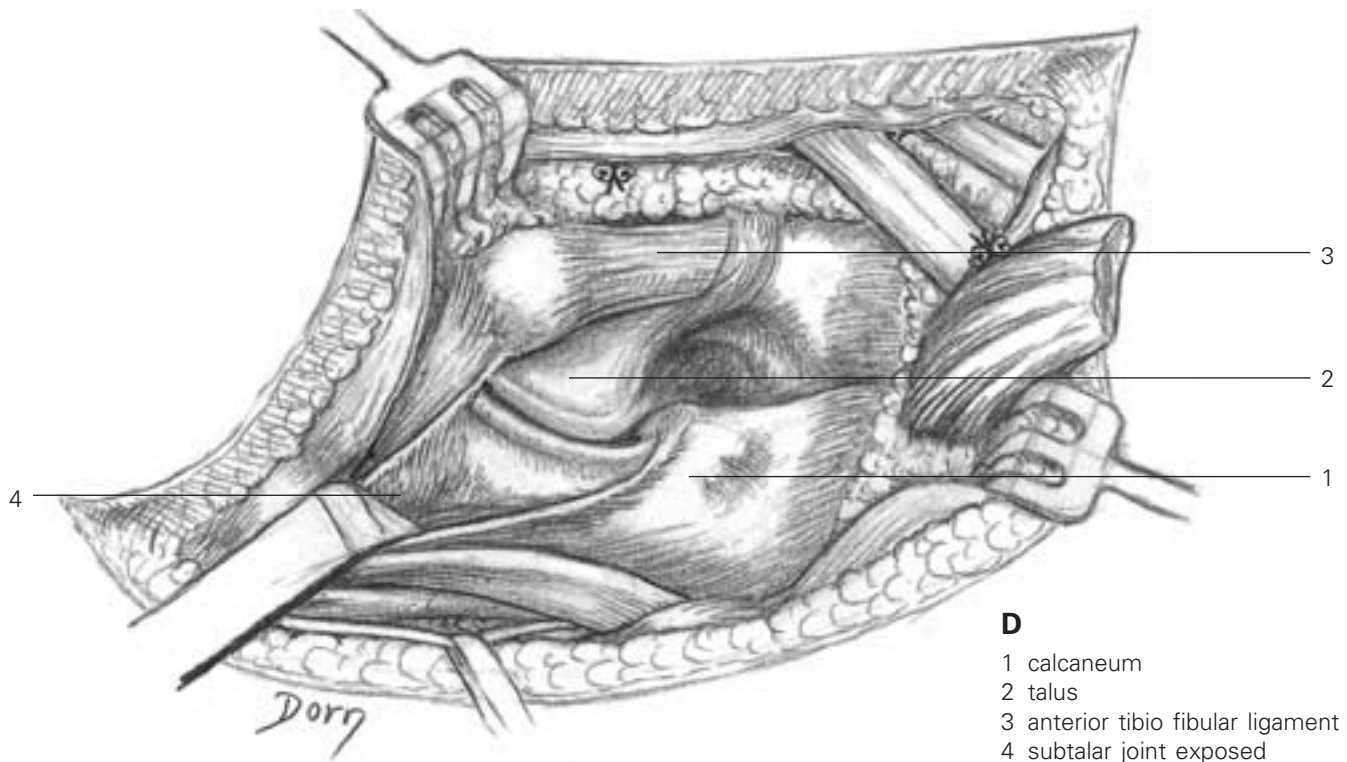
C The extensor digitorum brevis muscle is detached to expose the subtalar joint.

C

- 1 calcaneum
- 2 extensor digitorum brevis
- 3 anterior tibiofibular ligament
- 4 fibula
- 5 calcaneo fibular ligament
- 6 talus



D The subtalar joint and the talonavicular and calcaneocuboid joints are exposed.



D

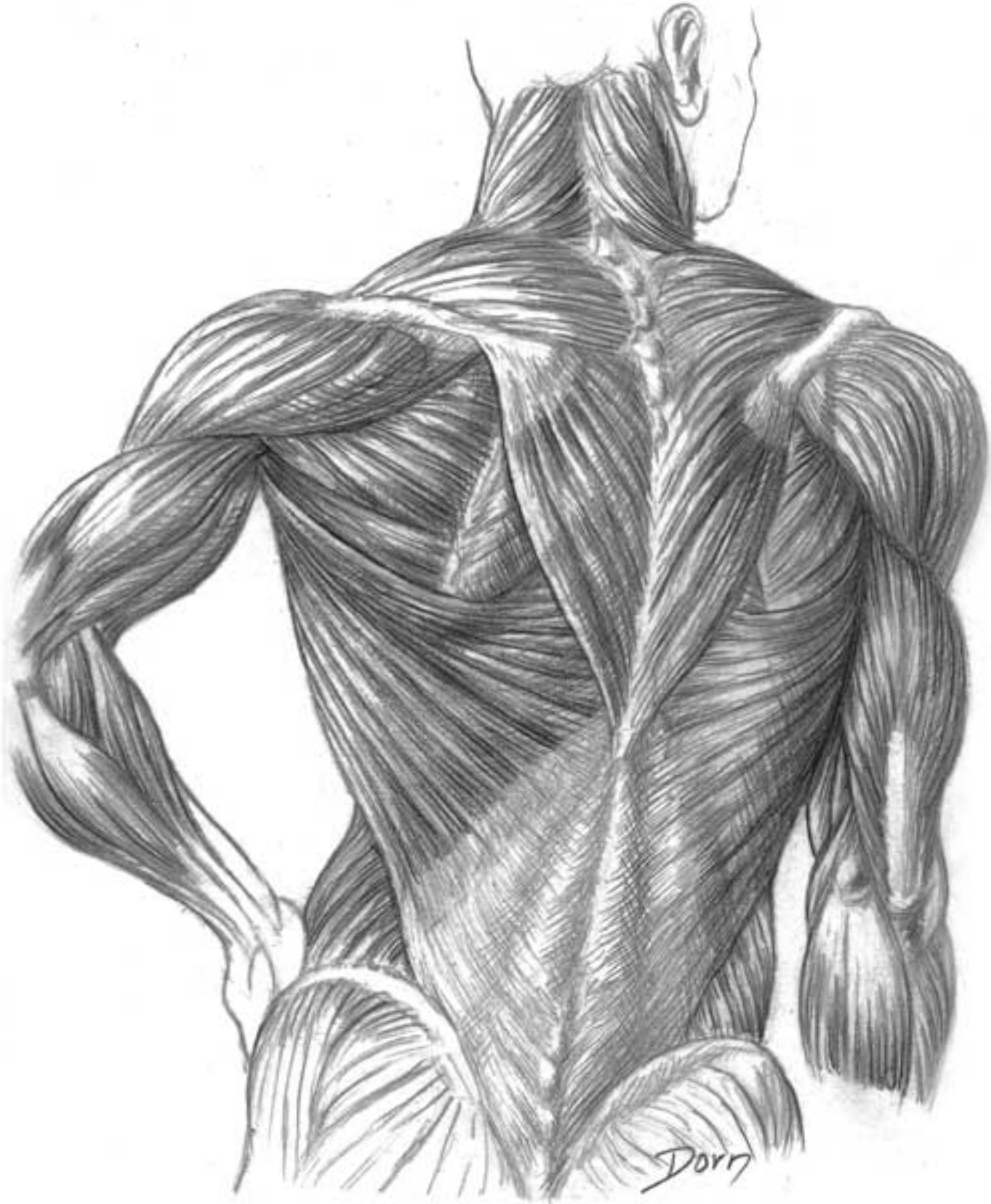
- 1 calcaneum
- 2 talus
- 3 anterior tibio fibular ligament
- 4 subtalar joint exposed

Miscellaneous

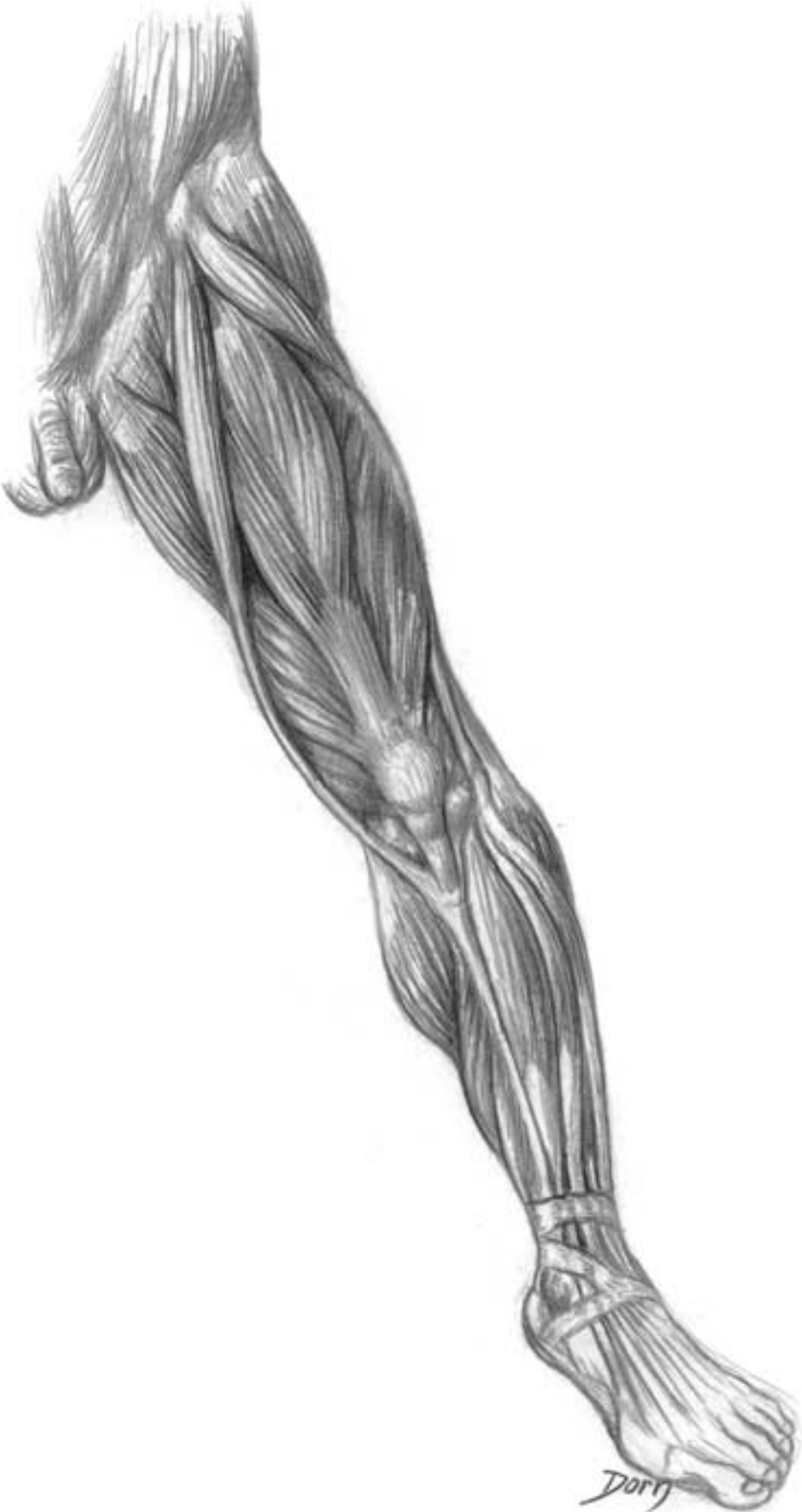Muscular studies

The shape of the human body is very attractive for a medical illustrator.

Studies of the muscular relief were one of the main interests of the artists of the Renaissance. It can be said that one of the motivations for dissection during this period was to understand how the muscles contribute to the shape of the body. The following drawings of Léon Dorn, particularly the first one, recall the 'écorché of Vésale'. The difference is that Vésale's man seems to be very anxious while Dorn's has a relaxed (modern) attitude.





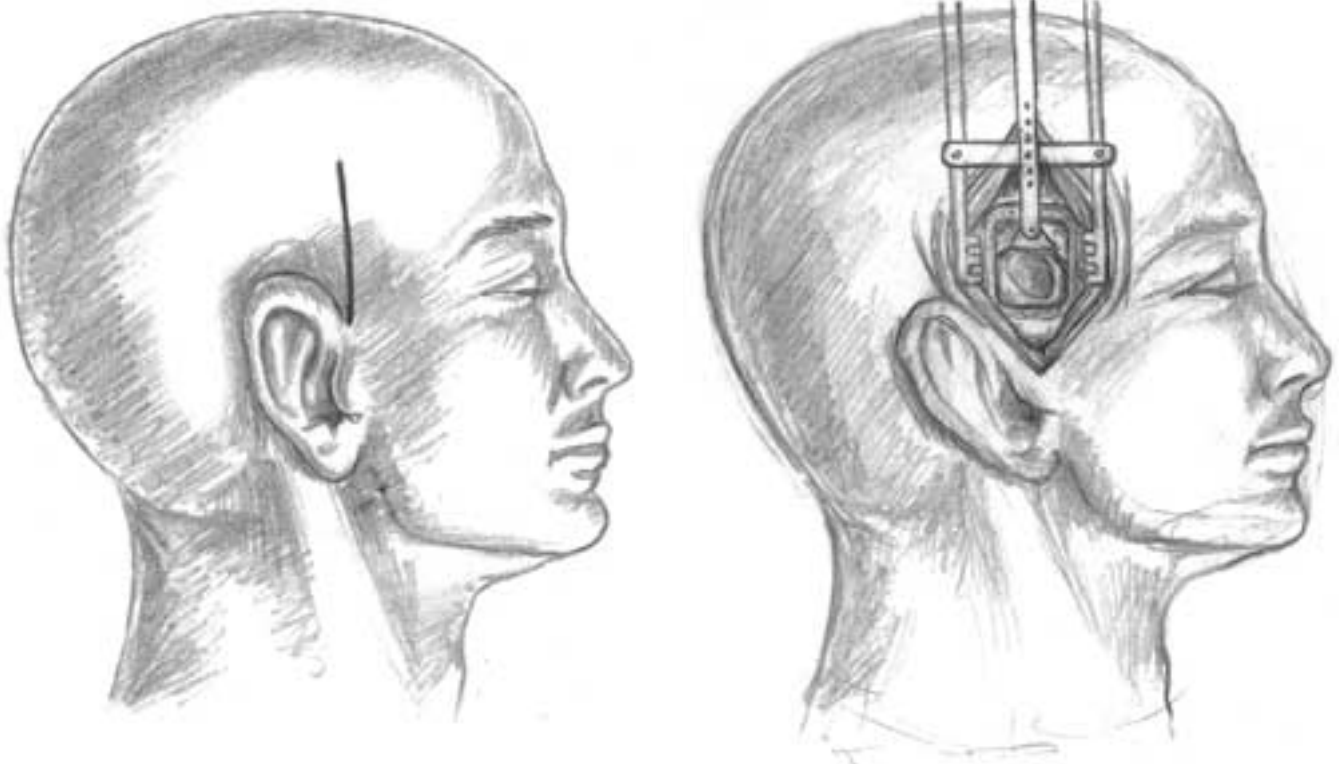


Surgery of the ear

A series of drawings showing the boundary between neurosurgery and ear surgery

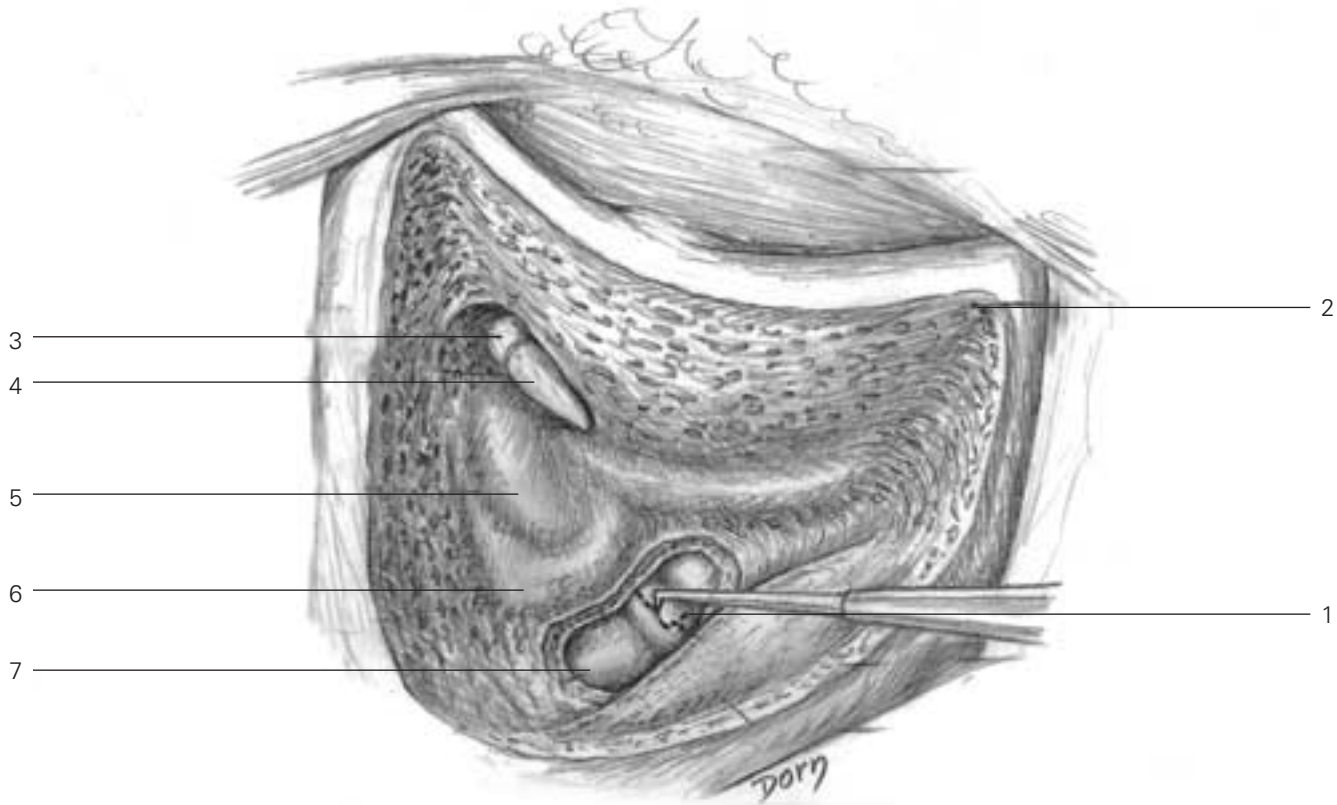
The first three drawings are devoted to the approach through the skull. The dura mater has been opened which allows exposure of the facial and other nerves.

A Exposure of a tumour of the vestibular nerve by a retroauricular and transvestibular approach.



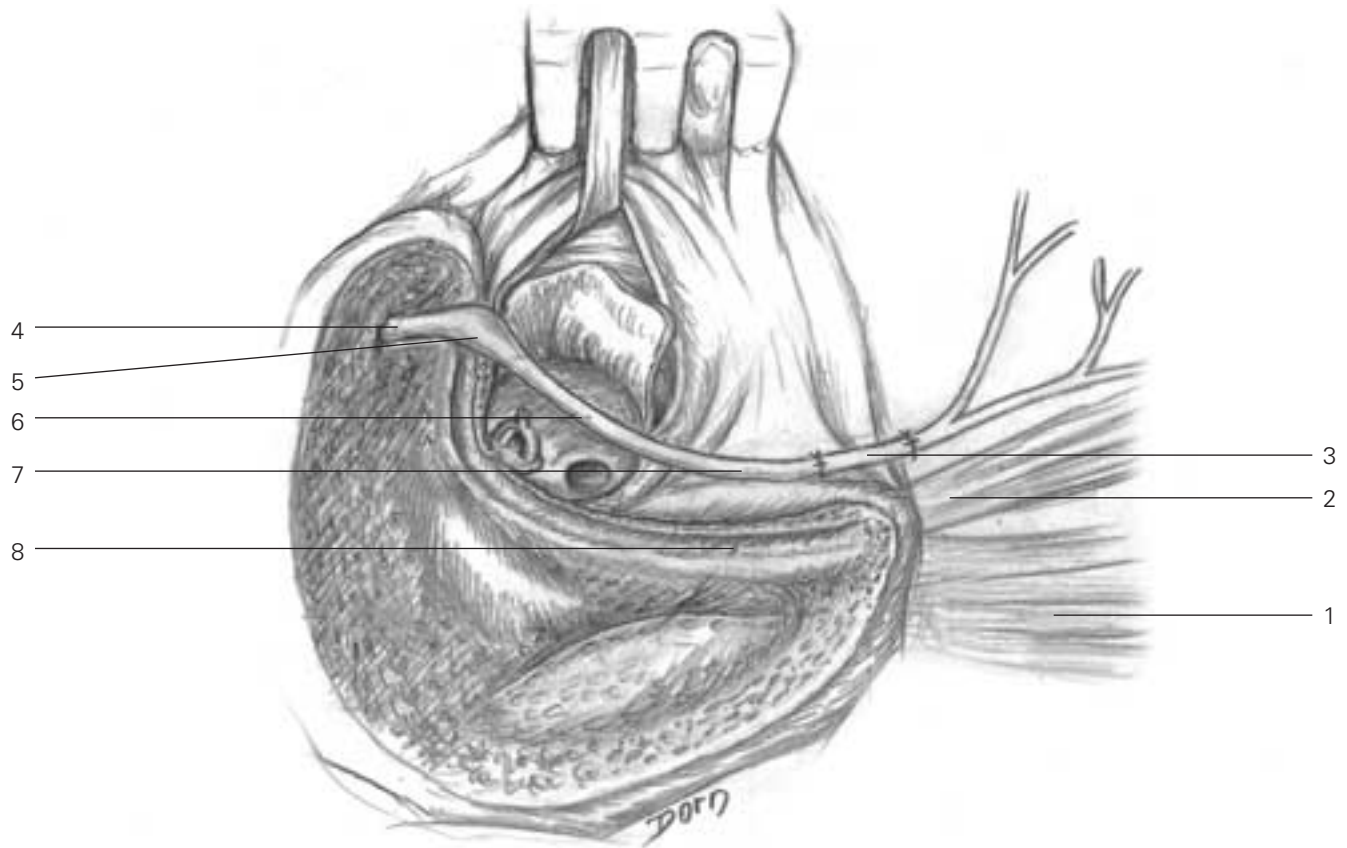
Miscellaneous

B Opening of the endolymphatic sac in a case of Ménière's disease.



- B**
- 1 opening of the endolymphatic sac
 - 2 mastoid cortex
 - 3 malleus (head of malleus)
 - 4 incus (short process)
 - 5 lateral semicircular canal
 - 6 posterior semicircular canal
 - 7 stripped cerebellum dura mater

C Transmastoid approach to expose the second and third parts of the facial nerve, which is taken out of the Fallopian aqueduct.

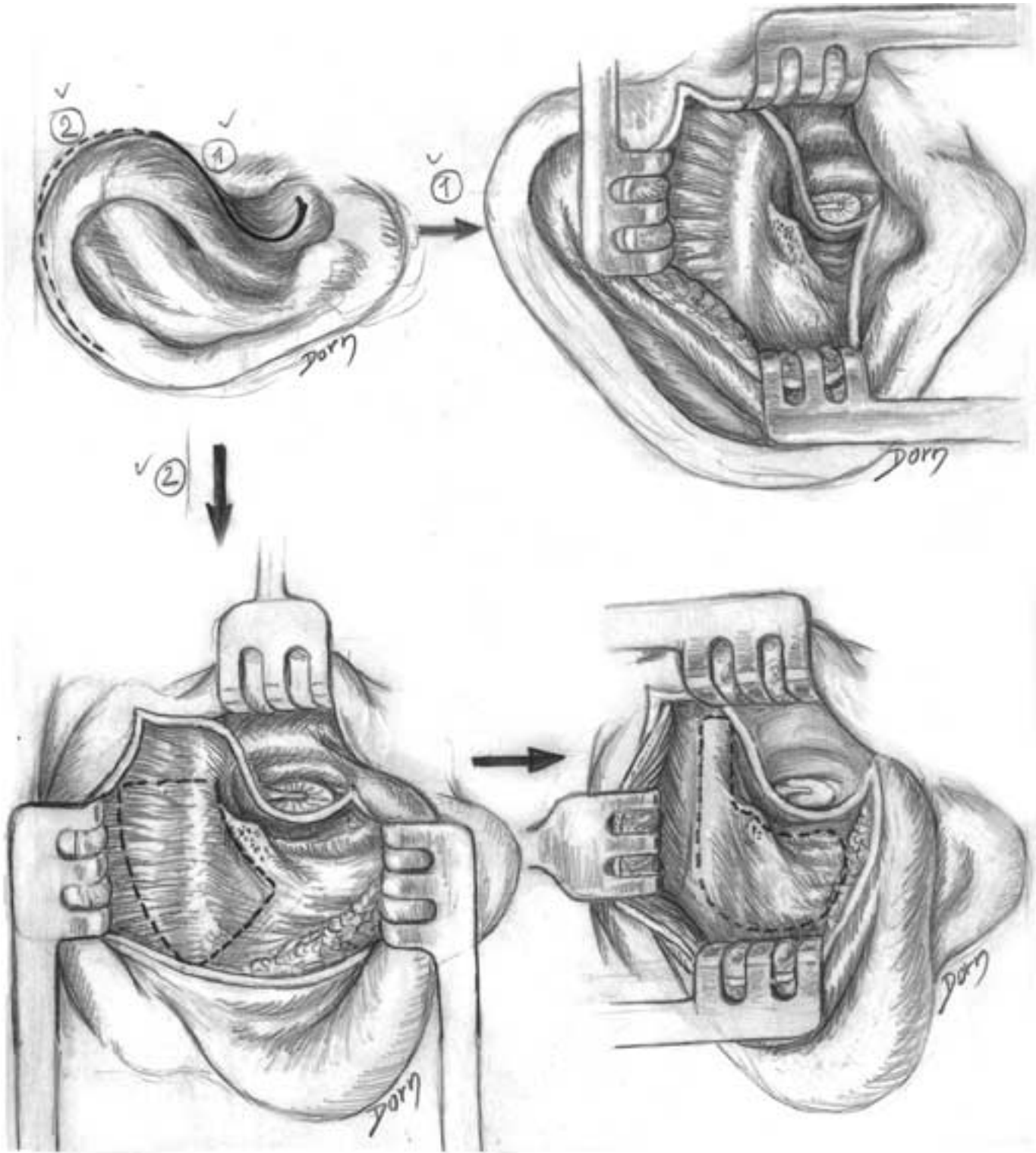


- C**
- 1 sternocleidomastoid muscle
 - 2 digastric muscle
 - 3 facial nerve grafting
 - 4 labyrinthine segment of the facial nerve
 - 5 geniculate ganglion of the facial nerve
 - 6 tympanic segment of the facial nerve
 - 7 mastoid segment of the facial nerve
 - 8 empty Fallopian aqueduct

Miscellaneous

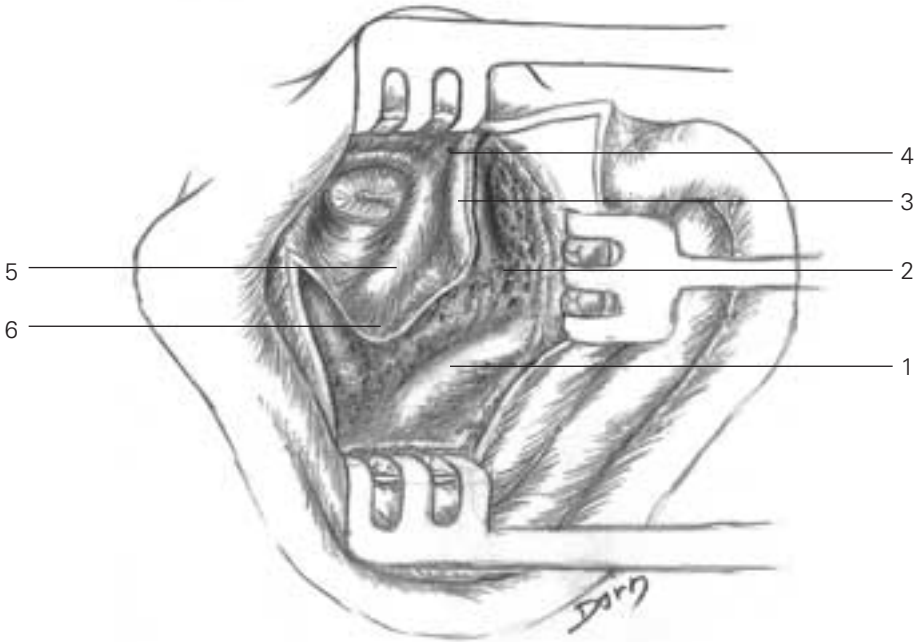
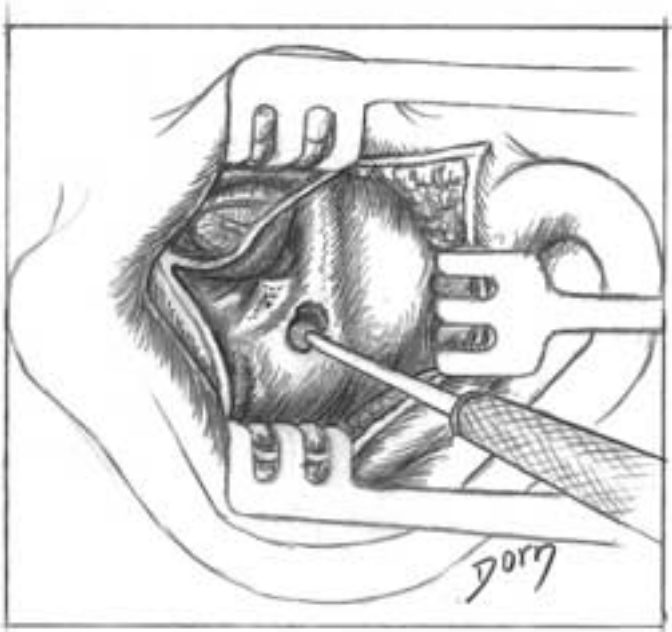
Surgery of the middle ear

A The transmeatal and extended transmeatal approaches to the middle ear, which allows harvesting a temporal fascia graft.



B The Shambaugh approach allows grooving of the cavities of the middle ear.

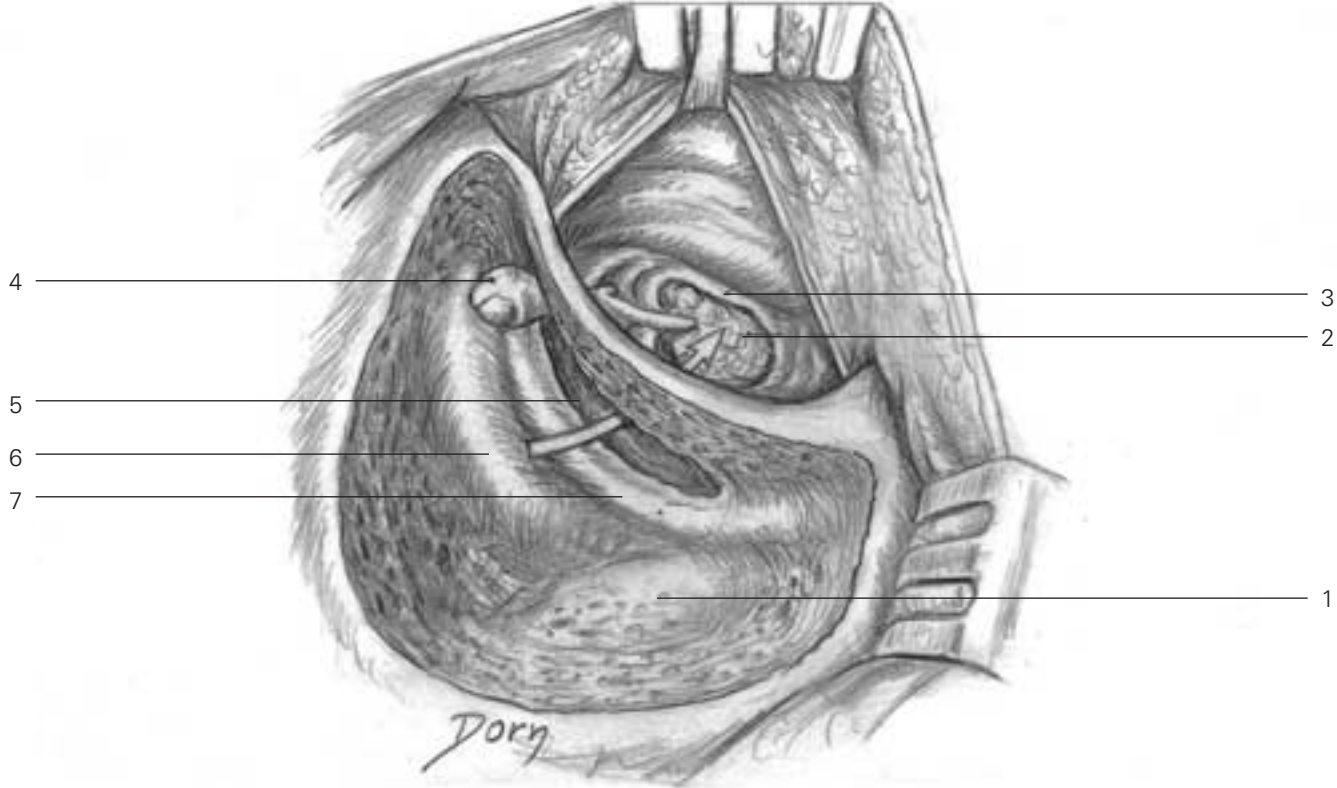
- B**
- 1 relief of sigmoid sinus
 - 2 antium opened
 - 3 lateral semicircular canal
 - 4 anterior epitypanum
 - 5 facial nerve
 - 6 canal wall skin



Miscellaneous

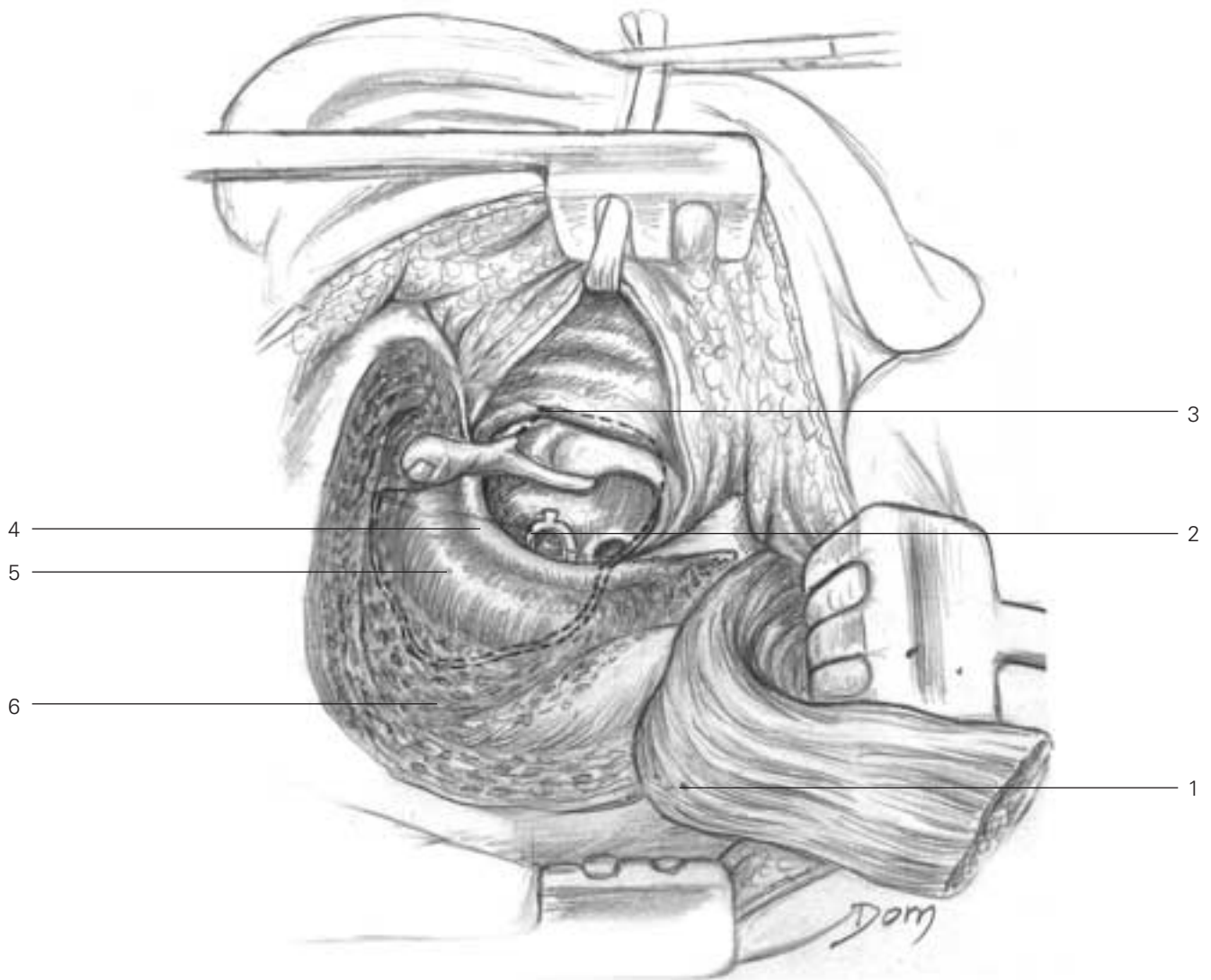
Tympanic graft

A Mastoidectomy (canal wall up procedure).



- A**
- 1 sigmoid sinus
- 2 cholesteatoma
- 3 perforated tympanic membrane
- 4 head of the malleus
- 5 posterior tympanectomy (facial recess opened)
- 6 lateral semicircular canal
- 7 facial nerve

B Exploration of the tympanic cavity, sparing the facial nerve. Mastoidectomy (canal wall down procedure) with tympanoplasty.

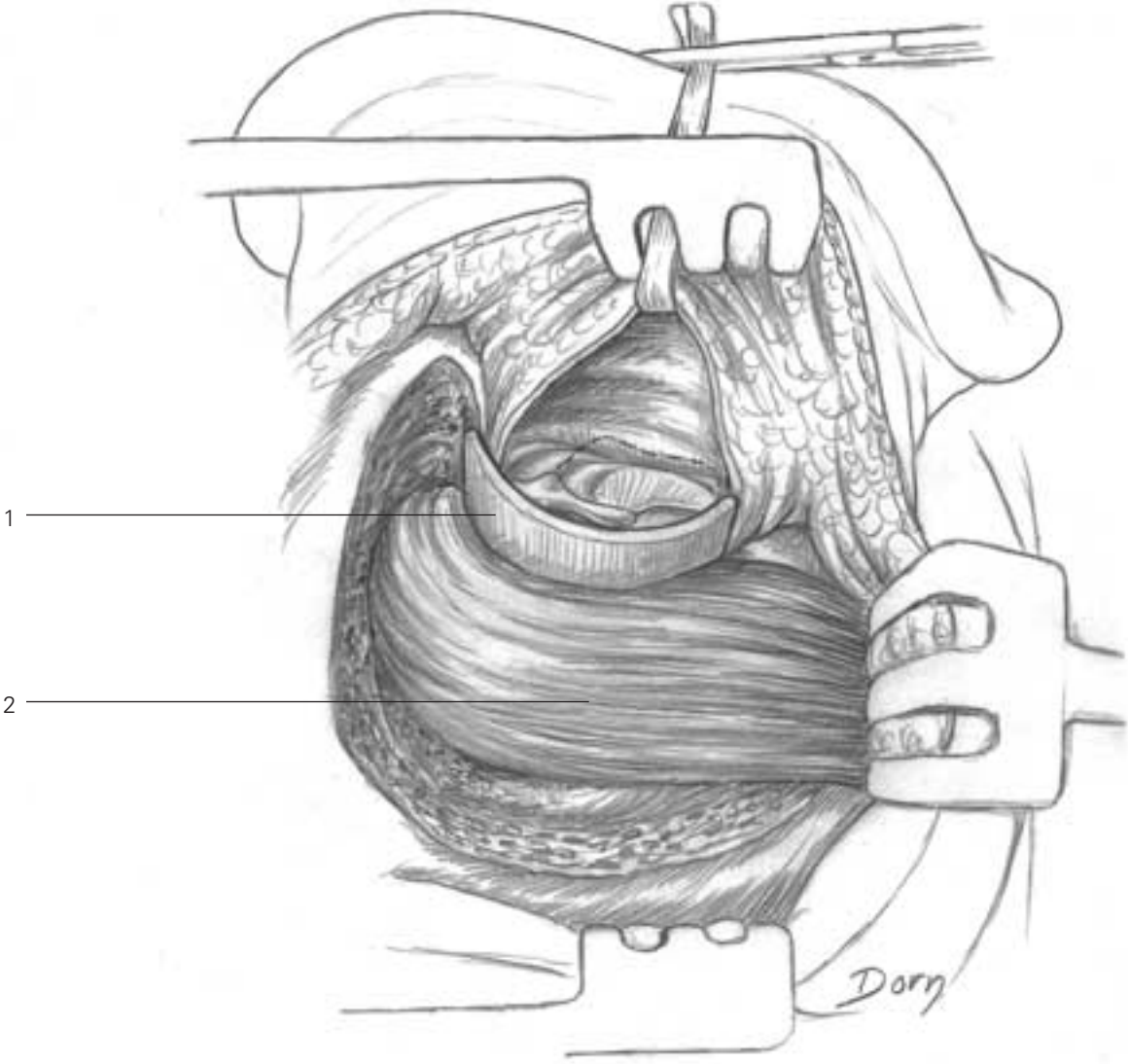


A

- 1 fibromuscular flap raised from the mastoidian and temporal muscles
- 2 stapes
- 3 temporal aponeurosis graft under the tympanic rests, on the facial nerve and the lateral semicircular canal
- 4 facial nerve
- 5 lateral semicircular canal
- 6 automastoidian cavity

Miscellaneous

C A muscular flap from the temporal muscle fills up the mastoid cavity. Reconstruction of the auditory canal.



- C**
- 1 temporal aponeurosis graft prefigures the final outer ear canal
 - 2 fascia temporalis graft and muscular flap of the temporalis muscle

Paediatrics

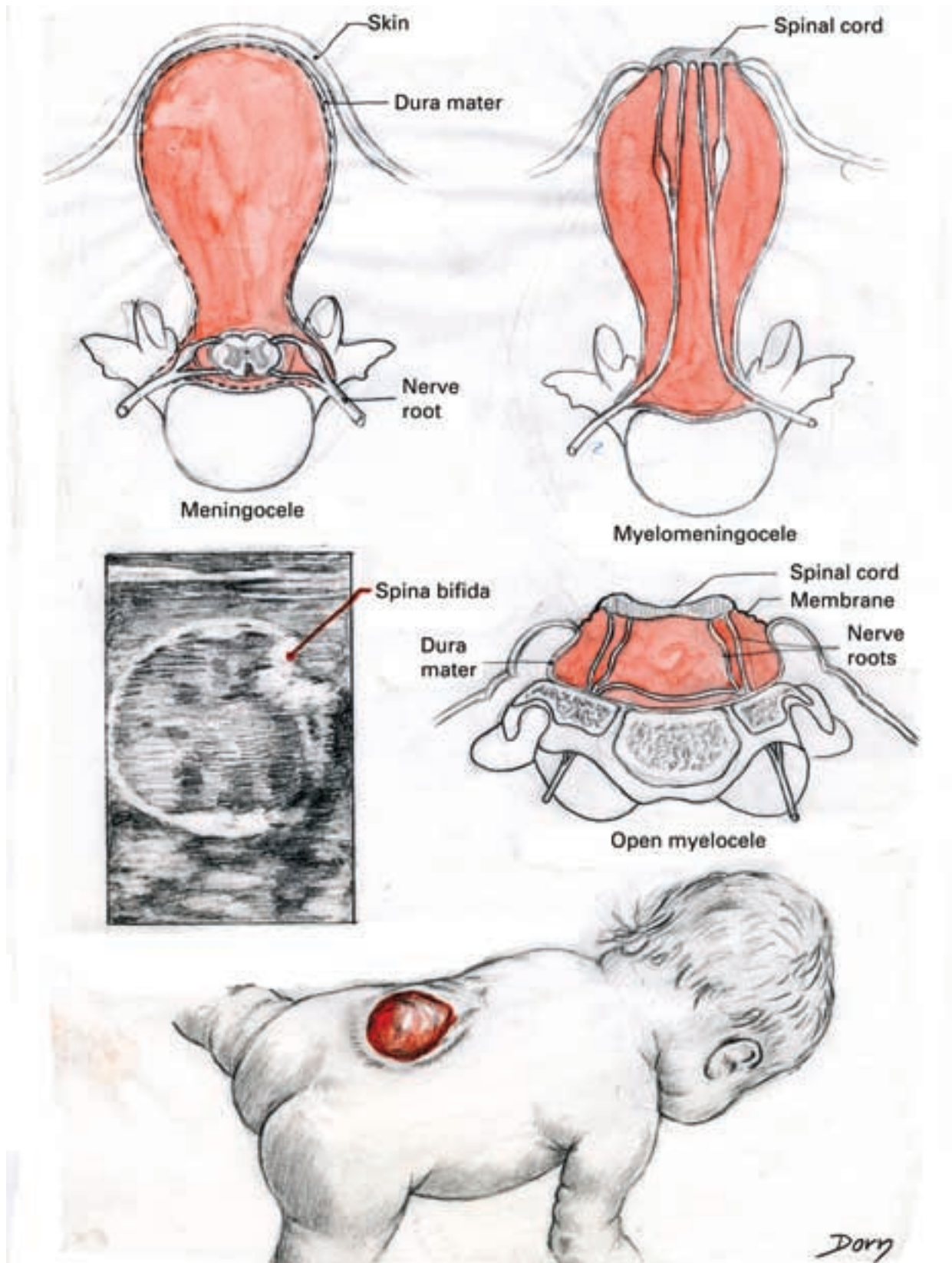
Crying baby with a Pavlick's harness to prevent hip dislocation or instability



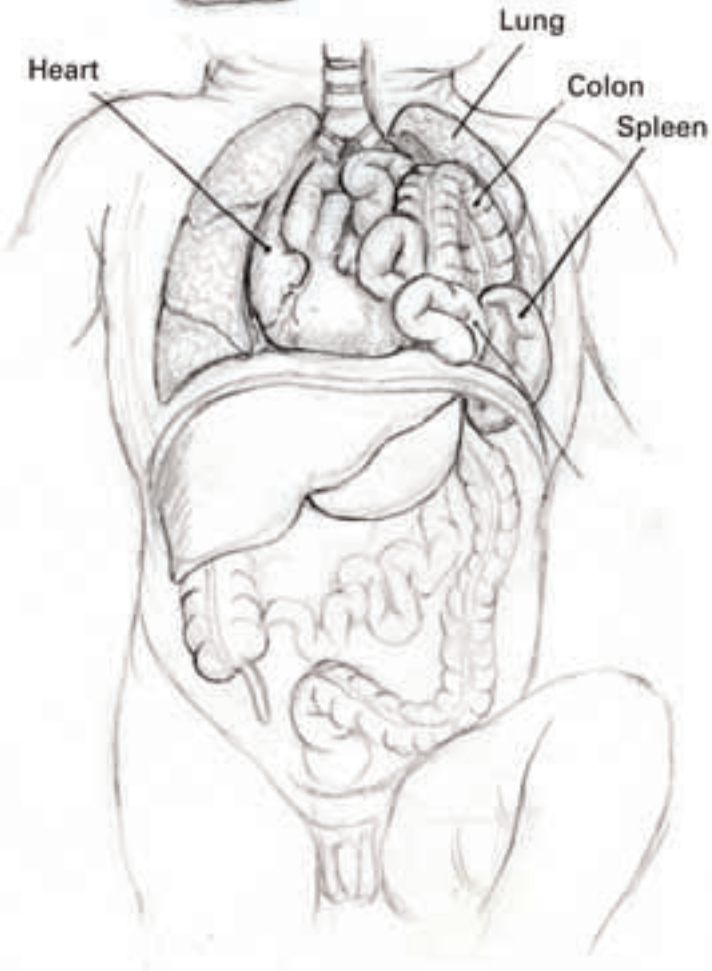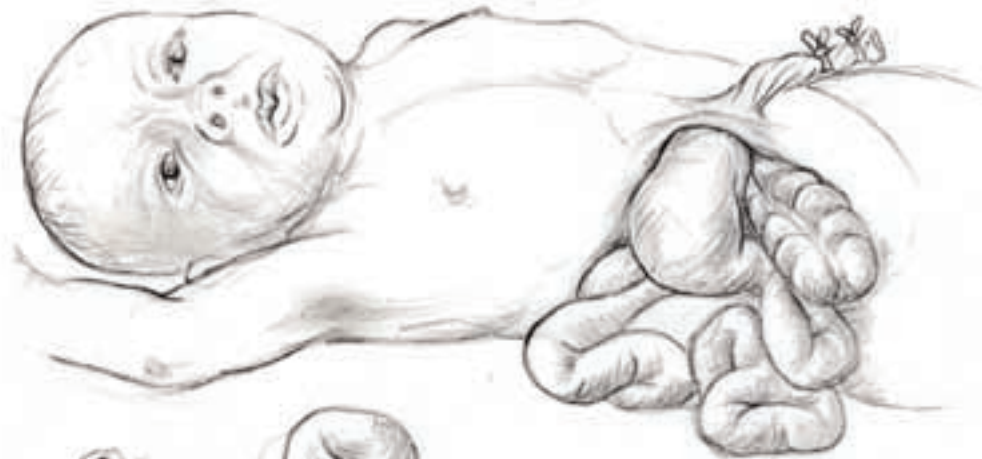Miscellaneous

Congenital malformations

Each plate shows the relation of the clinical aspect with the anatomical lesions and the ultrasound imaging aspect **A Myelomeningocele.**



B Laparoschisis.



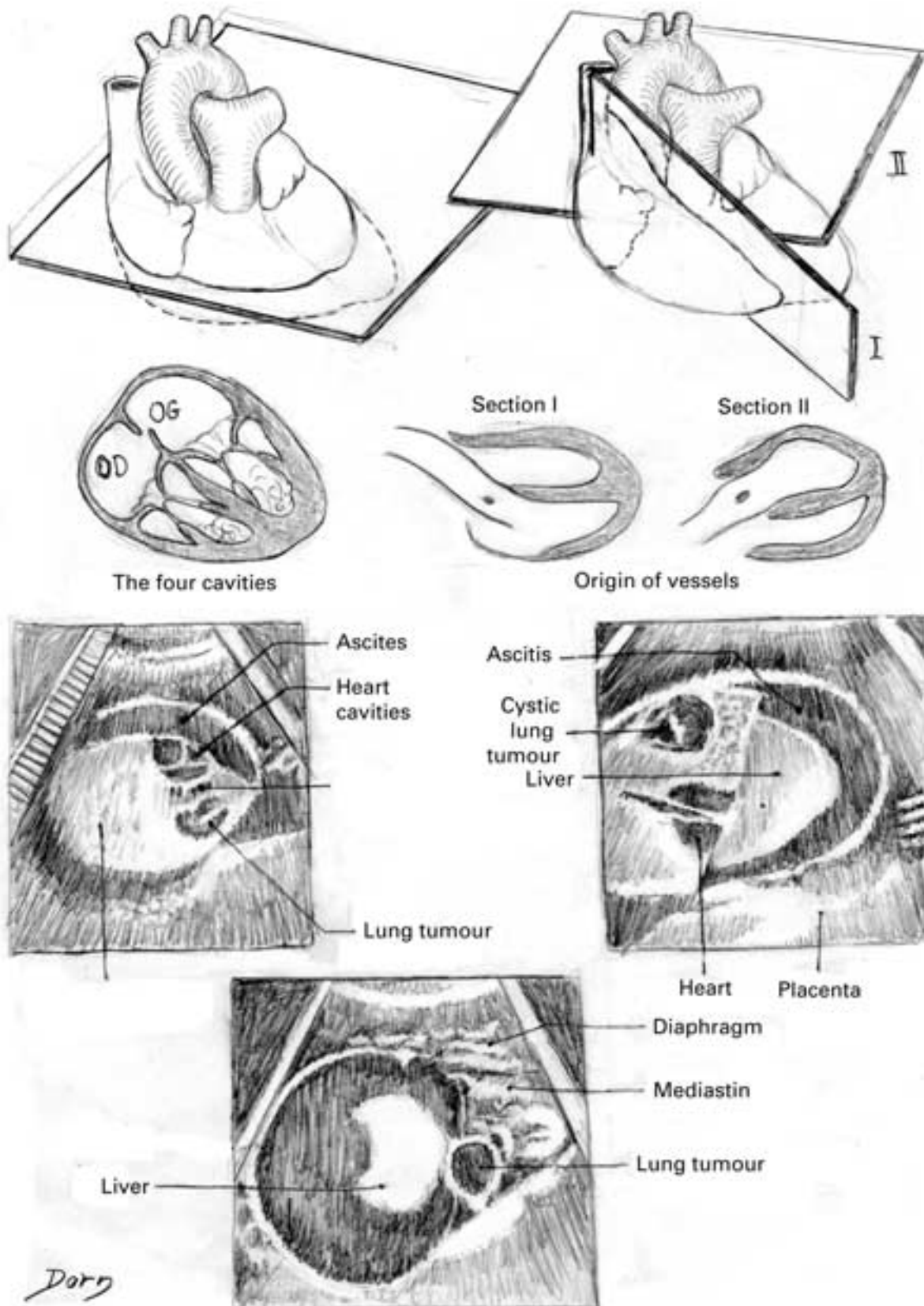
Diaphragmatic hernia



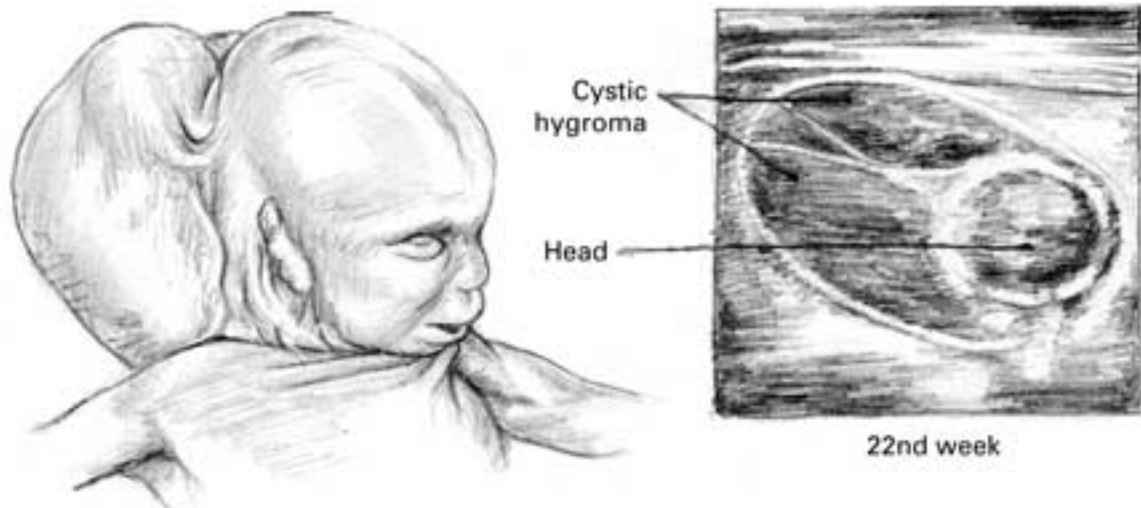
Dorn

Miscellaneous

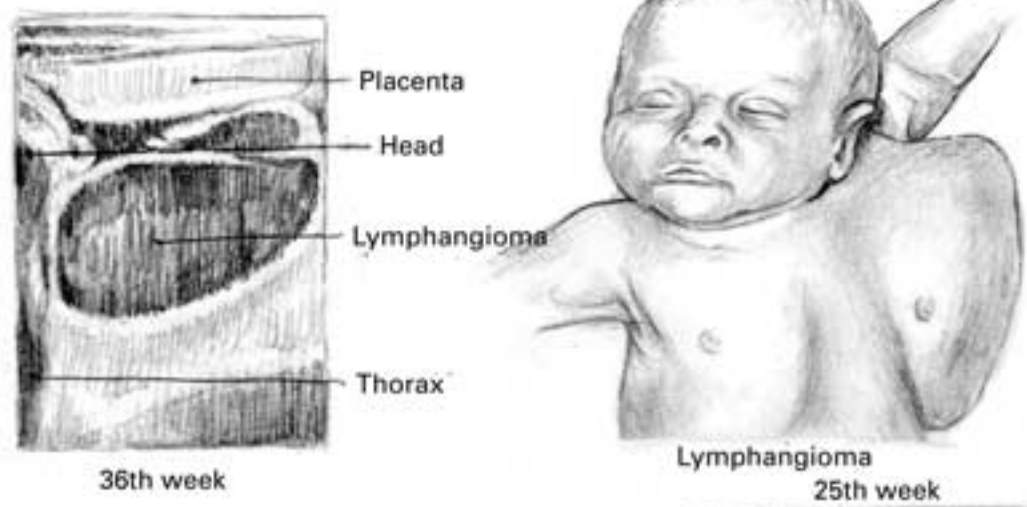
C Cystic tumour of the lungs.



D Different varieties of tumours: cystic hygroma; lymphangioma; sacrococcygeal teratoma.



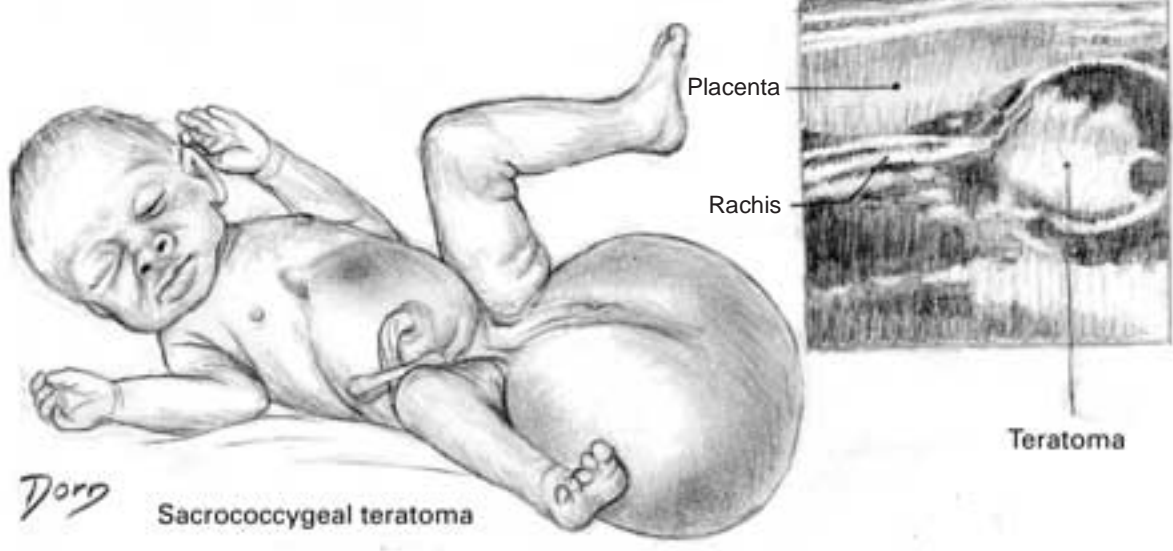
Cystic hygroma



36th week

Lymphangioma

25th week

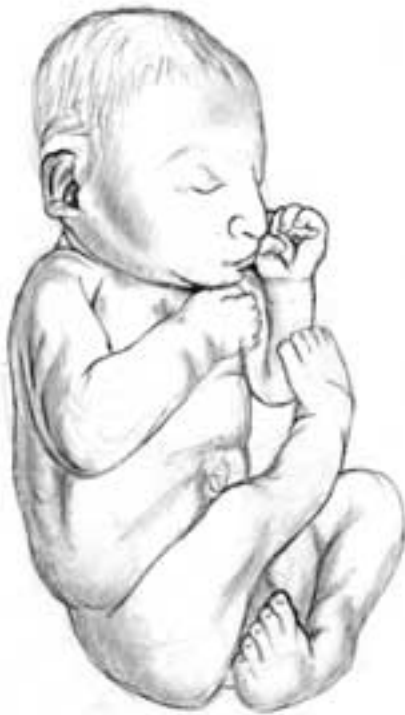

Sacrococcygeal teratoma

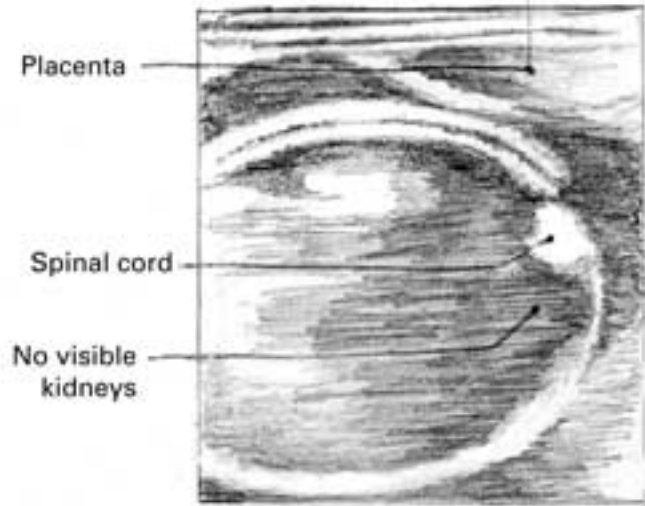
Teratoma

Miscellaneous

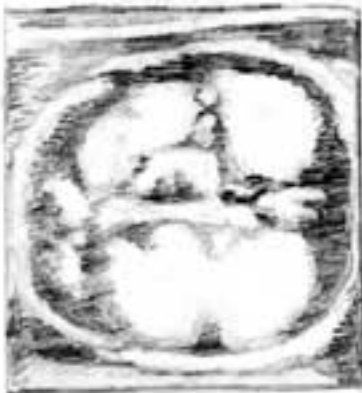E Anomalies of the urinary tract: agenesis of the kidneys; cystic tumour of the kidneys.



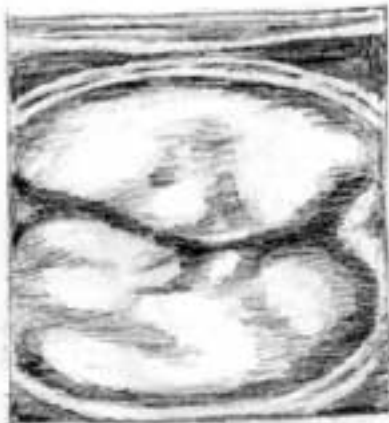Agenesis of the kidneys



Agenesis of the kidneys



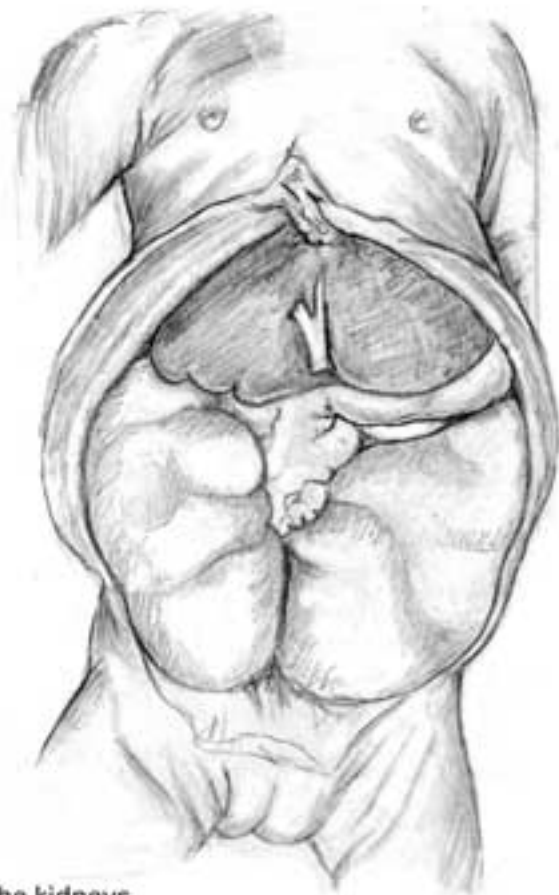32nd week



Increasing volume
35th week

Dorn

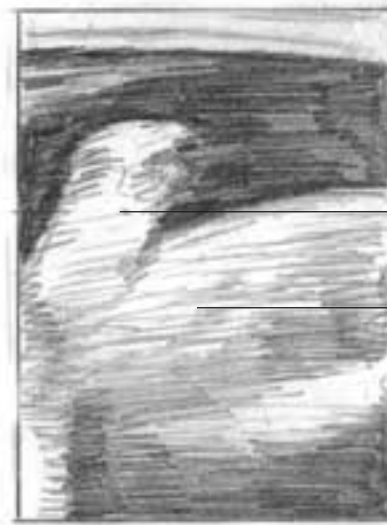Cystic tumour of the kidneys



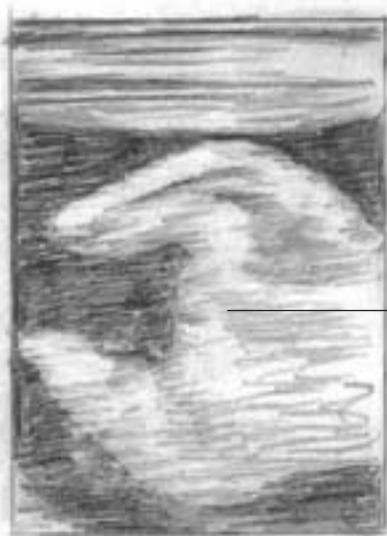F Achondrogenesis.



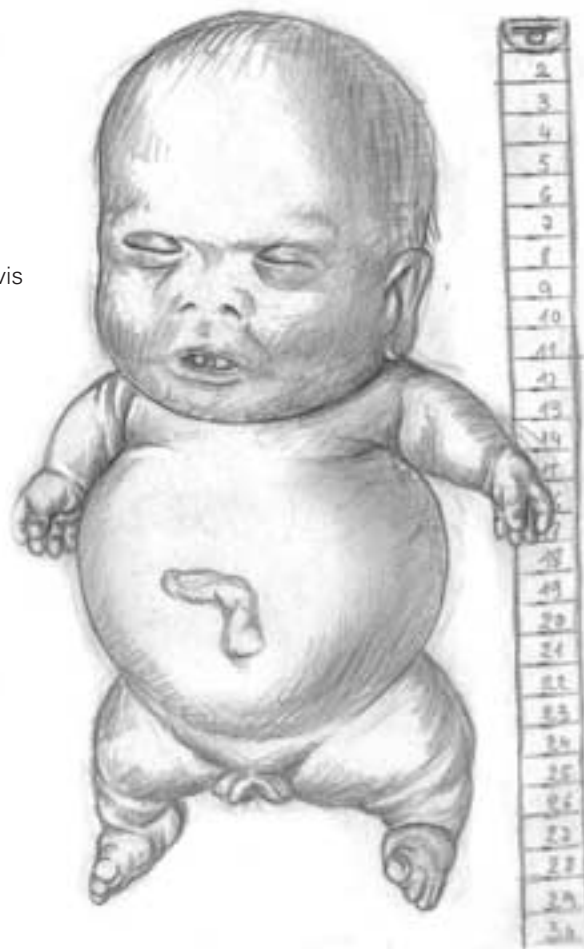35 weeks



35 weeks



35 weeks

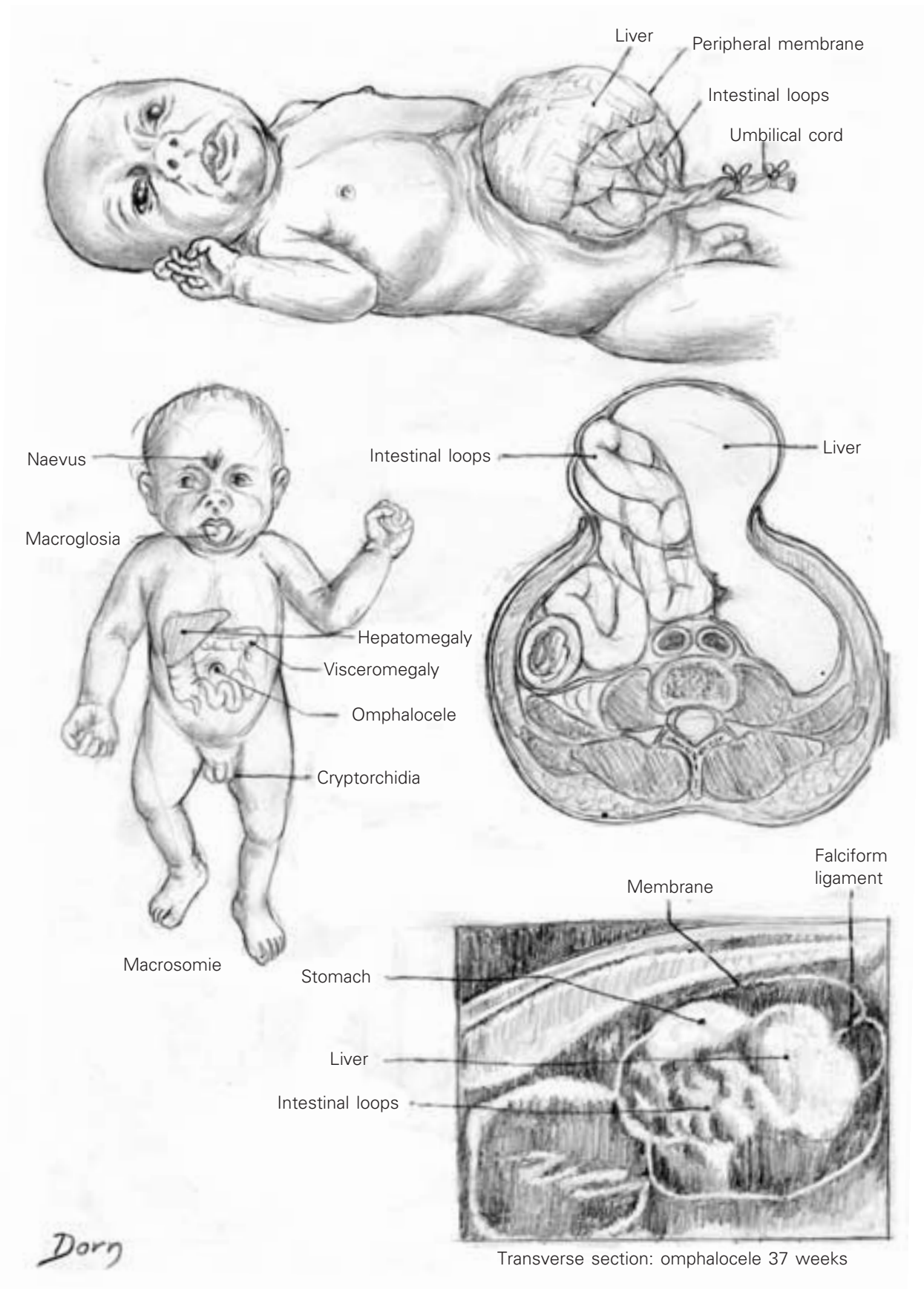


Achondrogenesis

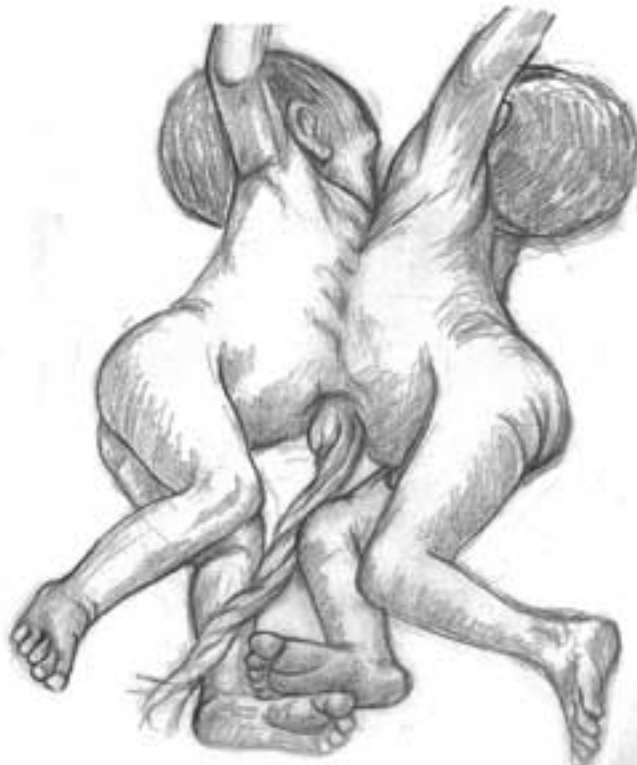Dorn

Miscellaneous

G Omphalocele.



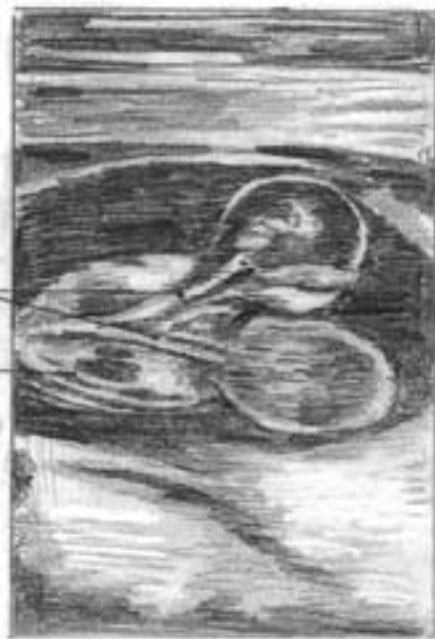H Monstrous anomalies.



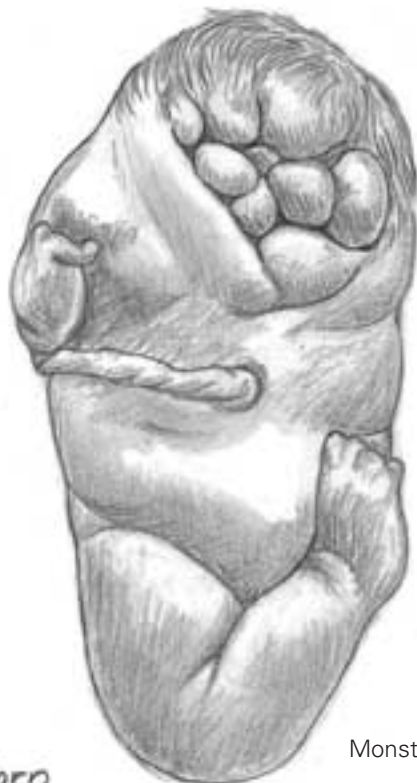Omphalothoracopage

two vertebral columns

one trunk



Two-headed foetus 14 weeks

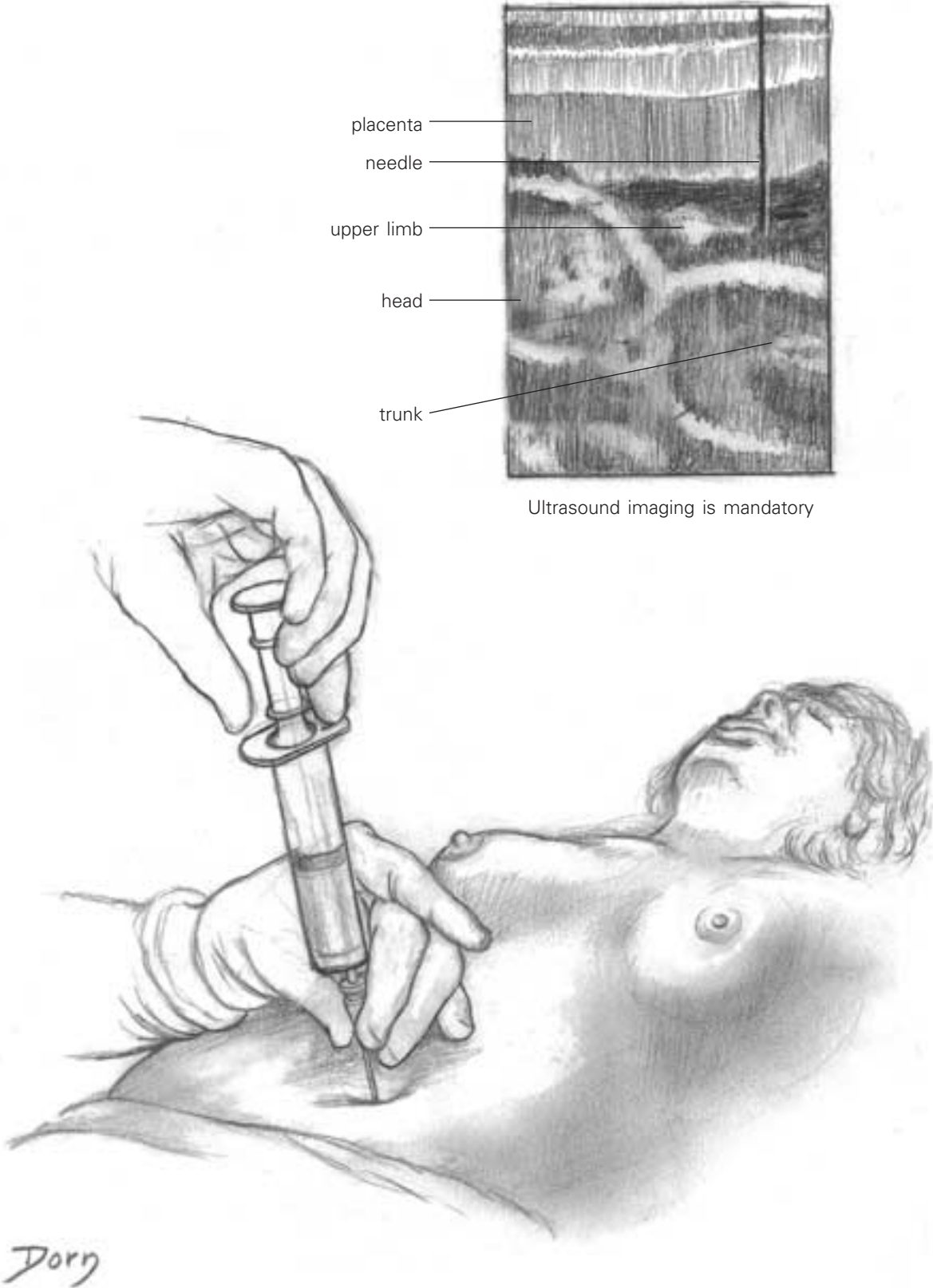


Monster

Dorr

Miscellaneous

Detection of fetal anomalies.
Amniocentesis under ultrasound
imaging

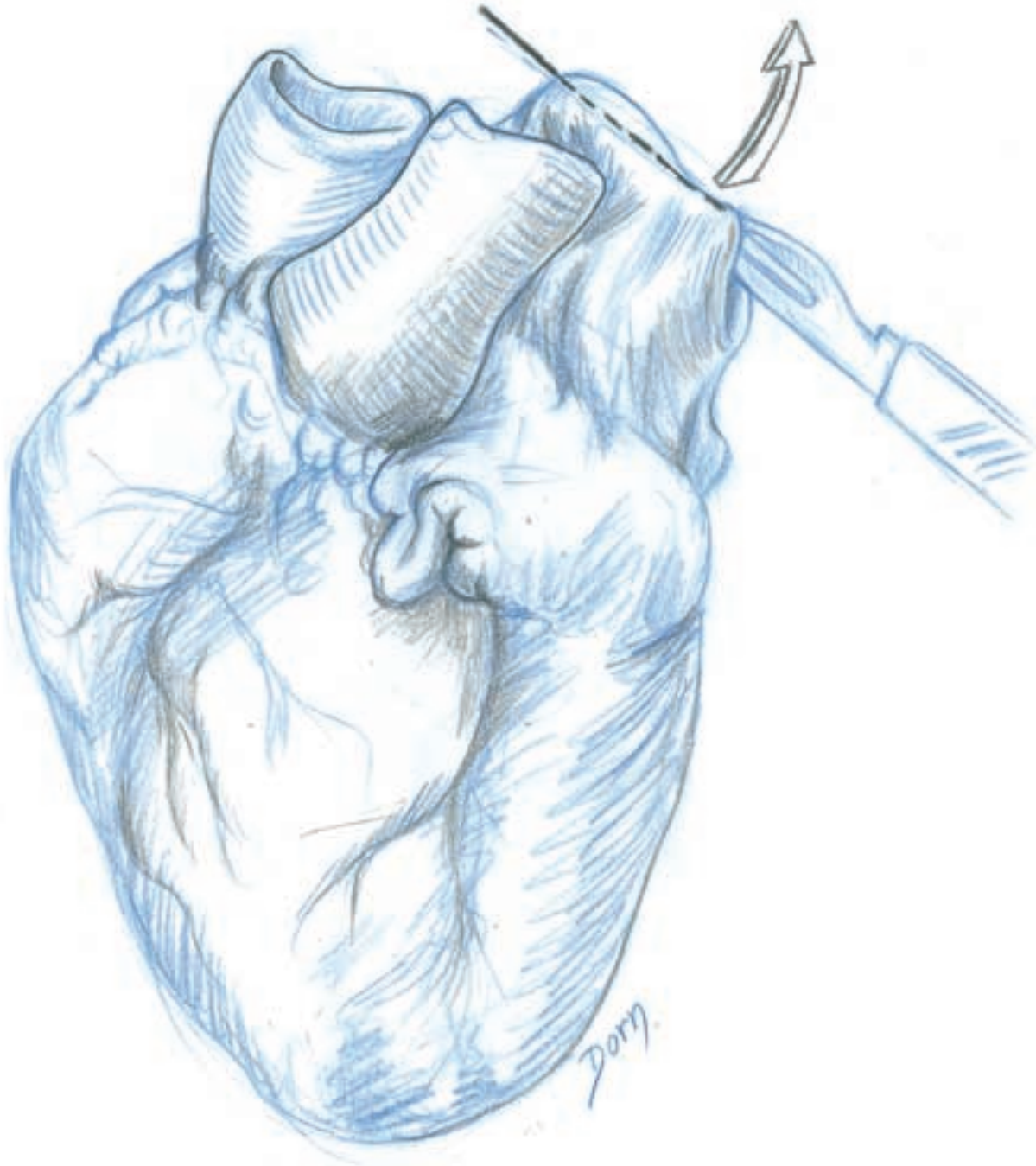


Heart anatomy

Heart anatomy cannot be understood without exposing the cavities.

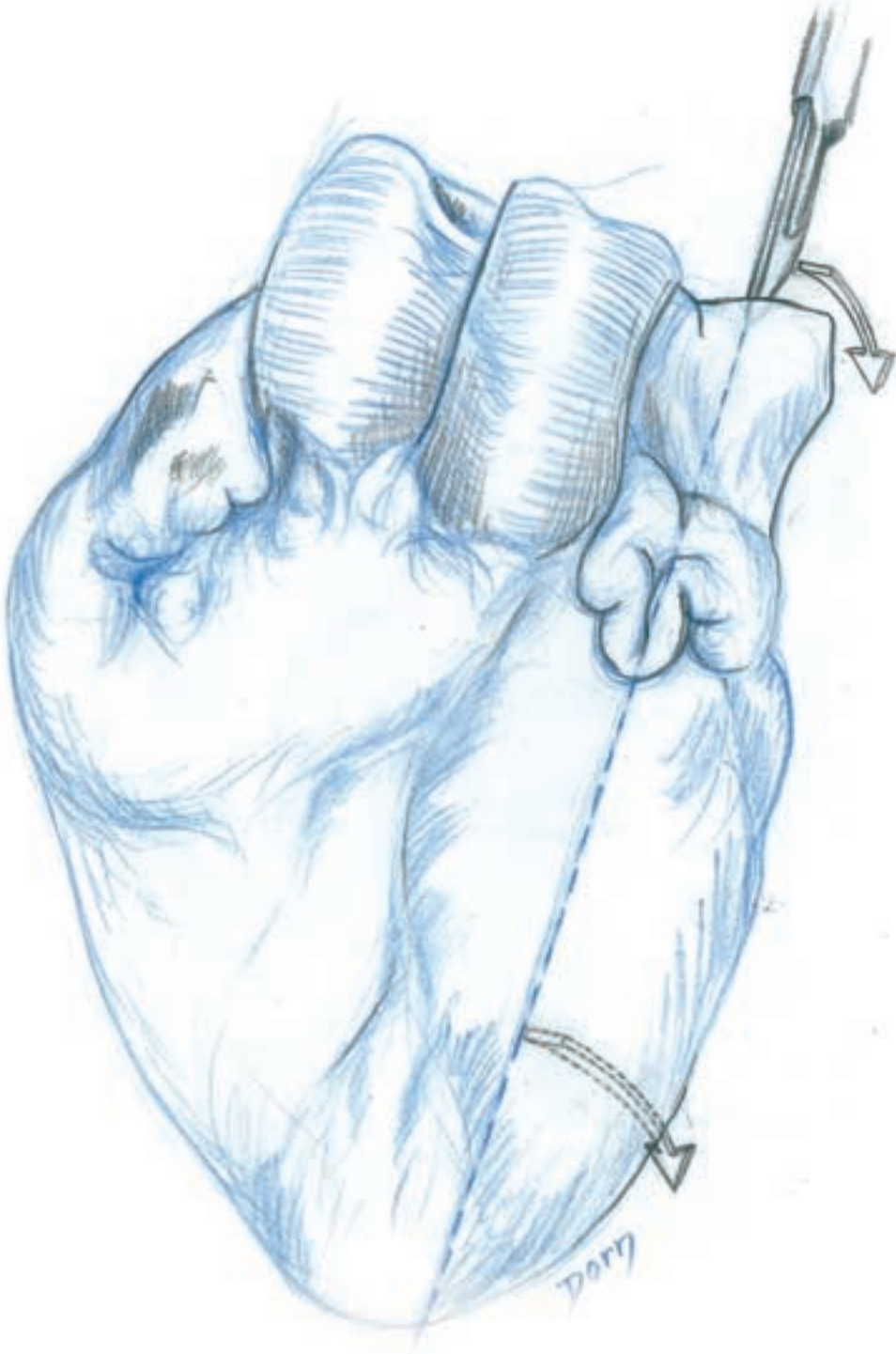
Dissection of the left heart

A Section of the left auricle between the two pulmonary veins.

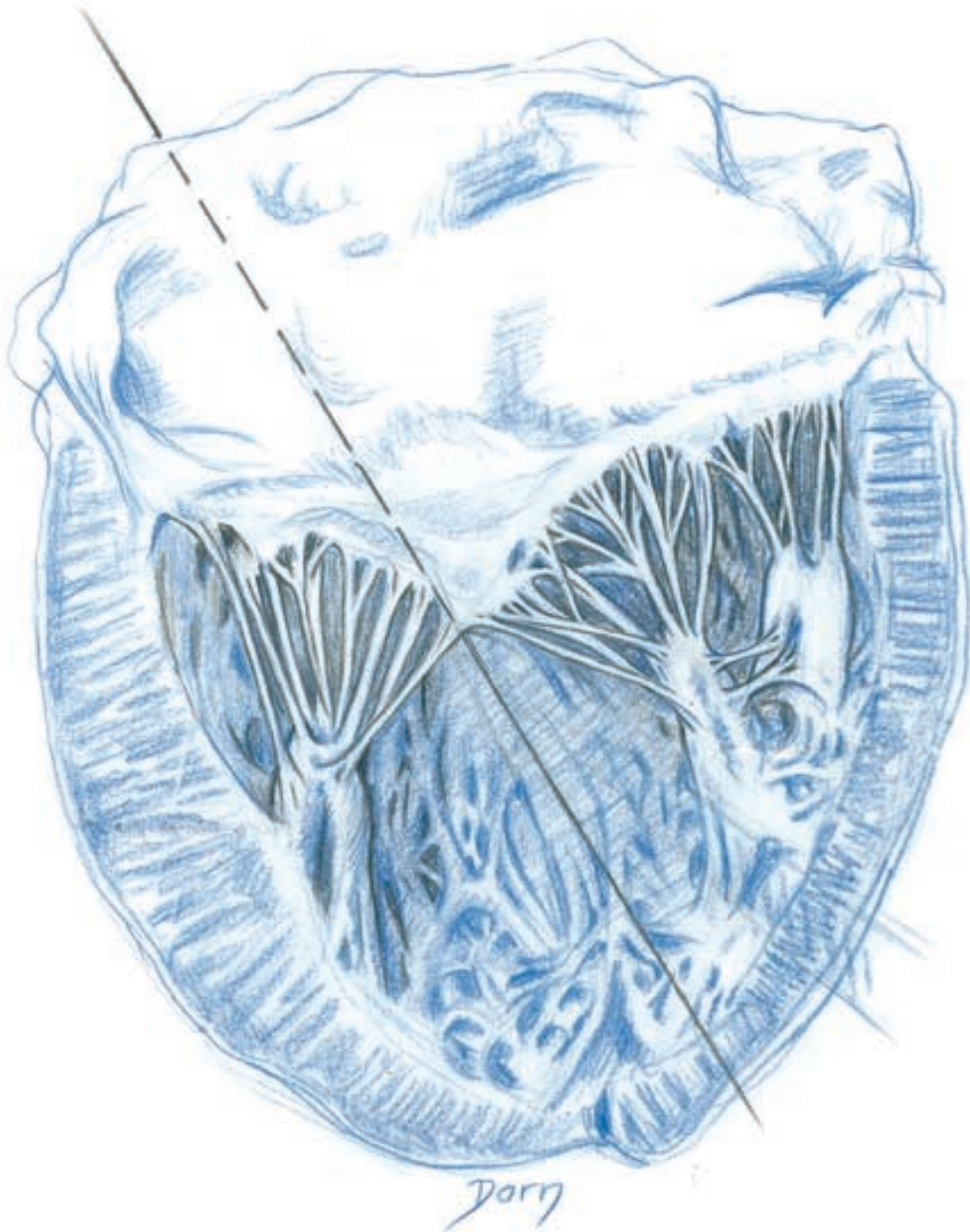


Miscellaneous

B The knife is introduced in the left auricle.

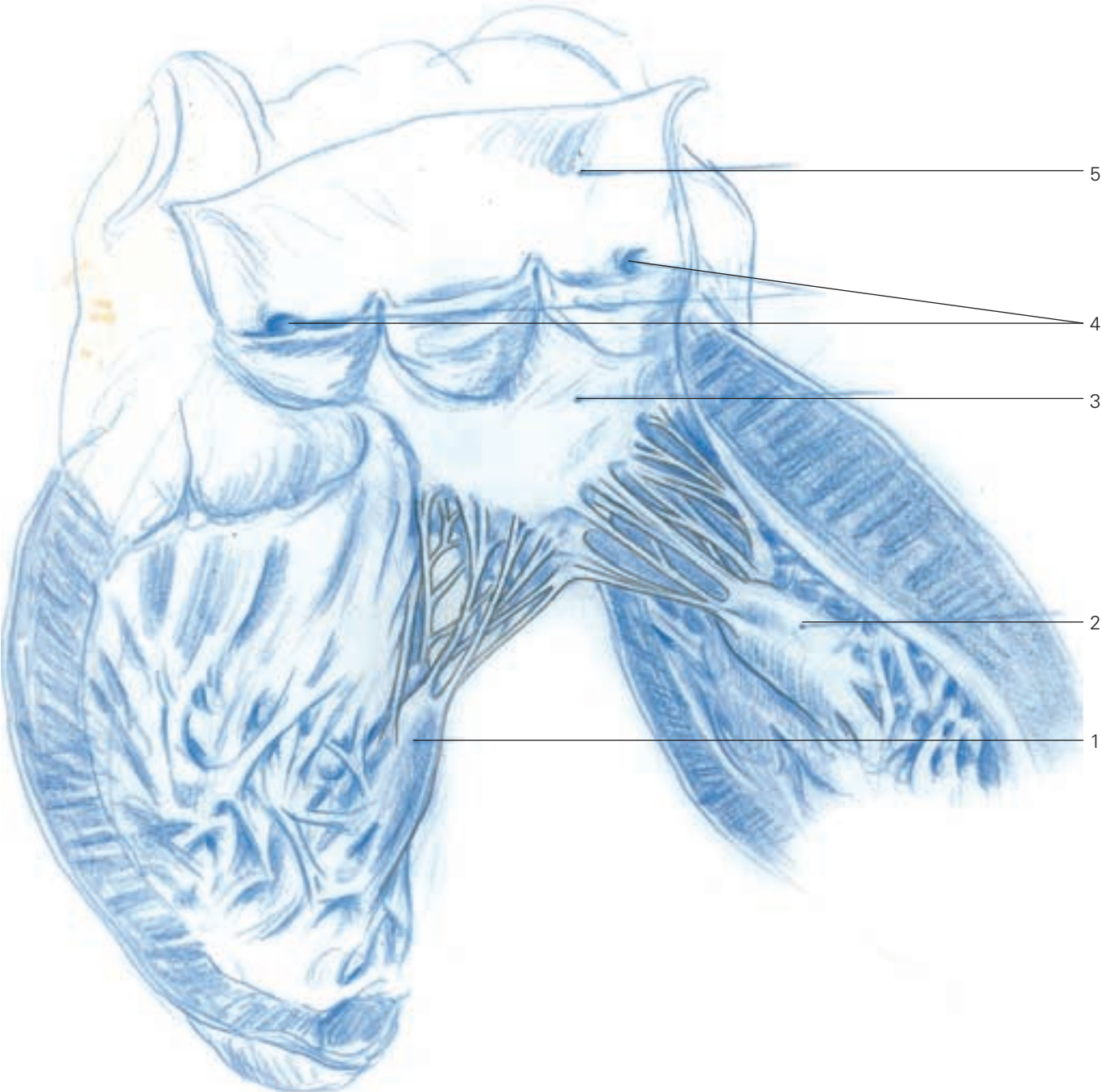


C Left ventricle. The mitral valve and the anterior and posterior papillary muscles are visible.



Miscellaneous

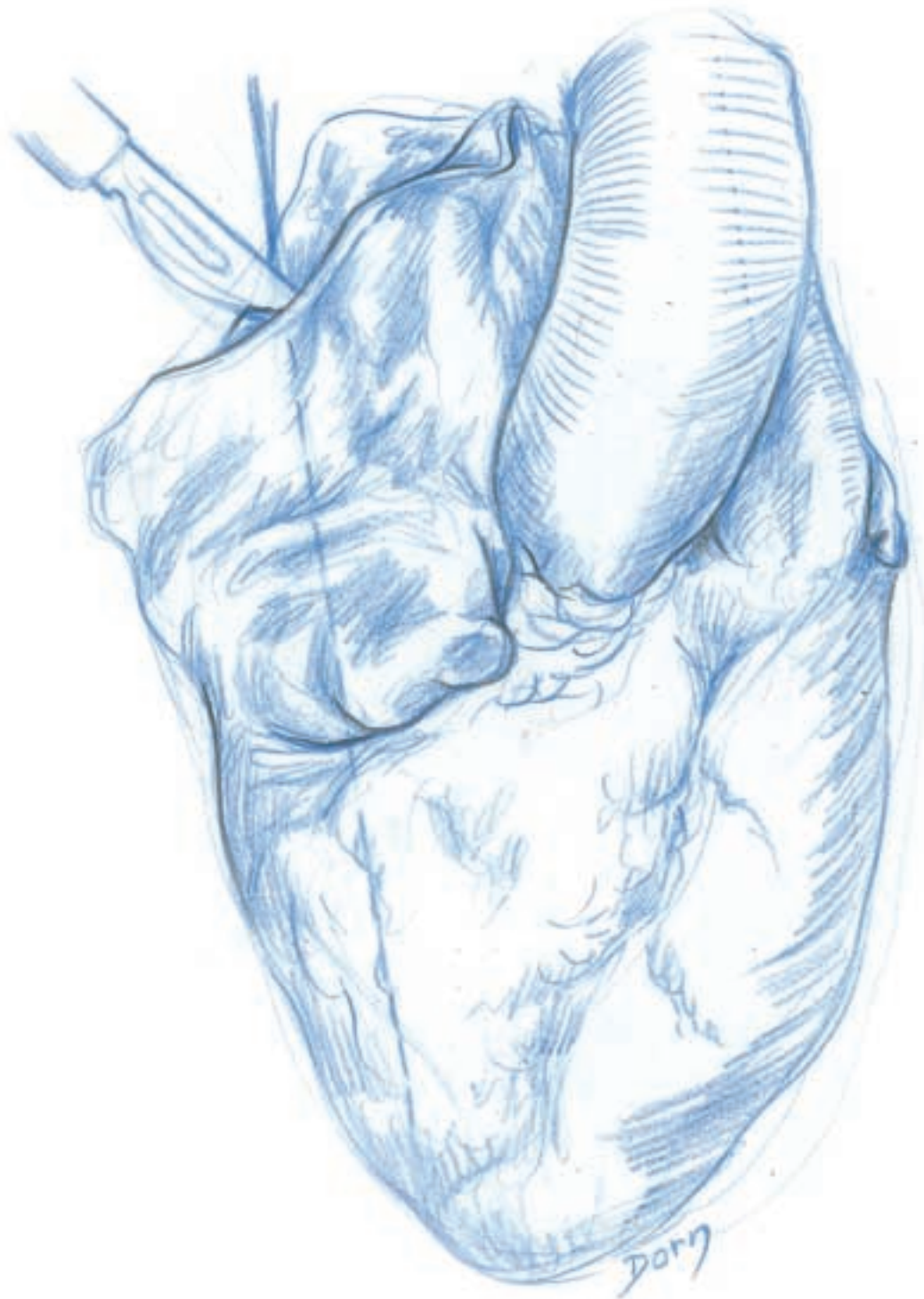
D The left ventricle is separated into two parts.



- D**
- 1 posterior papillary muscle
 - 2 anterior papillary muscle
 - 3 mitral valve
 - 4 opening of coronary arteries
 - 5 ascending aorta

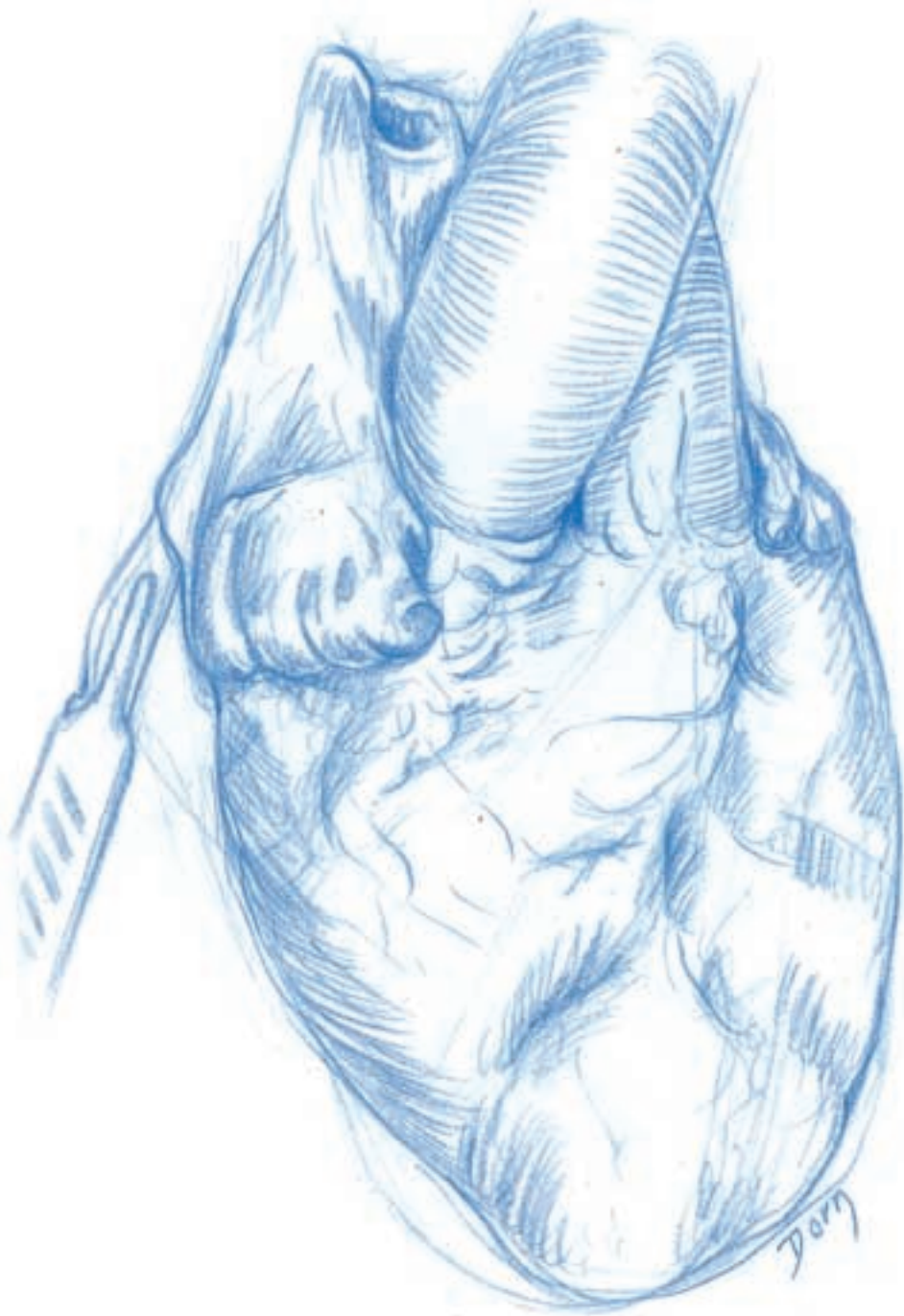
Dissection of the right heart

A Sectioning and opening of the right auricle between the two venae cavae.

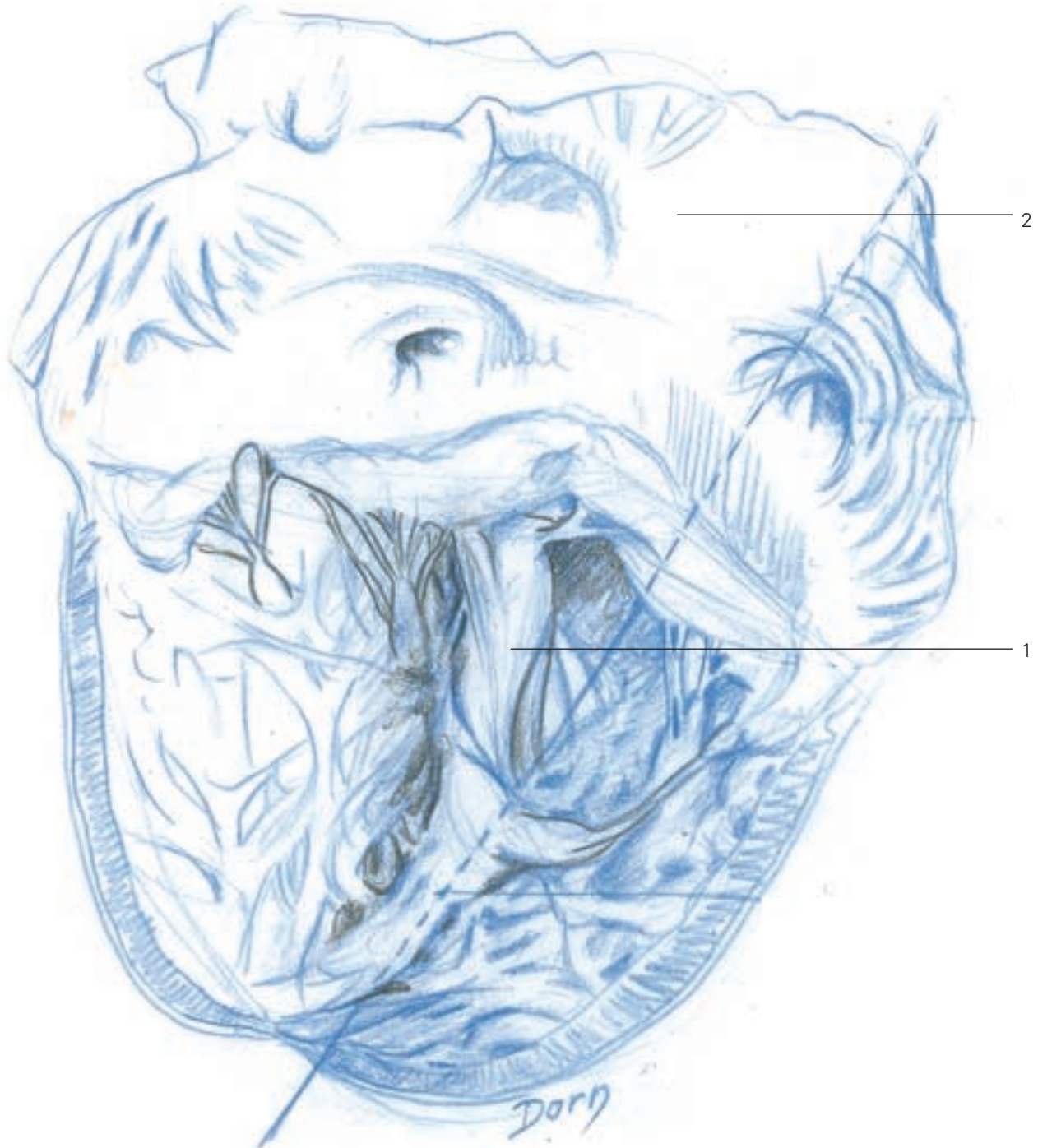


Miscellaneous

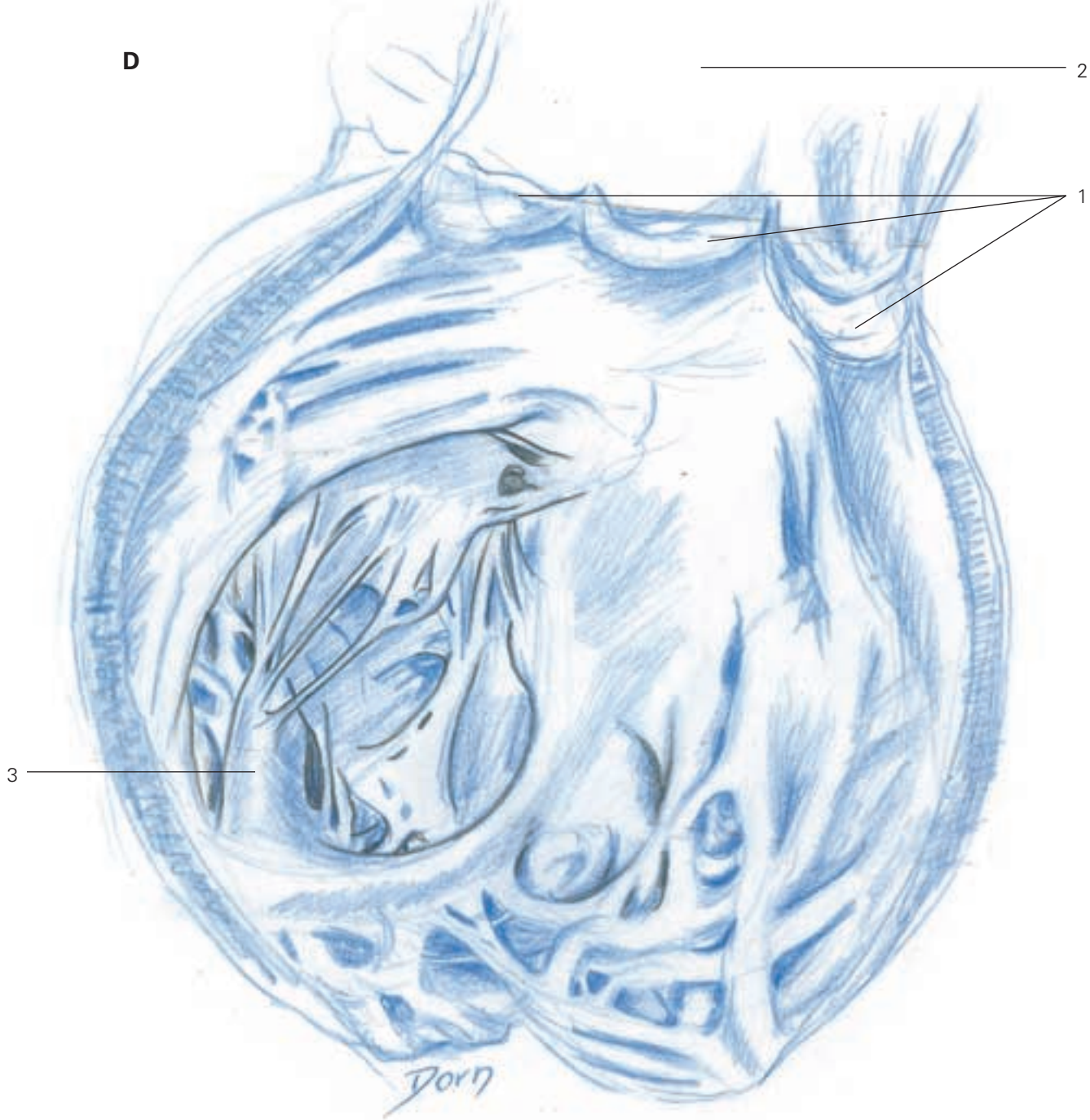
B The knife is introduced in the right auricle and the right ventricle is opened to the tip.



C, D The right ventricle is opened. The tricuspid valve and the papillary muscle are seen.



- 1 posterior papillary muscle
- 2 right atrium



D
1 tricuspid valve
2 right atrium
3 posterior papillary muscle

Index

- abdominal surgery 105-18
- abdominal wall 74
- acetabulum 189
 - cross-section through hip joint 177
 - exposures 177-90
 - extended iliofemoral approach 186
 - inguinal approach 182-6
 - posterior (Kocher-Langbeck) approach 178-81
- achondrogenesis 215
- acromion 141
- agenesis of kidneys 214
- Allen's test 24
- amniocentesis 218
- antiretrograde flow valves 107
- arm flap, lateral 2
- arteries
 - anterior interosseous 21
 - brachial 14
 - collateral 25
 - descending genicular 10
 - iliac
 - common 75
 - external 183
 - internal 75
 - interosseous
 - dorsal 39
 - posterior 18, 19
 - permeability (patency) test 24
 - peroneal
 - sural skin flap 9
 - vascularised fibula transfer 11, 12
 - radial
 - exposure of radial nerve at elbow 58
 - forearm radial flap 16, 17
 - ulnar 36, 37
- auditory canal reconstruction 208
- auricle
 - left 219-20
 - right 223-4
- back, muscle relief study of 198
- bladder
 - extrophy in young boy 81-5
 - bladder sutures 83
 - bone frame closure 84
 - muscular wall closure 85
 - skin flaps 81, 83
 - genital prolapse after hysterectomy 65
 - reconstruction 105, 106-9
 - antiretrograde flow valves 107
 - ileum isolation 106
 - ileum modification 107
 - ileum suture 106, 108
 - stabilisation 108
 - ureteric implantation 109
 - separation from vagina after genital prolapse 59-64
- blood supply *see* vascular supply
- bone
 - covering defects of 10
 - frame closure in bladder extrophy 84
 - transfer/transplantation
 - lumbar spondylolisthesis 124
 - patella allograft 175
 - scoliosis surgery 127
 - vascularised 10-13
- 'boutonnière' deformity 31-3
- brachial flap, lateral 14-15
- brachial plexus 49-53
 - anatomy 53
 - infraclavicular approach 51-2
 - supraclavicular approach 49-51
- bursae
 - in acetabulum 180, 181
 - subdeltoid 142
- calf, skin flap from 8
- canal wall down mastoidectomy 207
- canal wall up mastoidectomy 206
- cancellous bone
 - harvest/transplantation
 - lumbar spondylolisthesis 124
 - scoliosis surgery 127
- capsules
 - acetabulum 180, 181
 - ankle joint 193
 - glenohumeral joint 146
 - knee joint 173
 - trapeziometacarpal joint 28
 - vertebral 122
- carpal tunnel syndrome 36
- cervix, uterine 65
- clavicle
 - excision 137-8
 - exposure of brachial plexus 51
 - exposure of subacromial space 141
- cleidectomy 137-8
- clitoris plasty in feminisation 99, 101, 102
- compartments
 - of hand, Guyon's 36
 - of kidney in lithiasis 79
 - of leg 5
- congenital malformations 210-17
 - monstrous anomalies 217
 - of spine 210
 - tumours 212-14
- coracoid process 144
- corpora cavernosa
 - erectile function of penis, prosthesis for 90, 92, 94
 - feminisation 100, 102
 - hypospadias 87, 88
- corpora spongiosum 87, 88
- craniofacial surgery 10

- cul-de-sac of Douglas 64
 elythrocele prevention 68
 elythrocele treatment 70
 cystic hygroma 213
 cystic tumours
 of kidneys 214
 of lungs 212

 defects, covering
 of bone 10
 of hand 17, 19
 of heel 9
 of knee 4
 of lower limb 5
 deltopectoral groove 143
 diaphragmatic hernia 211
 distal ulnar flap 2
 Dorn, Léon vii, viii
 evolution of style 139
 on hands 23
 his method ix
 first stage sketch ix, x
 second stage rough drawing ix, xi
 third stage definitive drawing ix, xii
 dorsal rachis 120-1
 Douglas, cul-de-sac of 64
 elythrocele prevention 68
 elythrocele treatment 70
 Dupuytren's disease 40-3
 artery/nerve identification
 at digitopalmar junction 42
 in finger 41
 radial side lesions 40
 vertical septae, division of 43
 dura mater 201

 ear surgery 201-8
 retroauricular/transvestibular
 approach 201
 écorché of Vésale 197
 elythrocele
 prevention 68
 surgical treatment 70-2
 endolymphatic sac 202
 erectile function of penis, prosthesis
 for 86, 90-6

 Fallopian aqueduct 203
 fasciocutaneous flaps 2
 feminisation 97-104
 clitoris plasty 99, 101, 102
 final aspect 103
 labia plasty 97, 103
 vagina plasty 97

 femur
 distal metaphysis, flap from 10
 posterior approach to shaft
 154-6
 recalcitrant non-union of 10
 fetal abnormalities
 detection 218
 two-headed foetus 217
 fibula transfer 11
 finger, index, pollicisation of index
 45-8
 bone fixation/tendon suture 47
 dissection of dorsal aspect 45
 dissection of palmar structures
 46
 rotation 47
 flaps
 arm, lateral 2
 brachial, lateral 14-15
 from calf 8
 distal ulnar 2
 fasciocutaneous 2
 feminisation 97, 99
 free revascularised 2
 hypospadias 89
 interosseous, posterior 2, 18-19
 island, pedicled 2, 10
 distally based, with retrograde
 blood flow 16
 from lower limb 3-9
 mucosal, in hypospadias 86
 isolation 88
 tubularisation 89
 musculoperiosteal 143
 neurocutaneous 8-9
 osteoperiosteal 10
 preputial 86
 radial forearm 2
 scapular 2
 shoulder exposure 143
 sural 8-9
 sural skin 8-9
 tree of, for upper limb 2
 ulnar forearm 2
 upper limb, tree of flaps for 2
 forearm
 interosseous nerve exposure
 54-6
 osteosynthesis of fracture 139-40
 posterior interosseous flap
 18-19
 radial aspect anatomy 24
 radial flap 16-17
 radial flap pivot point 17
 radial flaps 2
 ulnar flaps 2

 fractures
 acetabulum
 columns
 anterior 182, 187
 posterior 187
 walls
 anterior 182
 posterior 178
 forearm, osteosynthesis of
 139-40
 intra-articular, of hand 27
 plate repair 139
 free revascularised flaps 2

 gastrectomy 110-14
 jejunum, anastomoses with
 112-14
 oesogastrectomy 110-11
 genital prolapse
 after hysterectomy 65-9
 lower approach 59-64
 glans
 erectile function of penis,
 prosthesis for 90, 94
 feminisation 102
 hypospadias 89
 Guyon's compartment 36
 gynaecological surgery 59-72

 hand
 anatomy 24-6
 covering defects of 17, 19
 surgery 27-48
 Harrington's rod 126, 128
 heart anatomy 219-26
 left heart 219-22
 right heart 223-6
 heel, covering defects of 9
 hepatectomy, left 117
 partial 118
 hernia, diaphragmatic 211
 humerus
 lateral brachial flap 14, 15
 shoulder implant stabilisation
 136
 subdeltoid approach to proximal
 metaphysis 150
 hygroma, cystic 213
 hypogastric plexus, superior 129
 hypospadias surgery 86-9
 mucosal flap 86, 88, 89
 skin flap 89
 hysterectomy 66

 ileum in bladder replacement 105,
 106-7

- iliac crest 124
iliac fossa 184
 internal 190
iliac wing, external 187
iliopsoas fascia 183
iliotibial tract 178
implantation
 patella prosthesis 165-6
 shoulder prosthesis 136
 ureteric 109
interosseous flap, posterior 2,
 18-19
intramedullar nail 140
ischium 180
island flaps, pedicled 2, 10
 distally based, with retrograde
 blood flow 16
jejunum 112-14
joints
 acromioclavicular 138
 ankle
 neurovascular bundle 191
 posteromedial approach to
 191-3
 posterior aspect 193
 calcaneocuboid 195
 DIP (distal interphalangeal) 31
 distal radioulnar 44
 elbow 57-8
 femoropatellar 164-7
 glenohumeral
 anterior approach 143-6
 capsule exposure/opening
 146
 muscle exposure 144-5
 skin incision 143
 axillary approach
 joint exposure 149
 neurovascular bundle 147-8
 skin incision 147
 hip
 cross-section of 177
 instability/dislocation 209
 humeroradial, exposure of 151
 knee
 anatomy
 anterior view 160-1
 medial aspect 159
 covering defect of 4
 posterior approach 172
 surgery 164-76
 anteromedial approach 168
 medial approach 164-7
 posterolateral approach
 168-71
 midtarsal 194-5
 PIP (proximal interphalangeal)
 25
 arthrolysis (limitation of
 extension) 34-5
 'boutonnière' deformity 31, 33
 sternoclavicular
 cleidectomy 138
 dislocation 134-5
 exposure 134
 subtalar
 exposure 195
 lateral approach 194-5
 talonavicular 195
 trapeziometacarpal 28
 wrist
 distal radioulnar joint approach
 44
 posterior interosseous flap
 pivot point 19
 radial aspect anatomy 24
 ankle
 kidneys 73
 agenesis 214
 allotransplantation 74-8
 skin incision 74
 transplant presentation 76
 vessel sutures 77, 78
 cystic tumour 214
 renal lithiasis
 exposure 79-80
 removal 80
 Kocher-Langbeck (posterior)
 approach 178-81
 labia plasty in feminisation 97, 99,
 103
 laparoschisis 211
 ligaments
 coracoclavicular 138
 costoclavicular
 cleidectomy 138
 repair/stabilisation 135
 rupture 134
 cruciate
 anterior
 anteromedial approach 168
 posterolateral approach
 168-71
 posterior 172-3
 deltoid 192
 inguinal 190
 ligamentum flavum 122
 longitudinal, anterior 130
 longitudinal, posterior 131
 patellar, allograft of 174-6
 radioulnar, posterior 44
 ureterosacral
 elythrocele treatment 72
 genital prolapse
 after hysterectomy 65, 67
 lower approach 64
 lithiasis, renal
 exposure 79-80
 removal 80
 liver
 hepatectomy, left 117
 partial 118
 lobes 106
 distribution of cuts 115
 distribution of vessels 115,
 116
 segmental resections 105
 transplantation 105
 lower limb
 anatomy 154-63
 covering defects of 5
 flaps from 3-9
 muscle relief study 200
 surgery 153-93
 lumbar disc hernia, anterior
 approach to 129-31
 disc excision 131
 disc exposure 130
 lumbar spondylolisthesis 122-5
 lumbosacral plexus anatomy
 162-3
 lungs 121
 cystic tumour 212
 lymphangioma 213
 macrosomia 216
 macroglossia 216
 mastoid canal 208
 mastoidectomy
 canal wall down procedure 207
 canal wall up procedure 206
 Ménière's disease 202
 meningocele 210
 mesentery in bladder replacement
 106
 metacarpals 28, 29
 middle ear surgery
 Shambaugh approach 205
 transmeatal/extended transmeatal
 approach 204
 mitral valve 221
 monstrous anomalies 217
 mucosal flap in hypospadias 86
 isolation 88
 tubularisation 89

- muscles
 biceps
 approach to proximal third of radius 151
 exposure of radial nerve at elbow 57
 posterior approach to femoral shaft 155
 biceps femoris 155
 brachialis 57
 brachioradialis
 approach to proximal third of radius 151
 exposure of radial nerve at elbow 57, 58
 coracobiceps 144, 145
 deltoid
 glenohumeral joint approach to shoulder 144
 subacromial space approach to shoulder 141
 subdeltoid approach to proximal metaphysis of humerus 150
 extensor carpi ulnaris 54
 extensor digitorum brevis 195
 extensor digitorum communis 54
 extensor retinaculum, inferior 194
 flexor hallucis longus 11
 flexor retinaculum 191
 gastrocnemius
 approach to popliteal vessels 157
 flap from lateral head 3-4
 medial head 172, 173
 soleus flap operation 5
 gemelli 180
 gluteal 187
 gluteus maximus 178
 gluteus medius 188
 gluteus minimus 188
 iliacus 190
 iliopsoas 184, 185
 ischiocavernosus 82
 latissimus dorsi
 flap vascular supply 2
 transpleural approach to dorsal rachis 120
 obturator internus 180
 omohyoideus 49
 papillary 221, 225
 pectoralis major 144
 pectoralis minor 51
 pes anserinus 157
 pisiformis 189
 pronator quadratus
 exposure 20
 flap operation 20-1
 pronator teres 57
 psoas 183
 relief studies 197-200
 rotators of hip, external 179, 180, 188, 189
 sartorius 190
 scalenus anterior 49
 semimembranosus 157
 serratus anterior 2
 soleus
 approach to popliteal vessels 157
 flap operation 5-7
 subscapularis 146
 supinator
 approach to proximal third of radius 151
 exposure of radial nerve at elbow 57
 interosseous nerve exposure 55, 56
 temporal 208
 tensor fascia latae 188
 of thenar eminence 28
 tibialis posterior 11, 12
 trapezium
 removal 29
 volar approach 27-30
 vastus lateralis 155
 musculoperiosteal flaps 143
 myelomeningocele 210
 nerves
 axillary 148
 cutaneous, lateral, of thigh 183
 digital, common 46
 facial
 mastoidectomy 207
 retroauricular/transvestibular approach 201
 transmastoid approach 203
 femoral 183
 interosseous 54-6
 of knee, medial aspect of 159
 lumbosacral plexus anatomy 162-3
 median 36-7
 in penis, origins of 101
 peripheral, surgery of 49-58
 peroneal, common 4
 posterior femoral cutaneous 154
 radial
 anterior 57-8
 approach to proximal third of radius 151
 exposure at elbow 57-8
 posterior
 exposure at elbow 57-8
 interosseous nerve exposure 55
 posterior interosseous flap 19
 sciatic
 extended iliofemoral approach to acetabulum 189
 posterior (Kocher-Langbeck) approach to acetabulum 179
 traumatic lesions 49
 vestibular 201
 neurocutaneous flaps 8-9
 neurosurgery/ear surgery boundary 201
 oesogastrectomy 110-11
 oesophagus
 excision in oesogastrectomy 110
 stomach, anastomosis with 111
 transpleural approach to dorsal rachis 121
 omphalocele 216
 omphalothoracopage 217
 osteoperiosteal flap from femur 10
 osteosynthesis of forearm fracture 139-40
 paediatrics 209-17
 patella 175
 allograft of 174-6
 prosthesis of 164-7
 patellar preparation 166-7
 trochlear implant 165-6
 patellar retinaculi, lateral 175
 Pavlick's harness 209
 pedicles
 adipofascial 8
 neurovascular 101
 vascular 1, 2
 pelvic brim 185
 penis
 amputation for sexual ambiguity 97-104
 corpora cavernosa
 excision 102
 release of 100
 final aspect 103
 neurovascular pedicles 101
 release of penis 99
 shortening 102
 urogenital sinus incision 98

- bladder extrophy 82
 curvature in hypospadias 87
 nerves, origins of 101
 prosthesis for erectile function 90-6
 perineum
 electrocele treatment 72
 genital prolapse after hysterectomy 69
 periosteum 11
 peripheral nerve surgery 49-58
 peritoneum
 kidney allotransplantation 75
 lumbar disc hernia treatment 129
 plate repair of fracture 139
 pleura 120
 pollicisation of index finger 45-8
 bone fixation/tendon suture 48
 dissection of dorsal aspect 45
 dissection of palmar structures 46
 rotation 47
 popliteal fossa 172
 popliteal neurovascular bundle 158
 popliteal vessels, extended medial approach to 157-9
 preputial flap 86
 prosthesis
 for erectile function of penis
 components 90
 flaccid/erect state 91
 placement 91, 96
 surgical procedure 92-6
 of patella 164-7
 shoulder implant stabilisation 136
 pubic ramus, superior 186

 radial forearm flap 2
 radius
 anterior approach to proximal third 151
 osteosynthesis of 139
 reconstructive surgery 1-21
 development of 1
 rectum 70, 71
 renal lithiasis
 exposure 79-80
 removal 80
 renal pelvis 79, 80
 retractile band 87
 Retzius' space 91, 95
 ribs 120

 sacrococcygeal teratoma 213
 scaphoid bone 39

 scapular flaps 2
 scoliosis surgery 126-8
 scrotum 91, 95
 sexual ambiguity
 amputation of penis 97-104
 diagrammatic representation 97
 Shambaugh approach to middle ear 205
 shoulder
 bony landmarks 141
 prosthetic implant stabilisation 136
 surgical exposure 141-9
 glenohumeral joint anterior approach 143-6
 glenohumeral joint axillary approach 147-9
 subacromial space anterior approach 141-3
 skin flaps
 from calf 8
 in feminisation 97, 99
 in hypospadias 89
 sural 8-9
 spermatic cord 183, 186
 spina bifida 210
 spinal cord 123
 spinal surgery *see* vertebral column surgery
 stomach
 excision in oesogastrectomy 110, 112
 oesophagus, anastomosis with 111
 subacromial space, anterior approach to 141-3
 musculoperiosteal flaps 143
 subdeltoid bursa 142
 sural skin flap 8-9

 temporal aponeurosis graft 207, 208
 temporal fascia graft 204, 208
 tendons
 Achilles'
 posteromedial approach to ankle 193
 soleus flap operation 6
 biceps
 approach to proximal third of radius 151
 shoulder implant stabilisation 136
 extensor 44
 extensor digiti minimi 44
 extensor, of hand
 central band release/resection 32
 central/lateral bands, suture of 33
 lateral band release 31
 flexor carpi radialis 29
 flexor carpi ulnaris 38
 flexor digitorum superficialis 26
 blood supply 34, 35
 transfer to thumb 38
 vincula 34
 flexor, of fingers 25
 flexor profundus 26
 to gastrocnemius medial head 172
 lateral collateral 171
 of popliteal muscle 171
 semitendinosus 155
 subscapularis 149
 of tibialis posterior 192
 teratoma, sacrococcygeal 213
 thoracotomy 120-1
 transplantation
 bone
 lumbar spondylolisthesis 124
 patella allograft 175
 scoliosis surgery 127
 vascularised 10-13
 kidneys 74-8
 skin incision 74
 transplant presentation 76
 vessel sutures 77, 78
 liver 105
 patella/patellar ligament allograft 174-6
 temporal fascia graft 204
 tympanic graft 206-8
 trapeziectomy 27, 29
 tree of flaps for upper limb 2
 tricuspid valve 225
 Tubiana, Raoul 23, 40
 tunnel syndromes 49
 carpal 36
 tympanic cavity exploration 207
 tympanic graft 206-8
 tympanoplasty 207

 ulna, osteosynthesis of 140
 ulnar forearm flap 2
 ultrasound-guided amniocentesis 218
 upper limb
 flaps 2, 14-21
 muscle relief study 199
 nerve surgery 49
 surgery 133-51
 see also hand, surgery

Index

- ureters
 - bladder replacement 109
 - genital prolapse after hysterectomy 65
 - renal lithiasis 79
 - sparing in elythrocele treatment 70
 - urethra
 - bladder extrophy 83
 - hypospadias 86, 87, 88
 - urethral canal reconstruction 86
 - urethral meatus, external 86, 88
 - urinary bladder *see* bladder
 - urinary tract anomalies, congenital 214
 - urogenital sinus 97, 98, 99
 - urological surgery 73-104
 - uterus 70, 71
 - cervix 65

 - vascularised fibula transfer 11
 - vascularised osteoperiosteal flap from femur 10
 - vagina
 - elythrocele treatment 70

 - genital prolapse after hysterectomy 67
 - plasty in feminisation 97
 - separation from bladder after genital prolapse 59-64
 - posterior aspect 63
 - valves, antiretrograde flow 107
 - vascular supply
 - flexor profundus 26
 - flexor tendons of fingers 25
 - knee, medial aspect of 159
 - liver lobes 115
 - upper limb flaps 2
 - vascularised bone transfers 10-13, 38
 - from distal metaphysis of femur 10
 - from metaphysis of second metacarpal 39
 - veins
 - anastomosis in kidney allotransplantation 77, 78
 - azygos 121
 - iliac, external 76, 183
 - iliac, internal 75

 - peroneal 11, 12
 - pulmonary 219
 - ulnar 37
- vena cavae 223
- ventricle
 - left 221-2
 - right 225-6
- vertebrae
 - fusion
 - lumbar spondylolisthesis 122, 124, 125
 - scoliosis surgery 127
 - resection
 - lumbar spondylolisthesis 122
 - scoliosis surgery 127
 - resection of posterior segment 123
 - sacral promontory exposure 129
- vertebral bodies, distraction of 131
- vertebral column surgery 119-31
- vertebral disc hernia, anterior
 - approach to 129-31
 - disc excision 131
 - disc exposure 130

An Atlas of Surgical Anatomy

Alain C Masquelet, MD

Consultant Orthopaedic Surgeon, Hôpital Avicenne, Bobigny

The author of a number of acclaimed and best-selling surgical atlases has here collaborated again with their distinguished award-winning artist to produce another invaluable resource to guide all surgeons, whether in training or in practice. Hand surgery and microsurgery form the core of the book, but all other parts of the body are also represented. The artwork is available to download from an integral CD-ROM, which will be a much-sought aid to embellish lectures and presentations. The accompanying text contains a commentary on points of surgical and clinical interest arising.

Alain C Masquelet's previous publications with Léon Dorn include *An Atlas of Surgical Exposures of the Upper Extremity* (1990), *An Atlas of Surgical Exposures of the Lower Extremity* (1993), *An Atlas of Flaps in Limb Reconstruction* (1995, winner of the Royal Society of Medicine Atlas award), *An Atlas of Surgical Techniques of the Hand and Wrist* (1999), *An Atlas of Surgical Exposures of the Upper and Lower Extremities* (2000), and *An Atlas of Flaps of the Musculoskeletal System* (2001); some of the preliminary drawings for these atlases are now published here, as well as some of the finished illustrations. Léon Dorn's preliminary artwork for a number of other landmark publications from his long career is also included.

Contents

Reconstructive surgery • Hand and peripheral nerve surgery • Gynaecological surgery • Urological surgery • Abdominal surgery • Surgery of the vertebral column • Upper limb surgery • Lower limb surgery • Miscellaneous

With 300 illustrations by Léon Dorn



Taylor & Francis
Taylor & Francis Group

www.tandf.co.uk/medicine

ISBN 1-84184-405-5



9 781841 844053